

Case Report of Nasal Rhinosporidiosis in South Africa

Huzaifah Mayet, Denasha L. Reddy, Tika Bello Alvarez, Yahya Atiya, Nelesh P. Govender, Monica Birkhead, Tsidiso Maphanga, Sugeshnee Pather

We describe a classic case of nasal rhinosporidiosis in a woman who resided in Johannesburg, South Africa, but originated from a rural area in Eastern Cape Province. We confirmed histologic diagnosis using PCR testing and compared details with those from records on 17 other cases from South Africa.

A 24-year-old Black woman from South Africa sought care at a local primary-level clinic in Soweto, Johannesburg, South Africa, reporting a painless nasal mass of 3 years duration that caused occasional difficulty in breathing. The patient resided in Soweto but was originally from Mqunduli (31°49'S, 28°45'E), a riverside village south of Mthatha, Eastern Cape Province, South Africa. The patient reported the mass had originated in her right nostril; she disclaimed any preceding trauma and described recent onset of pain and intermittent episodes of mild, self-limiting bleeding on contact (e.g., an accidental bump) at the site of the mass. She had no rhinorrhea, and her vision was normal.

The woman was treated for sinusitis for 1 month but 2 months after initially seeking treatment was referred to the otorhinolaryngology clinic at a tertiary academic facility, where we examined her. We report details of her condition, diagnosis, treatment, and outcomes. We obtained written informed consent from the patient for publication of an account of her case including use of clinical photographs and ethics clearance from the University of the Witwatersrand Human Research Ethics Committee (M210752).

The Study

We diagnosed the patient with HIV (viral load 6,060 copies/mL, CD4+ T-cell count 570 cells/mm³) and

initiated antiretroviral therapy. She had no other underlying conditions or notable medical history and reported no international travel or contact with animals. She denied swimming in any water sources or using river or freestanding water for day-to-day purposes; she also denied interacting with any contacts, either in Soweto or Mthatha, with similar complaints or tuberculosis.

On examination, we found a nontender, 5 mm, mobile, polypoid mass in the right nostril that appeared to adhere to the anterior, superior aspect of the nasal septum near the mucocutaneous junction. Results from the remainder of her ear, nose, and throat examination, as well as examinations of her eyes and pharynx, were unremarkable. We found no cervical lymphadenopathy.

We initiated treatment with oral amoxicillin/clavulanic acid and requested a computed tomography scan of the head and neck to assess the vascularity and amenability for biopsy of the mass. The scan showed a nonenhancing, soft tissue mass in the right nasal vestibule arising from the anterior septum (Appendix Figure 1, <https://wwwnc.cdc.gov/EID/article/30/4/24-0018-App1.pdf>). A sample of the friable mass from the biopsy sent for histologic examination revealed multiple, variously sized, spherical subepidermal structures, the largest with thickened walls. Contents varied from a single, central acidophilic structure to numerous basophilic spheres that developed centripetally (Figure 1).

Because of postbiopsy recurrence of the mass and recent onset of pain and epistaxis, we scheduled the patient for definitive surgery to obtain a full-thickness sample. During the operation, we found a 15 mm polypoid mass in the anterior nasal cavity (Figure 2,

Author affiliations: University of the Witwatersrand, Johannesburg, South Africa (H. Mayet, D.L. Reddy, T. Bello Alvarez, Y. Atiya, N.P. Govender, S. Pather); Chris Hani Baragwanath Academic Hospital, Johannesburg (H. Mayet, D.L. Reddy, T. Bello Alvarez, Y. Atiya, S. Pather); St George's University of London, London, UK (N.P. Govender); University of Cape Town, Cape Town,

South Africa (N.P. Govender); University of Exeter, Exeter, UK (N.P. Govender); National Institute for Communicable Diseases, Johannesburg (N.P. Govender, M. Birkhead, T. Maphanga); National Health Laboratory Service, Johannesburg (S. Pather)

DOI: <https://doi.org/10.3201/eid3004.240018>

panels A, B) attached by a stalk to the anterosuperior aspect of the septum (Figure 2, panel C). The stalk did not extend past the mucosa of the nasal septum, so the perichondrium was not macroscopically involved. We fixed the polyp for further microscopic examination (Figure 2, panels D, E; Appendix Figure 2). Examination of the rest of the patient's nasal cavities were unremarkable. Her postoperative course was uneventful, but she was not available for further follow-up.

We performed a panfungal PCR test on a section of formalin-fixed paraffin-embedded polyp from the nasal lesion. In the PCR, we amplified fungal DNA for internally transcribed spacer genes (Appendix) and confirmed 98.8% identification and 83% coverage with *Rhinosporidium* spp. (GenBank NCBI accession no. PP060009). Phylogenetically, sequences clustered with *Rhinosporidium* sp. (ex *Canis familiaris*) obtained from a dog (Appendix Figure 3).

Rhinosporidiosis is an indolent, generally benign, polypoidal infection occurring in humans and other mammals, amphibians, and aquatic birds (1,2). Host distribution reflects freshwater habitats, the environment most commonly associated with disease acquisition. Rural riverine and agricultural communities have reported the highest incidence (3). Other risk factors associated with human infection include contact with stagnant and silted water (typically through swimming or bathing), dust and soil, and contaminated hands or clothes; low socioeconomic status is also considered a risk factor (3). Highest incidence is reported in male persons <40 years of age, presumably because of increased exposure as a result of the nature and extent of their outdoor activities (4,5). The eukaryotic pathogen typically infects exposed nasal, ocular, or genitourinary tract mucosal membranes, with rare reports of cutaneous or disseminated spread in both immunocompetent and immunocompromised patients (1,4,6,7). The etiologic agent is *R. seeberi* (class: Mesomycetozoa). Mesomycetozoa comprises a unique group of microbes phylogenetically positioned between fungi and animals, presenting the taxonomic conundrum of a parasite that is neither sporozoan nor fungal, but appears to have features of both types of organism (8,9).

Rhinosporidium grows slowly in host tissues, so infection and clinical manifestations may be temporally distant. Patients with nasal or nasopharyngeal lesions manifest intermittent epistaxis, nasal obstruction, nasal mass, or nasal discharge (3,4). Clinical differential diagnoses include neoplasms, nasopharyngeal carcinomas, inverted papillomas, primary sinonasal tuberculosis, and nasal angiofibromas (5). Diagnosis of rhinosporidiosis is made histologically; sections show

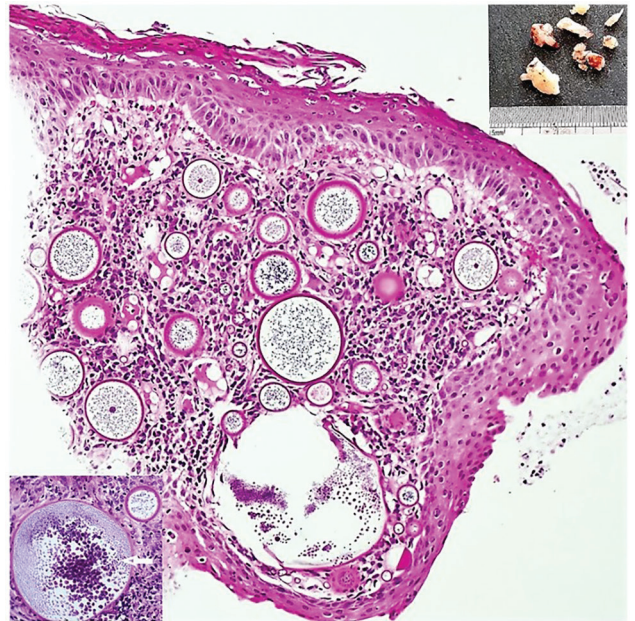


Figure 1. Results of testing in a 24-year-old Black woman with rhinosporidiosis, South Africa. Squamous mucosa with numerous thick-walled sporangia in the subepithelial region amid subacute inflammation. Hematoxylin and eosin stained section; original magnification $\times 100$. Upper right inset shows polypoid solid fragments of tissue; lower left inset depicts sporangia enclosing endospores maturing centripetally (white arrow). Insets: original magnification $\times 200$.

multiple sporangia, 50 to >450 μm in diameter, in various stages of maturity. During maturation, chitinous-walled sporangia contain numerous developing endospores 2–10 μm in diameter (8,9). The nucleated nature of the pathognomic structures precludes identifying the causative agent as *Microcystis*, a gram-negative, phototrophic prokaryote associated particularly with eutrophic lacustrine environments (8).

Treatment of rhinosporidiosis is limited to the surgical removal of polyps and electrocauterization at the attachment base; some clinicians prescribe a prolonged postoperative course of diaminodiphenyl sulfone (dapsone) alone or as part of a multidrug antimicrobial regimen (4–7). Although not curative, those adjuvants are thought to impede sporangial and endospore maturation. Refractory cases may occur because of incomplete excision, infection of the traumatized surgical sites by released endospores, or reinfection from an endospore reservoir (e.g., lymph) in disseminated cases (4,5). Recurrence, dissemination to adjacent anatomic sites, and local secondary bacterial infections are the most frequent complications (3). Although rhinosporidiosis is rarely fatal, diagnosis and treatment can be lifesaving when nasal infections seed to the tracheobronchial tree (6).

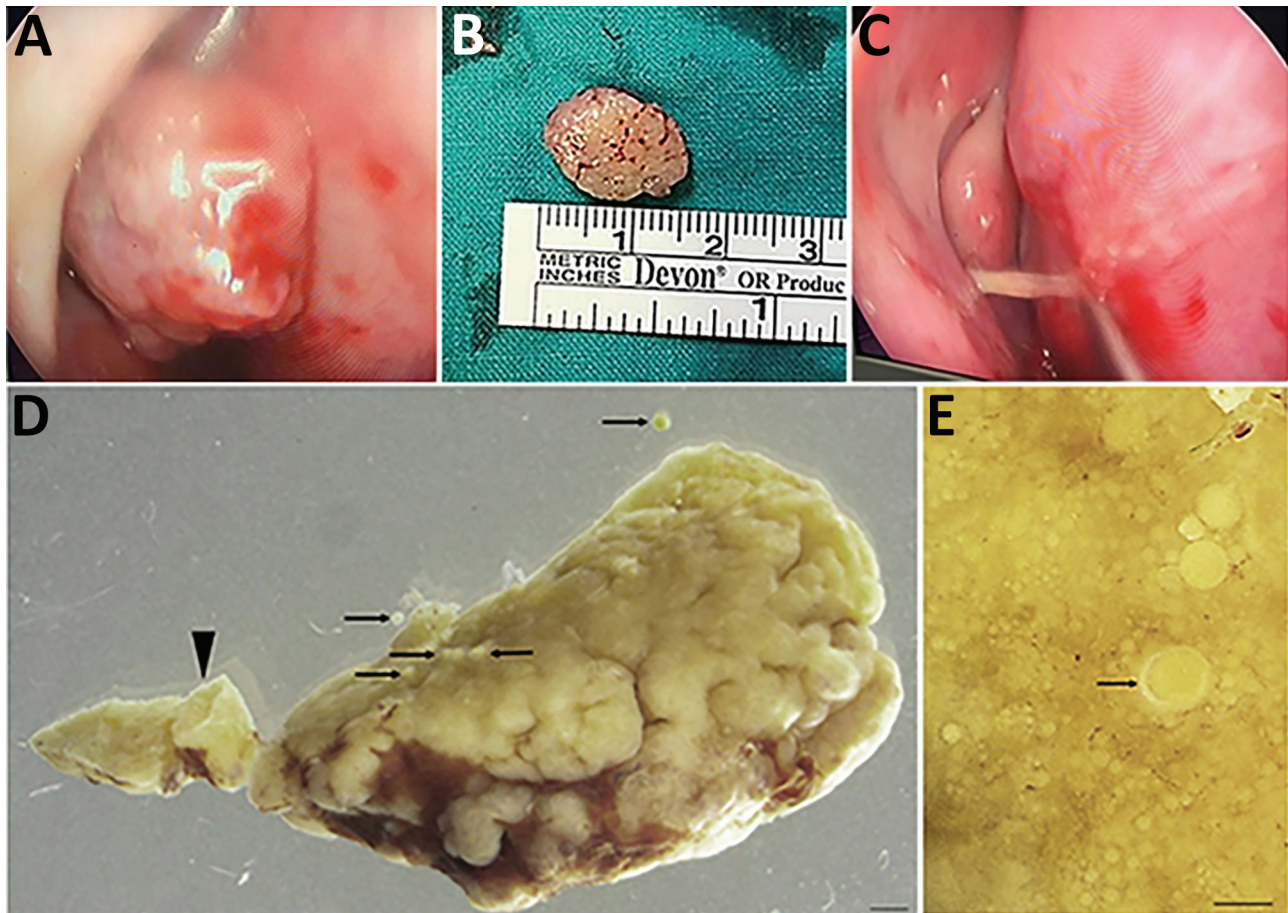


Figure 2. Macromorphology of excised recurrent nasal polyp from a 24-year-old Black woman with rhinosporidiosis, South Africa. A) Intraoperative endoscopic image of mass in right nasal cavity. B) Polypoid, oval mass measuring 15 mm. C) Stalk that attached the mass to the nasal septum. D) Portion of the pedunculated polyp (arrowhead) dotted with developing and mature sporangia (arrows). Scale bar = 1 mm. E) Surface of tissue with multiple sporangia in various stages of maturity, with the chitinous wall thickening during maturation (arrow). Scale bar = 150 μ m.

The highest incidence of rhinosporidiosis has been recorded in tropical zones in India and Sri Lanka, followed by South America and Africa, but sporadic autochthonous cases have been reported from tropical and subtropical regions of all continents except Australia and Antarctica (Appendix Table). Three case series and 5 case reports document cases in South Africa (Table); the first reported case was identified by a phy-

sician with clinical experience in southern India (10). Most cases have been among male children and teenagers, most with conjunctival infections. Reports from several other countries in Africa, including Cameroon, Ivory Coast, Kenya, Malawi, Tanzania, Uganda, Zaire, and Zambia, are most commonly conjunctival infections. Conversely, data from Rwanda and composite global reports indicate $\approx 70\%$ of infections are nasal or

Table. Case reports of rhinosporidiosis in South Africa*

Location of exposure or reporting facility†	Age, y/sex (no.)	Infection site	Date reported	Reference
Driefontein, Ladysmith, KwaZulu-Natal	12/M	Nasal	1951	(10)
Edendale Hospital, Pietermaritzburg, KwaZulu-Natal	10/M	Ocular	1959	(11)
Edendale Hospital, Pietermaritzburg, KwaZulu-Natal	12/M	Nasal	1977	(12)
Edendale Hospital, Pietermaritzburg, KwaZulu-Natal	14/M	Nasal	1977	(12)
King Edward VIII Hospital, Durban, KwaZulu-Natal	9–15/M (4), F (2)	4 ocular, 2 nasal	1987	(13)
Umtata General Hospital, Mthatha, Eastern Cape	<15/M (3), F (3)	6 ocular	2005	(14)
Sefako Makgatho Health Sciences University, Ga-Rankuwa, Gauteng	17/M	Nasal	2017	(15)
Chris Hani Baragwanath Academic Hospital, Johannesburg, Gauteng	24/F	Nasal	2022	This study

*All patients were Black persons from Africa.

†Name of facility at date of publication.

nasopharyngeal infections (5,9). Misdiagnosis of nasal rhinosporidiosis in some countries in Africa could account for the predominance of reported conjunctival infection in those countries.

Despite the diagnostic simplicity of rhinosporidiosis, it is unknown if *Rhinosporidium* might have a noninfectious saprophytic developmental phase or natural hosts; how long spores are viable also remains unknown. In addition, the potential role of climate change on the epidemiology of rhinosporidiosis in South Africa is a topic for future research.

In conclusion, our study adds information about the epidemiology and diagnosis of rhinosporidiosis. Because the disease might be misdiagnosed by clinicians who are unaware of its clinical characteristics, providing education could improve rates of accurate diagnosis, leading to better disease surveillance and control efforts.

Acknowledgments

For assistance with the microbiological diagnosis of rhinosporidiosis, the authors acknowledge John Freaun and Charlotte Sriruttan-Nel. For assistance with retrieving histopathology slides, the authors acknowledge members of the Histopathology Department at National Health Laboratory Services, Chris Hani Baragwanath Academic Hospital. We also thank the staff of the Electron Microscope Unit of Sefako Makgatho Health Sciences University for facilitating the scanning electron microscopy.

Author contributions: H.M., T.B.A., and D.L.R. compiled the initial manuscript, M.B. wrote all subsequent versions. H.M., T.B.A., Y.A., and D.L.R. were responsible for the clinical management of the patient. S.P. confirmed the histopathological diagnosis. T.M. and N.P.G. assisted with the panfungal PCR confirmation of the diagnosis, and T.M. performed the molecular analysis. S.P. and M.B. were responsible for the photomicrography. M.B. was responsible for the scanning electron microscopy images. All authors contributed to and approved the final manuscript.

About the Author

Dr. Mayet is a clinician currently specializing in internal medicine at the University of the Witwatersrand, Johannesburg, South Africa. His research interests include infectious diseases, but currently he is investigating lupus nephritis and its progression to chronic kidney disease.

References

1. Fredricks DN, Jolley JA, Lepp PW, Kosek JC, Relman DA. *Rhinosporidium seeberi*: a human pathogen from a novel group of aquatic protistan parasites. *Emerg Infect Dis*. 2000;6:273–82. <https://doi.org/10.3201/eid0603.000307>
2. Scheid P, Balczun C, Dehling JM, Ammon A, Sinsch U. Rhinosporidiosis in African reed frogs *Hyperolius* spp. caused by a new species of *Rhinosporidium*. *Dis Aquat Organ*. 2015;115:111–20. <https://doi.org/10.3354/dao02888>
3. Mohiuddin IM, Burud S, Harriss M. Rhinosporidiosis reinfection after 20 years – a case report from United Arab Emirates. *Hamdan Med J*. 2021;14:205–7. https://doi.org/10.4103/hmj.hmj_56_21
4. Arias AF, Romero SD, Garcés CG. Case report: rhinosporidiosis literature review. *Am J Trop Med Hyg*. 2020;104:708–11. <https://doi.org/10.4269/ajtmh.20-0291>
5. Ali GM, Goravey W, Al Hyassat SA, Petkar M, Al Maslamani MA, Hadi HA. Recurrent nasopharyngeal rhinosporidiosis: case report from Qatar and review of the literature. *IDCases*. 2020;21:e00901. <https://doi.org/10.1016/j.idcr.2020.e00901>
6. Pradhan S, Sirka CS, Baisakh MR. Polymorphic presentation of disseminated cutaneous rhinosporidiosis in an immunocompetent individual. *Indian J Dermatol Venereol Leprol*. 2018;84:614–7. https://doi.org/10.4103/ijdv.IJDV_52_18
7. John D, Selvin SST, Irodi A, Jacob P. Disseminated rhinosporidiosis with conjunctival involvement in an immunocompromised patient. *Middle East Afr J Ophthalmol*. 2017;24:51–3.
8. Vilela R, Mendoza L. The taxonomy and phylogenetics of the human and animal pathogen *Rhinosporidium seeberi*: a critical review. *Rev Iberoam Micol*. 2012;29:185–99. <https://doi.org/10.1016/j.riam.2012.03.012>
9. Izimukwiye AI, Mbarushimana D, Ndayisaba MC, Bigirimana V, Rugwizangoga B, Laga AC. Cluster of nasal rhinosporidiosis, Eastern Province, Rwanda. *Emerg Infect Dis*. 2019;25:1727–9. <https://doi.org/10.3201/eid2509.190021>
10. Dick AM. Nasal rhinosporidiosis; report of a case in Natal. *S Afr Med J*. 1951;25:270–1.
11. Coetzee T. Rhinosporidiosis of the conjunctiva. *Br J Ophthalmol*. 1959;43:309–11. <https://doi.org/10.1136/bjo.43.5.309>
12. Smith PL. Rhinosporidiosis: case reports. *S Afr Med J*. 1977;51:281.
13. Chetty R, Cooper K. Rhinosporidiosis at King Edward VIII Hospital, Durban – 1976–1985. A report of 6 cases. *S Afr Med J*. 1987;72:217–8.
14. Salazar Campos MC, Surka J, Garcia Jardon M, Bustamante N. Ocular rhinosporidiosis. *S Afr Med J*. 2005;95:950–2.
15. Masilela MMJ, Selepe MS, Masilo L. Nasal rhinosporidiosis in South Africa: review of literature and report of a case. *S Afr Dent J*. 2017;72:420–3.

Address for correspondence: Monica Birkhead, National Institute for Communicable Diseases, Private Bag X4, Sandringham, 2192, South Africa; email: monicab@nicd.ac.za

Case Report of Nasal Rhinosporidiosis in South Africa

Appendix

Methods

Microscopy

Routine protocols were used for tissue processed for light microscopy. For the scanning electron microscopy (SEM) illustrated below, small pieces of tissue no larger than 4 mm³ were fixed in 2.5% glutaraldehyde (EM grade) in 0.1 M sodium cacodylate buffer (pH 7.01, osmotically adjusted with the addition of 0.01 M calcium chloride, 0.1 M sucrose and 0.01 M magnesium chloride). After four days, the tissue blocks were rinsed three times in fresh buffer, post-fixed for 2 hours in 1% osmium tetroxide in buffer, repeatedly rinsed in fresh buffer, and dehydrated in a graded ethanol series at hourly intervals. Once in absolute ethanol, the tissues were stored until usage of an SEM was available. Some of the dehydrated tissue pieces were cut with a razorblade under liquid nitrogen (a 'primitive' cryo technique), then all tissue was chemically dried with hexamethyldisiloxane. Critical point drying, which is preferable for fungal samples (*1*) was not available. Dried specimens were mounted on stubs with carbon adhesive, sputter coated with platinum, and viewed on a Zeiss Supra 55 VP Field Emission Scanning Electron Microscope at 2 KV.

Molecular

The following primers were used for the *LSU* PCR:

LROR: 5' ACCCGCTGAACTTAAGC 3'

LR5: 5' TCCTGAGGGAACTTCG 3'

And for the *ITS* PCR:

ITS1: 5' TCCGTAGGTGAACCTGCGG 3'

ITS4: 5' TCCTCCGCTTATTGATATGC 3'

ITS1: 5' TCCGTAGGTGAACCTGCGG 3'

ITS2: 5' GCTGCGTTCTTCATCGATGC 3'

And for the human beta globin PCR (human specimens):

G1: 5' GAA GAG CCA AGG ACA GGT AC 3'

G2: 5' CAA CTT CAT CCA CGT TCA CC 3'

The PCR method of White et al. (2) was followed. Sequencing was performed by the NICD core facility, and the analyses were done using NCBI (3).

References

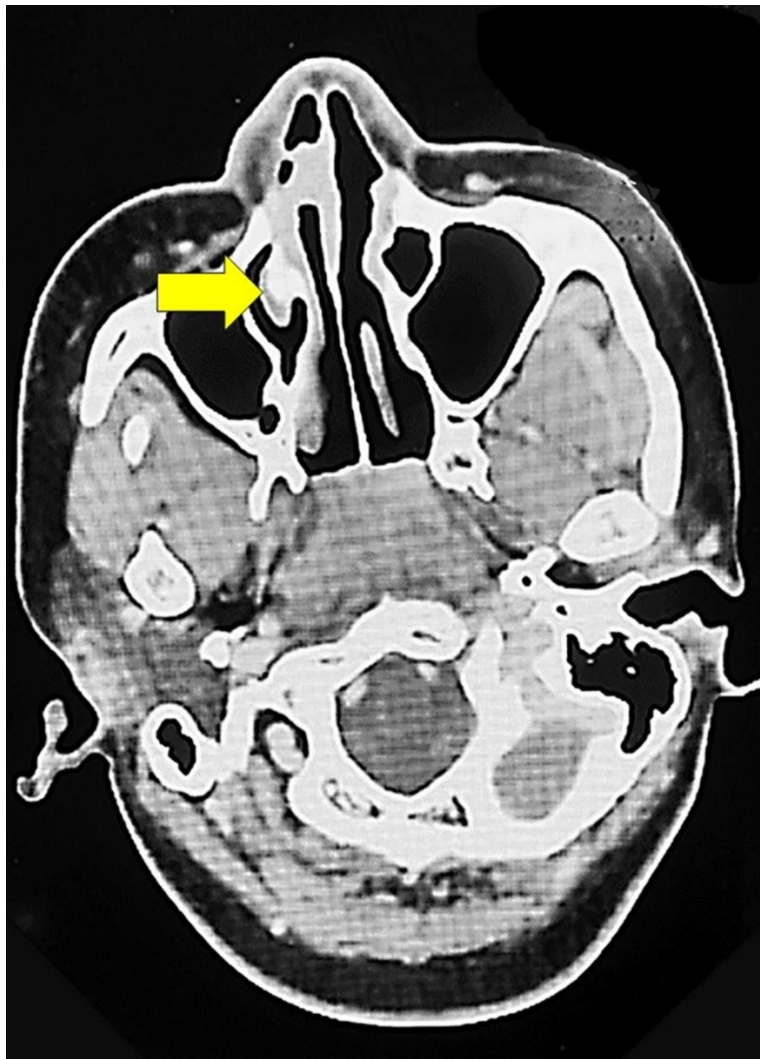1. Gibbons J, Geetha-Loganathan P. Processing Embryo, Eggshell, and Fungal Culture for Scanning Electron Microscopy. *J Vis Exp*. 2019; (150). 10.3791/60018 [PubMed](#)
<https://doi.org/10.3791/60018>
2. White TJ, Bruns T, Lee S, Taylor J. Amplification and direct sequencing of fungal ribosomal RNA genes for phylogenetics. In: Innis MA, Gelfand DH, Sninsky JJ, White TJ, editors. *PCR protocols: a guide to methods and applications*. London: Academic press; 1990. p315–322.
3. Silva V, Pereira CN, Ajello L, Mendoza L. Molecular evidence for multiple host-specific strains in the genus *Rhinosporidium*. *J Clin Microbiol*. 2005;43:1865–8. 10.1128/JCM.43.4.1865-1868.2005
[PubMed](#) <https://doi.org/10.1128/JCM.43.4.1865-1868.2005>
4. Brygoo ER, Bermond C, Dodin A. First Madagascan case of rhinosporidiosis [in French]. *Bull Soc Pathol Exot Filiales*. 1959;52:137–40. [PubMed](#)
5. Desta TW, Kedir A. Conjunctival rhinosporidiosis in an Ethiopian child: a case report. *Int Med Case Rep J*. 2022;15:405–8. [PubMed](#) <https://doi.org/10.2147/IMCRJ.S365729>
6. Gigase P, Kestelyn P. Further African cases of rhinosporidiosis. *Ann Soc Belg Med Trop*. 1993;73:149–52. [PubMed](#)
7. Izimukwiye AI, Mbarushimana D, Ndayisaba MC, Bigirimana V, Rugwizangoga B, Laga AC. Cluster of nasal rhinosporidiosis, Eastern Province, Rwanda. *Emerg Infect Dis*. 2019;25:1727–9. 10.3201/eid2509.190021 [PubMed](#) <https://doi.org/10.3201/eid2509.190021>
8. Udoye EP, Azonobi RI, Opubiri IR. Ocular rhinosporidiosis in a Nigerian child: a case report and literature review from Niger Delta of Nigeria. *J Sci Res Rep*. 2014;4:599–604. <https://doi.org/10.9734/JSRR/2015/14619>

9. Ulzen-Appiah K, Akakpo PK, Brookman SB, Imbeah EG. A rare case of conjunctival rhinosporidiosis mimicking a neoplasm in Ghana. *Postgrad Med J Ghana*. 2022;11:1–4.
<https://doi.org/10.60014/pmjg.v11i2.290>
10. Harissi-Dagher M, Robillard N, Corriveau C, Mabon M, Allaire GS. Histopathologically confirmed ocular rhinosporidiosis in two Canadians. *Can J Ophthalmol*. 2006;41:226–9. [PubMed](#)
<https://doi.org/10.1139/I06-013>
11. Penagos S, Zapata N, Castro JJ, Hidron A, Agudelo CA. Rhinosporidiosis in the Americas: a systematic review of native cases. *Am J Trop Med Hyg*. 2021;105:171–5. [PubMed](#)
<https://doi.org/10.4269/ajtmh.20-1411>
12. Arseculeratne SN, Sumathipala S, Eriyagama NB. Patterns of rhinosporidiosis in Sri Lanka: comparison with international data. *Southeast Asian J Trop Med Public Health*. 2010;41:175–91.
[PubMed](#)
13. Ayub-ur-Rehman MMN, Moallam FA. Rhinosporidiosis. *J Coll Physicians Surg Pak*. 2012;10:671–2.
14. Nguyen VA, Phan ND, Nguyen TL. Two cases of rhinosporidiosis in the Vietnamese [in French]. *Acta Med Vietnam*. 1959;3:763–8. [PubMed](#)
15. Simuangco SA, Bocobo FC, Lacuna L. Review of literature on medical mycology in the Philippines, 1955–1962. *Mycopathol Mycol Appl*. 1963;20:145–56. [PubMed](#)
<https://doi.org/10.1007/BF02054886>
16. Snidvongs ML, Supanakorn S, Supiyaphun P. Severe epistaxis from rhinosporidiosis: a case report. *J Med Assoc Thai*. 1998;81:555–8. [PubMed](#)
17. Thakur SK, Sah SP, Badhu BP. Oculosporeidiosis in eastern Nepal: a report of five cases. *Southeast Asian J Trop Med Public Health*. 2002;33:362–4. [PubMed](#)
18. Alonso MJ, Gomez De Tejada R, Diaz P, Ruiz J, Prieto J. Description of a case of rhinosporidiosis in Spain. *Mycopathologia*. 1987;97:9–16. [PubMed](#) <https://doi.org/10.1007/BF00437325>
19. Vukovic Z, Bobic-Radovanovic A, Latkovic Z, Radovanovic Z. An epidemiological investigation of the first outbreak of rhinosporidiosis in Europe. *J Trop Med Hyg*. 1995;98:333–7. [PubMed](#)
20. Hussein MR, Rashad UM. Rhinosporidiosis in Egypt: a case report and review of literature. *Mycopathologia*. 2005;159:205–7. [PubMed](#) <https://doi.org/10.1007/s11046-004-6388-y>
21. Firouz-Abadi A, Moghimi M, Azad Y. Rhinosporidiosis in Iran (Persia)—a study of seventy-four cases. *Mycopathol Mycol Appl*. 1971;44:249–60. [PubMed](#) <https://doi.org/10.1007/BF02128638>

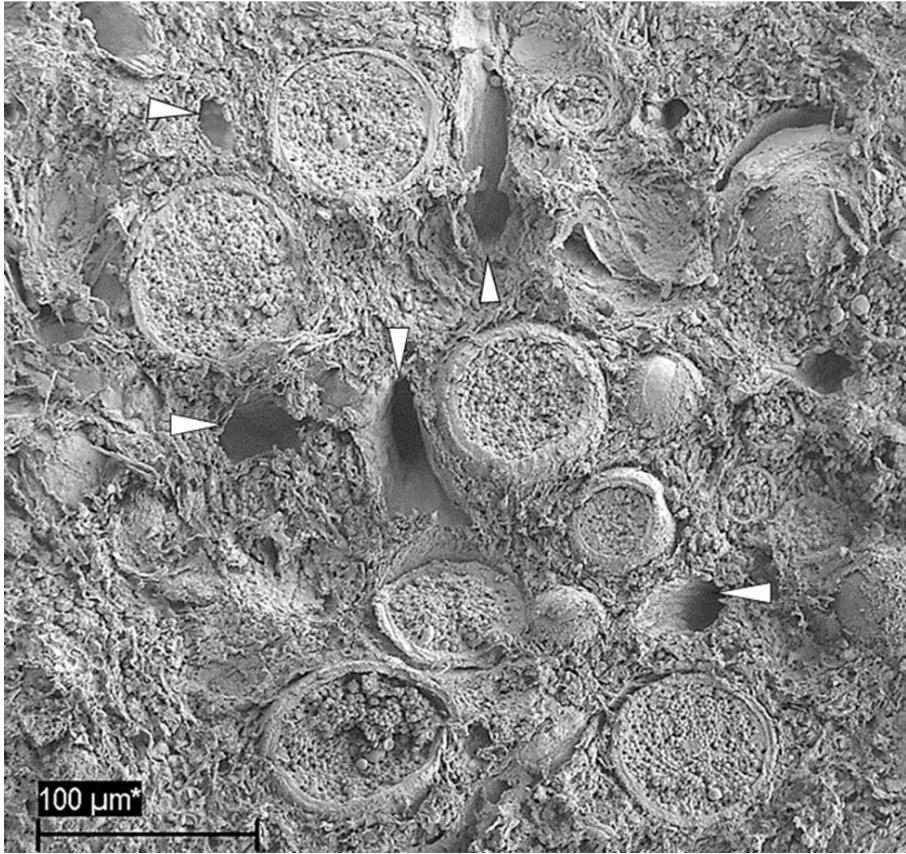
22. Keskin G, Ustündağ E, Kaçarözkarar S, Keskin S. An erosive mass involving the nasal cavity and maxillary sinus: rhinosporidiosis. *Kulak Burun Bogaz Ihtis Derg.* 2004;13:143–7. [PubMed](#)

Appendix Table. Countries reporting autochthonous cases of rhinosporidiosis

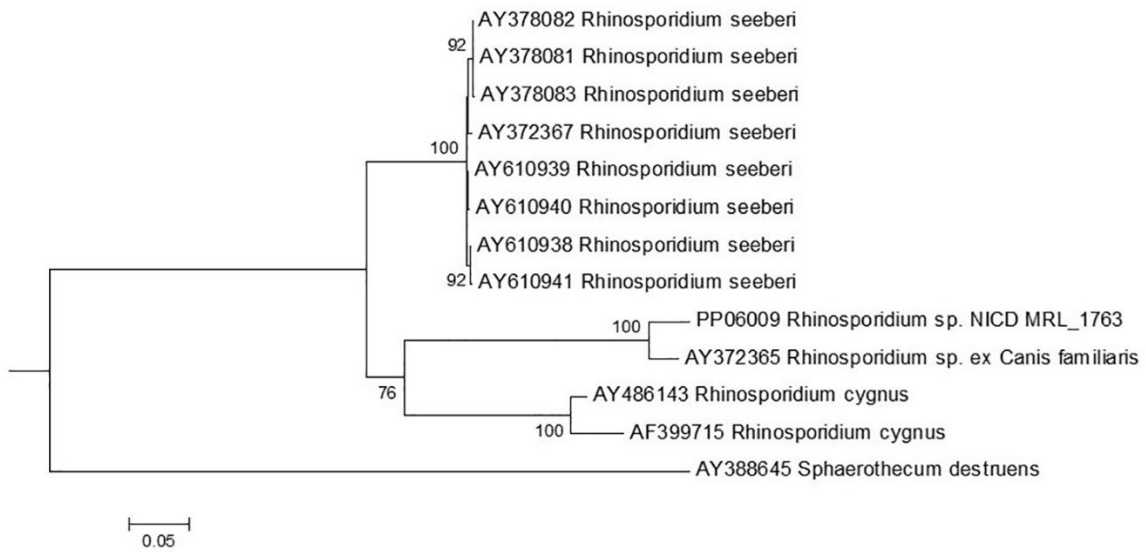
Region	Country	References
Africa	Burundi, Cameroon, Central African Republic, Chad, Congo – Brazzaville, Democratic Rep of Congo (Zaire), Ethiopia, Ghana, Ivory coast, Kenya, Madagascar, Malawi, Nigeria, Rwanda, South Africa, Sudan, Tanzania, Uganda, Zambia	4–9
Central and North America	Canada, Costa Rica, Cuba, Mexico, Panama, USA	10, 11
South America	Argentina, Bolivia, Brazil, Chile, Colombia, Ecuador, French Guyana, Paraguay, Venezuela	11
Asia	India, Indonesia, Nepal, Pakistan, Philippines, Sri Lanka, Thailand, Vietnam	12–17
Europe	Serbia, Spain	18, 19
Middle East	Egypt, Iran, Turkey	20–22



Appendix Figure 1. Computed tomography scan of the nasal cavity, axial section, showing a small homogenous mass with no epithelial extension occupying the anterior part of the right nasal cavity (yellow arrow).



Appendix Figure 2. Scanning electron micrograph of excised nasal polyp (sectioned face) showing the highly vascularized tissue (arrowheads) interspersed with spherical sporangia at various stages of development.



Appendix Figure 3. Phylogenetic relationships of human (*Rhinosporidium seeberi*), dog (*Rhinosporidium sp. canis*), and swan (*Rhinosporidium cygnus*) strains based on *ITS* sequences. The phylogenetic tree is constructed using a neighbor-joining algorithm with 1000 bootstrap replications, following the Jukes-Cantor model. The *ITS* sequence from the case patient is denoted as NICD MRL_1763 and clustered with the sequence obtained from a dog (3).