

Cardoso CC, Brustolini OJ, Gerber AL, et al.; Covid19-UFRJ Workgroup, LNCC Workgroup, Adriana Cony Cavalcanti. Genomic characterization of a novel SARS-CoV-2 lineage from Rio de Janeiro, Brazil. *J Virol*. 2021;95:e00119-21. <https://doi.org/10.1128/JVI.00119-21>

10. US Department of Agriculture, Animal and Plant Health Inspection Service. Confirmation of COVID-19 in a coatimundi at an Illinois zoo, 2021 [cited 2022 Jun 6]. https://www.aphis.usda.gov/aphis/newsroom/stakeholder-info/sa_by_date/sa-2021/sa-10/covid-coatimundi

Address for correspondence: Giliane de Souza Trindade, Universidade Federal de Minas Gerais, Av Antônio Carlos, 6627, Campus Pampulha, Belo Horizonte, 31270-901, Minas Gerais, Brazil; email: giliane@icb.ufmg.br

***Babesia microti* Causing Intravascular Hemolysis in Immunocompetent Child, China**

Jiafeng Yao,¹ Guoging Liu,¹ Yang Zou, Jin Jiang, Shaogang Li, Heng Wang, Xiaoling Cheng, Rui Zhang, Kaige Zhang, Chunyan Wei, Runhui Wu

Author affiliations: Beijing Children's Hospital, Beijing, China (J. Yao, G. Liu, J. Jiang, X. Cheng, R. Zhang, K. Zhang, R. Wu); Capital Medical University, Beijing (Y. Zou, S. Li); Peking Union Medical College School of Basic Medicine, Beijing (H. Wang, C. Wei)

DOI: <https://doi.org/10.3201/eid2903.220888>

We report a case of *Babesia microti* infection in an immunocompetent child <5 years of age that caused fever and severe intravascular hemolysis. Physicians in China should be aware of babesiosis, especially in the differential diagnosis of immune hemolytic anemia with negative results for antiglobulin tests.

Babesiosis, caused by tickborne zoonotic protozoa of the genus *Babesia*, is an emerging health risk to humans. Among the known *Babesia* species infecting humans, *B. microti* is the most common cause of

human babesiosis (1). In China, *B. microti* has caused >100 human cases of babesiosis (2), but nearly all have been reported in adults, particularly the elderly.

B. microti babesiosis has rarely been reported in immunocompetent children in China. We reported a case of severe intravascular hemolysis caused by *B. microti* infection in an immunocompetent preschooler from Shandong Province, China.

The patient, a girl 4 years and 9 months of age, had fever develop (highest temperature 39°C) on September 30, 2021. Antimicrobial drug treatment was not effective. Four days later, her urine became dark, and she had abdominal pain. On October 9, 2021, she was admitted to the hospital because of severe anemia and abnormal laboratory test results (Table). She had shock after a discharge of dark brown urine.

To stabilize her vital signs, we began repeated blood transfusion for supportive treatment. Azithromycin and immune regulatory treatment (high-dose methylprednisolone, 10 mg/kg/d for 3 days, and intravenous immunoglobulin, 1 g/kg/d for 2 d) were not effective. Her symptoms worsened, and her hemoglobin level remained at <60 g/L (Appendix Figure, panel A, <https://wwwnc.cdc.gov/EID/article/29/3/22-0888-App1.pdf>). On the basis of those findings, we excluded congenital hemolytic anemia and autoimmune hemolytic anemia.

We examined her blood smear and observed parasites in the erythrocytes (Appendix Figure, panel B). We used a genus-specific 18S rRNA PCR described previously (3) to confirm *Babesia* infection by amplification of a 515-bp fragment (Appendix Figure, panel C). Test results for malaria infection was negative. Subsequent sequencing of the fragment and BLAST analysis (<https://blast.ncbi.nlm.nih.gov/Blast.cgi>) of the nucleotide sequence showed 100% similarity with *B. microti* RI strain. Those results confirmed the diagnosis as a *B. microti* infection causing severe intravascular hemolytic anemia.

The girl's parents recalled that the child had been in a wild chestnut forest in a suburb of Zaozhuang City, Shandong Province, on September 14, 2021. They found ≈20 red papules and an itching sensation on the trunk and limbs. The papules subsided within 3 days. There were no other complications of babesiosis, such as splenic infarction, acute respiratory distress syndrome, or disseminated intravascular coagulation.

The child was given atovaquone and azithromycin (4) for 21 days, and the urine color became clear within 24 hours. The frequency of erythrocyte transfusion was reduced gradually, and the hemolysis was controlled (Appendix Figure, panel A). On the 10th day after the treatment began, molecular detection

¹These authors contributed equally to this article.

Table. Laboratory test results for *Babesia microti* causing intravascular hemolysis in immunocompetent child, China*

Variable	Age-adjusted reference value or range	Value
Epstein-Barr virus	Negative	Negative
<i>Mycoplasma pneumoniae</i>	Negative	Positive
IgM titer	<1:80	1:80
Drug-resistance gene	Negative	Negative
Leukocyte count, × 10 ⁹ cells/L	4.9–12.7	4.36
Erythrocyte count, × 10 ¹² cells/L	4.1–5.5	2
Hemoglobin, g/L	115–150	57
Mean corpuscular volume, μm ³	76–88	83
Mean corpuscular hemoglobin concentration, g/L	309–359	343
Platelet count, × 10 ⁹ /L	187–475	100
% Reticulocytes	0.5%–2.5%	2.07%
Clotting function	NA	Normal
Bilirubin, μmol/L		
Total	3.42–20.5	55.98
Direct	0–3.42	13.76
Indirect	0–17.1	42.22
Aspartate aminotransferase, U/L	14–44	196.2
Alanine aminotransferase, U/L	7–30	187.6
Lactate dehydrogenase, U/L	110–295	2,899
Antiglobulin tests		
IgG	Negative	Negative
C3d	Negative	Negative
DAT	Negative	Negative
Control	Negative	negative
Spot urine sample		
Urine color	Light yellow	Brown
Ketone body	Negative	1+
Protein	Negative	2+
Urinary bilirubin	Negative	1+
Occult blood	Negative	3+
Centrifugal microscopy for erythrocytes, HPF	0–3	0
Centrifugal microscopy for leukocytes, HPF	0–3	0
Chest computed tomography	NA	Few shadows in lower lobe of right lung, no exudative lesion
Abdominal ultrasound	NA	Splenomegaly

*DAT, direct antiglobulin test; HPF, high-power field; NA, not applicable.

of *B. microti* showed a negative result. The child has been monitored for >6 months and is in good health.

In this case, we confirmed the severe intravascular hemolysis caused by *B. microti* infection in an immunocompetent child <5 years of age. For children in China, although babesiosis caused by *B. venatorum* and *B. crassa*-like parasites was detected in epidemiologic surveys (5,6), few children who have babesiosis caused by *B. microti* and severe hemolysis have been reported. Thus, babesiosis is still unfamiliar to pediatricians. This case implied that *Babesia* infection might be underdiagnosed in China. It is imperative for pediatricians and clinicians to be aware of babesiosis, which has become a newly emerging public health threat globally.

In Shandong Province, where this child lived, only 2 adults who had babesiosis and severe anemia caused by *B. divergens* were documented (7), but *B. microti*-positive (0.58%) hard ticks from the Jiaodong Peninsula in Shandong Province were reported (8). Given that the child did not have a splenectomy, take immunosuppressive drugs, receive

previous blood transfusions, or have other travel histories, her travel history to the wild chestnut forest and subsequent red, itching papules provided strong evidence for *B. microti* infection by tick bites. Detailed epidemiologic survey of *Babesia* infection in tick vectors and reservoir animals in local areas is necessary to provide guidelines for better prevention and control of babesiosis.

Severe babesiosis in immunocompetent persons <50 years of age is rare; only 2 cases have been reported (9,10). We report a case of *B. microti* infection causing severe illness in an immunocompetent child. Better understanding of the pathogenesis of this parasite is necessary. This case indicates that babesiosis cannot be ignored in severe intravascular hemolysis. For patients who have intermittent fever and intravascular hemolysis but negative results for antiglobulin tests, babesiosis should be considered in the differential diagnosis, especially in areas where the tick vector is present. A timely and appropriate treatment for patients who have severe disease that is recognized early is needed.

About the Authors

Dr. Yao is an associate chief physician at Beijing Children's Hospital, Beijing, China. His primary research interest is pediatric hematology. Dr. Liu is a physician at Beijing Children's Hospital, Beijing, China. His primary research interest is pediatric hematology.

References

1. Puri A, Bajpai S, Meredith S, Aravind L, Krause PJ, Kumar S. *Babesia microti*: pathogen genomics, genetic variability, immunodominant antigens, and pathogenesis. *Front Microbiol*. 2021;12:697669. <https://doi.org/10.3389/fmicb.2021.697669>
2. Zhao GP, Wang YX, Fan ZW, Ji Y, Liu MJ, Zhang WH, et al. Mapping ticks and tick-borne pathogens in China. *Nat Commun*. 2021;12:1075. PubMed <https://doi.org/10.1038/s41467-021-21375-1>
3. Wei CY, Wang XM, Wang ZS, Wang ZH, Guan ZZ, Zhang LH, et al. High prevalence of *Babesia microti* in small mammals in Beijing. *Infect Dis Poverty*. 2020;9:155. <https://doi.org/10.1186/s40249-020-00775-3>
4. Krause PJ, Auwaerter PG, Bannuru RR, Branda JA, Falck-Ytter YT, Lantos PM, et al. Clinical practice guidelines by the Infectious Diseases Society of America (IDSA): 2020 guideline on diagnosis and management of babesiosis. *Clin Infect Dis*. 2021;72:e49–64. <https://doi.org/10.1093/cid/ciaa1216>
5. Jiang JF, Zheng YC, Jiang RR, Li H, Huo QB, Jiang BG, et al. Epidemiological, clinical, and laboratory characteristics of 48 cases of "*Babesia venatorum*" infection in China: a descriptive study. *Lancet Infect Dis*. 2015;15:196–203. [https://doi.org/10.1016/S1473-3099\(14\)71046-1](https://doi.org/10.1016/S1473-3099(14)71046-1)
6. Jia N, Zheng YC, Jiang JF, Jiang RR, Jiang BG, Wei R, et al. Human babesiosis caused by a *Babesia crassa*-like pathogen: a case series. *Clin Infect Dis*. 2018;67:1110–9. <https://doi.org/10.1093/cid/ciy212>
7. Qi C, Zhou D, Liu J, Cheng Z, Zhang L, Wang L, et al. Detection of *Babesia divergens* using molecular methods in anemic patients in Shandong Province, China. *Parasitol Res*. 2011;109:241–5. <https://doi.org/10.1007/s00436-011-2382-8>
8. Zhang H, Sun Y, Jiang H, Huo X. Prevalence of severe febrile and thrombocytopenic syndrome virus, *Anaplasma* spp. and *Babesia microti* in hard ticks (Acari: Ixodidae) from Jiaodong Peninsula, Shandong Province. *Vector Borne Zoonotic Dis*. 2017;17:134–40. <https://doi.org/10.1089/vbz.2016.1978>
9. Gonzalez LM, Rojo S, Gonzalez-Camacho F, Luque D, Lobo CA, Montero E. Severe babesiosis in immunocompetent man, Spain, 2011. *Emerg Infect Dis*. 2014;20:724–6. <https://doi.org/10.3201/eid2004.131409>
10. Selig T, Ilyas S, Theroux C, Lee J. Fatal babesiosis in an immunocompetent patient. *R I Med J* (2013). 2022;105:20–3.

Address for correspondence: Chunyan Wei, Department of Microbiology and Parasitology, Institute of Basic Medical Sciences Chinese Academy of Medical Sciences, School of Basic Medicine, Peking Union Medical College, 5# Dong Dan San Tiao, Dongcheng District, Beijing 100005, China; email: weicy@pumc.edu.cn; Runhui Wu, Beijing Children's Hospital, Capital Medical University, National Center for Children's Health, Beijing, China; email: runhuiwu@hotmail.com

Tick-Borne Encephalitis in Pregnant Woman and Long-Term Sequelae

Aurélie Velay, Ralf Janssen-Langenstein, Stéphane Kremer, Elodie Laugel, Maximilian Lutz, Anne Laure Pierson, Marie-Josée Wendling, Francis Schneider, Samira Fafi-Kremer

Author affiliations: Strasbourg University Hospital, Strasbourg, France (A. Velay, R. Janssen-Langenstein, S. Kremer, E. Laugel, A.L. Pierson, M.-J. Wendling, F. Schneider, S. Fafi-Kremer); Université de Strasbourg, Strasbourg (A. Velay, E. Laugel, S. Fafi-Kremer); Charité Universitätsmedizin Berlin, Berlin, Germany (M. Lutz)

DOI: <https://doi.org/10.3201/eid2903.221328>

We report a case of severe tick-borne encephalitis in a pregnant woman, leading to a prolonged stay in the intensive care unit. She showed minor clinical improvement >6 months after her presumed infection. The patient was not vaccinated, although an effective vaccine is available and not contraindicated during pregnancy.

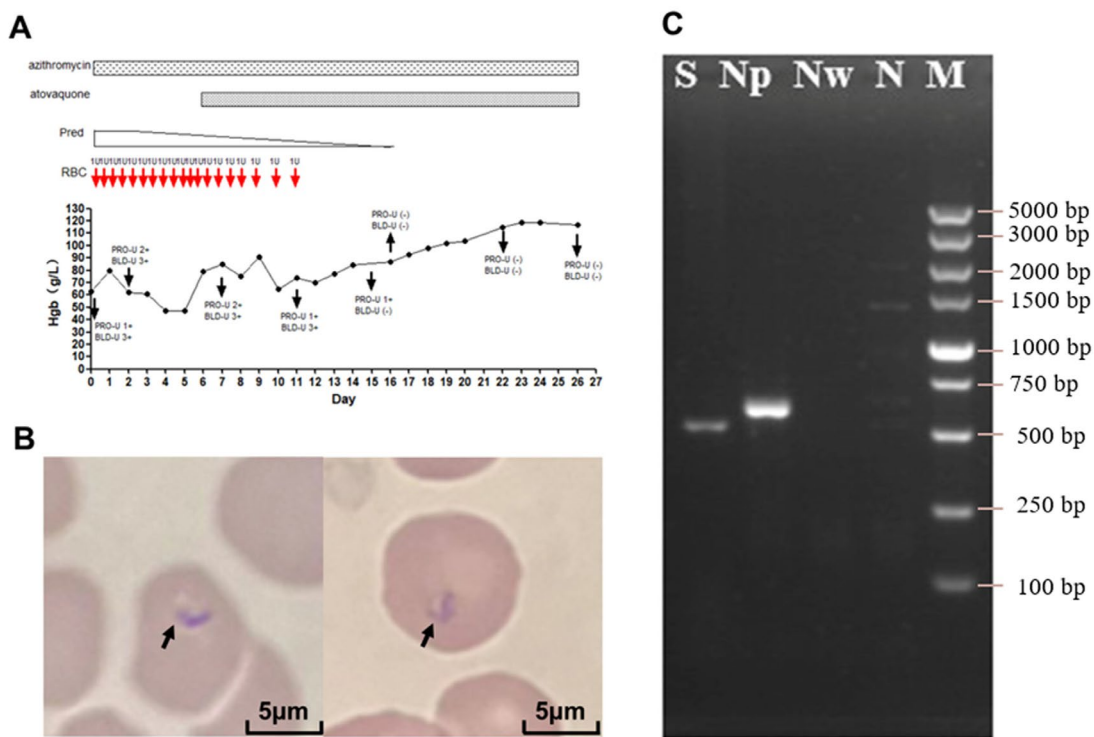
Tick-borne encephalitis (TBE), an emerging infectious disease, has shown a deeply evolving epidemiology during the past decade, especially in Europe (1). TBE virus (TBEV) is transmitted mainly to humans by tick bites and occasionally by consumption of contaminated dairy products (1). Although most infections caused by the TBEV European subtype are asymptomatic, some patients' conditions could worsen to show severe encephalitis, associated with long-term sequelae (1). Data dealing with TBEV infection during pregnancy are scarce. We report a case of severe TBE and long-term sequelae in a pregnant woman.

In July 2020, a 34-year-old woman at 20 weeks of gestation was admitted to an emergency department in Strasbourg, France, because of meningismus associated with nystagmus. The patient lived in Berlin, Germany, traveled to the Black Forest (Germany), and visited Provence (southeastern France) and Alsace (northeastern France) on the way home before symptom onset.

On day 3, TBEV serologic results were positive for IgM and negative for IgG (Figure). The patient progressed to severe hyperactive delirium, requiring sedation and intubation. After a second lumbar puncture, results of reverse transcription PCR testing of cerebrospinal fluid (CSF) was positive for TBEV (Figure). A second MRI showed signs of diffuse leptomeningitis

Babesia microti Causing Intravascular Hemolysis in Immunocompetent Child, China

Appendix



Appendix Figure. *Babesia microti* infection causing severe intravascular hemolysis in an immunocompetent child, China. A) Time course of infection. BLD-U, urine occult blood; Hgb, hemoglobin; Pred, prednisolone; PRO-U, urine protein RBC, red blood cell. Each red arrow indicates transfusion of 1 unit of RBCs. B) Blood smear showing parasites (arrows) in RBCs (a strain with 100% similarity with *B. microti* strain RI; hematoxylin and eosin stained). C) Electrophoresis of genus-specific 18S rRNA PCR products showing *Babesia* spp. infection (intense amplification of a 515-bp fragment) in patient. Lane S, *Plasmodium falciparum* 3D7 strain; lane NP, RBCs from patient; lane Nw, water; lane N, standard RBCs; lane M, DNA marker.