

Group A *Streptococcus* Primary Peritonitis in Children, New Zealand

Amanda Taylor, Brodie M. Elliott, John Atkinson, Sally Roberts, Lesley Voss, Emma J. Best, Rachel Webb



In support of improving patient care, this activity has been planned and implemented by Medscape, LLC and Emerging Infectious Diseases. Medscape, LLC is jointly accredited with commendation by the Accreditation Council for Continuing Medical Education (ACCME), the Accreditation Council for Pharmacy Education (ACPE), and the American Nurses Credentialing Center (ANCC), to provide continuing education for the healthcare team.

Medscape, LLC designates this Journal-based CME activity for a maximum of 1.00 **AMA PRA Category 1 Credit(s)**™. Physicians should claim only the credit commensurate with the extent of their participation in the activity.

Successful completion of this CME activity, which includes participation in the evaluation component, enables the participant to earn up to 1.0 MOC points in the American Board of Internal Medicine's (ABIM) Maintenance of Certification (MOC) program. Participants will earn MOC points equivalent to the amount of CME credits claimed for the activity. It is the CME activity provider's responsibility to submit participant completion information to ACCME for the purpose of granting ABIM MOC credit.

All other clinicians completing this activity will be issued a certificate of participation. To participate in this journal CME activity: (1) review the learning objectives and author disclosures; (2) study the education content; (3) take the post-test with a 75% minimum passing score and complete the evaluation at <http://www.medscape.org/journal/eid>; and (4) view/print certificate. For CME questions, see page XXX.

NOTE: It is Medscape's policy to avoid the use of Brand names in accredited activities. However, in an effort to be as clear as possible, the use of brand names should not be viewed as a promotion of any brand or as an endorsement by Medscape of specific products.

Release date: October 16, 2023; Expiration date: October 16, 2024

Learning Objectives

Upon completion of this activity, participants will be able to:

- Analyze clinical characteristics of pediatric cases of Group A *Streptococcus* primary peritonitis in the current study
- Assess microbiologic findings in the current series of pediatric cases of Group A *Streptococcus* primary peritonitis
- Evaluate clinical outcomes of Group A *Streptococcus* primary peritonitis among children

CME Editor

Jill Russell, BA, Technical Writer/Editor, Emerging Infectious Diseases. *Disclosure: Jill Russell, BA, has no relevant financial relationships.*

CME Author

Charles P. Vega, MD, Health Sciences Clinical Professor of Family Medicine, University of California, Irvine School of Medicine, Irvine, California. *Disclosure: Charles P. Vega, MD, has the following relevant financial relationships: served as consultant or advisor for Boehringer Ingelheim Pharmaceuticals, Inc.; GlaxoSmithKline; Johnson & Johnson.*

Authors

Amanda Taylor, MBChB; Brodie M. Elliott, MBChB; John Atkinson, MBChB, FRACS; Sally Roberts, MBChB, FRACP, FRCPA; Lesley Voss, MBChB, FRACP; Emma J. Best, MBChB, FRACP, MMED; and Rachel Webb, MBChB, FRACP, MD.

Author affiliations: Starship Children's Hospital, Auckland, New Zealand (A. Taylor, B.M. Elliott, J. Atkinson, L. Voss, E.J. Best, R. Webb); The University of Auckland, Auckland (A. Taylor, E.J. Best, R. Webb); LabPLUS, Auckland City Hospital,

Auckland (S. Roberts); Kidz First Hospital, Counties Manukau, Auckland (R. Webb)

DOI: <https://doi.org/10.3201/eid2911.230211>

Group A *Streptococcus* (GAS) primary peritonitis is a rare cause of pediatric acute abdomen (sudden onset of severe abdominal pain); only 26 pediatric cases have been reported in the English language literature since 1980. We discuss 20 additional cases of pediatric primary peritonitis caused by GAS among patients at Starship Children's Hospital, Auckland, New Zealand, during 2010–2022. We compare identified cases of GAS primary peritonitis to cases described in the existing pediatric literature. As rates of rates of invasive GAS increase globally, clinicians should be aware of this cause of unexplained pediatric acute abdomen.

Streptococcus pyogenes, or group A *Streptococcus* (GAS), causes a wide spectrum of disease ranging from superficial skin infection and pharyngitis to invasive infections, such as sepsis, empyema, necrotizing fasciitis, meningitis, osteomyelitis, and septic arthritis (1). GAS is responsible for the toxin-mediated complications of scarlet fever and streptococcal toxic shock syndrome, as well as the postinfectious sequelae rheumatic fever and poststreptococcal glomerulonephritis (2).

Primary peritonitis is defined as a bacterial infection within the peritoneal cavity in the absence of ascites or an intraabdominal source of infection, such as appendicitis (3,4). Primary peritonitis is an uncommon manifestation of invasive GAS (iGAS) disease; a 2016 report found it accounted for 4.6% of children with iGAS in Finland (5). Pediatric primary peritonitis itself is rare, reportedly accounting for 1%–3% of children experiencing acute abdomen (sudden onset of severe abdominal pain), and is most commonly caused by *S. pneumoniae*, gram-negative organisms, and staphylococcal species (3).

In late 2022, the United Kingdom, United States, Australia, and several countries in Europe reported unexpectedly high rates of iGAS and scarlet fever, particularly in children <10 years of age (6–10). Rates of iGAS in the United Kingdom during this period are reported to be higher than in the years before the COVID-19 pandemic (2017–2019) and substantially higher than those reported during 2020–2021 (11). With increased GAS circulation, media coverage, and heightened community awareness, clinicians globally should be aware of the vast spectrum of invasive disease caused by GAS, including primary peritonitis.

In New Zealand, iGAS disease is not notifiable to Public Health authorities (12). Surveillance relies on individual laboratories sending clinically relevant iGAS isolates to the Institute of Environmental Science and Research (ESR) for typing (13). The most recent ESR report (2016) describes an iGAS incidence of 9.0/100,000 population in New Zealand;

rates were inequitably high among New Zealand Māori (23.5/100,000 population) and Pacific peoples (73.9/100,000 population) compared with rates among persons of European or other ethnicities (4.3/100,000 population) (13). Incidence of iGAS is highest in children <1 year of age (13). Although ESR laboratory surveillance provides some information on the burden of iGAS in New Zealand, its passive nature suggests that reported rates are likely to be an underestimate.

Consistent with the high burden of iGAS disease in children in New Zealand, clinicians at Starship Children's Hospital in Auckland have observed that GAS is a major cause of primary peritonitis in the pediatric population. We evaluated the incidence, clinical features, and management of children admitted to this tertiary pediatric center with GAS primary peritonitis during January 1, 2010–June 30, 2022, to provide a better understanding of the clinical features of GAS primary peritonitis in a contemporary setting with a high burden of iGAS disease. In addition, we reviewed and compared identified cases with reports in the English language literature.

Methods

We performed a retrospective observational study of children admitted to Starship Children's Hospital with GAS primary peritonitis during January 1, 2010–June 30, 2022. Starship Children's Hospital is a tertiary hospital with a surgical department that primarily serves Auckland and northern New Zealand. It contains the country's only pediatric intensive care unit (PICU), and complex cases from across New Zealand are frequently transferred to the facility for surgical management.

We included children <15 years of age who had primary peritonitis, defined as bacterial infection within the peritoneal cavity in the absence of ascites or an intraabdominal source of infection either confirmed on abdominal imaging (typically free intraabdominal fluid and peritoneal enhancement with small bowel dilation and bowel wall thickening) (14) or operative findings (free fluid in the abdomen without intraabdominal or gynecological pathology) (3); and from whom GAS had been isolated from culture or molecular methods from blood culture, peritoneal fluid, peritoneal tissue, or intraoperative peritoneal swab samples (3,4). We excluded children with peritonitis secondary to preexisting ascites or an indwelling peritoneal dialysis catheter or device; children in whom an intraabdominal source of infection, such as a perforated viscus, acute appendicitis, or gynecological pathology, had been identified; or in whom

another bacterial cause of primary peritonitis had been identified, by culture or molecular method, from any of blood culture, peritoneal fluid, peritoneal tissue, or intraoperative peritoneal swab sample.

A.T. reviewed electronic notes, imaging, operative findings, and microbiology of all possible cases to determine whether persons met the study criteria. A multidisciplinary team of the remaining authors then discussed possible cases; the team consisted of pediatric surgeons, pediatric infectious disease specialists, and a clinical microbiologist.

We reviewed 4 data sources for case ascertainment. The first source was Pediatric Infectious Diseases (ID) daily handover lists from the Starship Pediatric ID service inpatient consultation service, which are Microsoft Word documents stored in a password-protected folder on the Starship hospital server. They are manually updated each day by the Starship Pediatric ID team with a summary of all active referrals, including patient diagnosis and relevant microbiology. We searched all handover lists during the study period were electronically searched for the terms "peritonitis," "group A *Streptococcus*," "GAS" and/or "*Streptococcus pyogenes*." Second, we searched for codes from the International Classification of Diseases, 10th Revision (ICD-10), from discharge summaries of patients at Starship Children's Hospital during the study period for primary diagnosis peritonitis or acute peritonitis (codes K65.-, P78.0, P78.1, N73.3, N73.4, N73.5, K35.2, K35.3, K57.0-, K57.2-, K57.4-, K57.8-), with or without secondary group A streptococcus (codes B95.0, A40.0). Third, we requested national reference laboratory data from the New Zealand ESR for children <15 years of age with iGAS isolates sent from LabPLUS (Starship Hospital laboratory service) for *emm* typing. All laboratories in New Zealand are asked to send clinically relevant iGAS isolates to ESR for typing. Clinically relevant iGAS isolates are defined as GAS from a normally sterile body site (e.g., blood, cerebrospinal fluid, pleural fluid, peritoneal fluid, synovial fluid) consistent with the US Centers for Disease Control and Prevention definition of iGAS (13). Last, we reviewed LabPLUS microbiology data for children with GAS culture-positive or molecular test-positive peritoneal or abdominal aspirates, tissue, or peritoneal swab samples and GAS-positive blood cultures.

We subsequently conducted a review of the English literature from 1980 onward using PubMed and the search terms "streptococcus pyogenes" [MeSH] OR "group A streptococc*" OR "streptococcal infection*" OR "invasive GAS" OR "invasive group A streptococc*" AND primary peritonitis

[MeSH]. We identified additional cases by reviewing references and citations of articles identified from the initial PubMed search. We excluded cases in which a primary etiology of peritonitis (e.g., peritoneal dialysis, gynecological or abdominal pathology) had been identified.

This study received Auckland Health Research Ethics Committee approval (AH24823). We performed data collection and descriptive analyses using Microsoft Excel.

Results

We identified 253 possible cases at the hospital during the study period. Of those, 20 cases met the study inclusion criteria for GAS primary peritonitis (Appendix Table, <http://wwwnc.cdc.gov/EID/article/29/11/23-0211-App1.pdf>). Only 2/20 (10%) were identified from all 4 data sources and 5/20 (20%) were notified to ESR by LabPLUS. We compared patient demographics and clinical features to features described in previous case reports (Table).

Ethnicity was recorded as New Zealand Māori for 3/20 (15%) children and Pacific peoples for 8/20 (40%) children. Comorbidities were present in 3 children: 1 child was born at 29 weeks' gestation with hypoxic ischemic encephalopathy, 1 had suspected immunodeficiency, and 1 child had a periodic fever syndrome.

Median symptom duration before admission was 3.5 days (range 1–8 days). We reviewed clinical notes to identify possible skin or pharyngeal sources. A possible skin source was identified in 5/20 (25%) children; sources were a foot wound with cellulitis, a leg wound with cellulitis, vaginal erythema and discharge, groin cellulitis, and scrotal erythema with discharge. Skin swab samples were culture-positive for GAS in 4/5 children with possible skin sources. One child was documented as having pharyngitis the week before admission, although no throat swab sample was collected. Although the presence of skin or pharyngeal infection in household contacts was infrequently documented, 1 child's father had confirmed GAS pharyngitis the week before the child's hospitalization.

Of the 22 cases identified as primary peritonitis on ICD-10 codes, 13/22 had positive microbiology. GAS was cultured from 11/22 (50%). One case each of *S. pneumoniae* and *S. anginosus* primary peritonitis was identified.

A total of 19/20 cases of GAS primary peritonitis were culture-positive for GAS from blood or intraoperative peritoneal samples. In 3/19 cases, GAS was cultured from blood or peritoneal samples at the original hospital before the patient was transferred to

SYNOPSIS

Table. Comparison of characteristics of cases of pediatric GAS primary peritonitis at Starship Children's Hospital, New Zealand, 2010–2022, to previously described cases*

Pediatric GAS primary peritonitis	Cases from literature review, 1980–2022, n = 26 [3,4,14–30]	Cases from Starship Hospital, Jan 1, 2010–Jun 30, 2022, n = 20
Median age (range)	7 y (2 wk–16 y)	2 y (3 wk–13 y)
Sex		
F	16/19 (84)	11/20 (55)
M	3/19 (16)	9/20 (45)
Preceding throat or skin infection		
Pharyngitis	4/18 (22)	1/20 (5)
Skin	3/18 (17)	5/20 (25)
STSS	7/18 (39)	6/20 (30)
Microbiology		
Peritoneal fluid or tissue	25/26 (96)	17/20 (85)
Blood culture	5/26 (19)	9/20 (45)
Other	1/26†	4/20 (20)‡
Molecular method (16S)	3/25 (12)	0/20
Culture	22/25 (88)	19/20 (95)
Surgery		
Laparoscopy or laparotomy	21/25 (84%)§	19/20 (95)
VATS only	NA	1/20 (5)
Median antibiotic duration (range), d	14 (10–61)	21 (14–42)
Clindamycin treatment	4/14 (29)	4/20 (20)
IVIG treatment	3/14 (21)	1/20 (5)
Median length of hospital stay (range), d	10 (4–47)	13 (5–31)
Deaths	0/19	0/20
<i>emm</i> types	3.1 (n = 1)	88 (n = 1), 65/69 (n = 1), 114 (n = 2), 118 (n = 1)§
M-type	M3 (n = 1), M81 (n = 1), M2 (n = 1)	NA

*Values are no. (%) except as indicated. IVIG, intravenous immunoglobulin; NA, not available; STSS, streptococcal toxic shock syndrome; VATS, video-assisted thoracoscopic surgery.

†From pleural aspirate.

‡From skin swab samples; 3/4 GAS-positive skin swabs also had a positive blood or intraoperative peritoneal culture.

§5/20 isolates were sent for *emm* typing.

Starship Hospital. In 7/20 cases, both blood culture and peritoneal culture were GAS-positive (on tissue, aspirate, or intraoperative swab sample). Two of 20 cases were blood culture-positive and peritoneal culture-negative. Half (10/20) were peritoneal culture-positive and blood culture-negative. No patients were identified by molecular methods.

We included 1 patient despite negative blood and peritoneal cultures because intraoperative and imaging findings were consistent with primary peritonitis and because GAS was cultured from a swab sample of vaginal discharge taken at admission. That patient had 2 intraoperative peritoneal swab samples (obtained after antimicrobial treatment) that were culture-negative but demonstrated gram-positive cocci. No molecular method could be performed on the swabs. It was the multidisciplinary team's consensus opinion that this patient should be included as a probable case of GAS primary peritonitis.

One quarter (5/20) of iGAS isolates from this series were sent to ESR from LabPlus for typing and surveillance. In total, primary peritonitis represented 4.6% (5/108) of pediatric iGAS isolates sent to ESR from LabPLUS during the study period.

US Centers for Disease Control and Prevention criteria for streptococcal toxic shock syndrome (STSS)

were met in 6/20 cases (30%), and 10/20 (50%) patients were admitted to the PICU; 5/10 (50%) patients required ventilation and 6/10 (60%) required inotropes (9). A total of 4/20 (20%) patients were given adjunctive clindamycin, and 1/20 received intravenous immunoglobulin. Of those who received clindamycin, 2 patients had STSS, 1 had presumed β -lactam-induced neutropenia, and 1 had clindamycin added to their existing treatment for evolving empyema. The average duration of total antibiotic treatment in our series was 21 days (range 14–42 days), and the average hospital stay was 13 days (range 5–31 days). No deaths occurred within 90 days of hospital admission. One patient was readmitted to the hospital because of intolerance of oral antibiotics.

Discussion

GAS primary peritonitis is a rare but noteworthy cause of pediatric acute abdomen; only 26 pediatric cases have been reported in the English literature since 1980 (Table) (3,5,14–30). We describe a large single-center pediatric cohort of 20 cases in patients admitted to Starship Children's Hospital, New Zealand, during 2010–2022. This study contributes to existing knowledge of the clinical manifestations, treatment, and trajectory of children with GAS primary peritonitis.

In the context of increasing rates of iGAS globally, our case series should increase awareness among clinicians of this manifestation of iGAS disease.

In our series, GAS was the most common pathogen isolated from children with an ICD-10 discharge code of primary or acute peritonitis. This finding contrasts with previous reports that found more common pediatric primary peritonitis causes were *S. pneumoniae*, staphylococci, and gram-negative organisms (3). Although this retrospective, observational study did not aim to assess the causative pathogens of all primary peritonitis cases, key pathogens could have changed over time; this possibility should be the focus of further study. Our findings could be explained by the high burden of iGAS in New Zealand children, particularly among Māori and Pacific peoples, who were overrepresented in our case series (accounting for 55% of cases).

Postulated causes of GAS primary peritonitis include hematogenous spread from the skin or respiratory tract, ascending infection from the female genital tract, and gastrointestinal translocation (4,30). Although GAS is known to colonize the throat, skin, and female genital tract, it is not typically present in intestinal flora (30). Among previously reported pediatric cases, a possible skin or throat source was found in 50% of cases (14). In our cohort, a skin or throat source was identified in a similar proportion of cases (30%). Because of the retrospective nature of our study, clinical records were not always complete. Future studies would benefit from standardized, prospective collection of cases detailing recent pharyngeal, skin, or genitourinary infections (1,3).

Previous reports have suggested that girls are disproportionately affected by GAS primary peritonitis because of ascending genitourinary infection; in 84% (16/19) of previous pediatric case reports where sex was given, the child was a girl (30). This effect was not seen in our cohort, where the median age was younger than that previously reported and 55% of case-patients were girls, suggesting that this route might be less common in younger children (30).

As in previous reports, symptoms of children in our cohort were abdominal pain, nausea, vomiting, and diarrhea. Several cases were initially diagnosed as viral gastroenteritis before deteriorating into peritonism and sepsis (3,14). Of the children in our cohort, 30% met STSS criteria, which is comparable with previous case reports that found an overall STSS incidence of 39% (5,14,15).

Although adult clinical practice guidelines advise nonoperative management, particularly in persons with underlying ascites, previous case reports found

that most (83%) pediatric patients undergo surgery to rule out secondary peritonitis (14,30). This practice was also demonstrated in our series; 95% of patients underwent laparoscopy or laparotomy. Surgical management might aid source control, particularly in patients with STSS where reduction of bacterial load plays a major role (4,14,31). Operative management has also been hypothesized to decrease the duration of illness: a 2020 case report describes a child who was managed nonoperatively and in whom a multiloculated abscess developed that required multiple drains and 61 days of antibiotics (30).

The median total duration of antibiotic treatment in our cohort was 21 days (range 14–42 days), which is 1 week longer than the median duration of 14 days (range 10–61) seen in previous case reports. The additional benefit of clindamycin or intravenous immunoglobulin in the management of GAS primary peritonitis remains unclear; however, those adjunct treatments might have a role in patients with STSS.

Observational case reports alone make it difficult to comment on the importance of operative management or the optimal duration of antibiotic treatment for GAS primary peritonitis; however, despite substantial rates of severe illness in our series (10 cases [50%] required PICU admission), no deaths occurred, and only 1 patient required readmission to the hospital. Furthermore, no deaths have been reported in any pediatric case report of GAS primary peritonitis since the 1980s (14). As such, shorter durations of antibiotics may be reasonable for patients with less severe clinical manifestation, particularly when early surgical source control is achieved.

Although this report describes iGAS infection in a population with an identified high burden of GAS infection, as reports emerge from Europe, the United Kingdom, and the United States describing an increase in iGAS and scarlet fever, pediatricians should be aware of this cause of acute abdomen (6). Identifying iGAS promptly enables antibiotic treatment to be rationalized to penicillin and might enable STSS to be recognized earlier. The international rise in iGAS cases might also provide an opportunity to evaluate the best treatment approach for GAS primary peritonitis and how best to manage close contacts. In New Zealand, no guidelines exist around routine assessment of household contacts of persons with iGAS. The risk for secondary iGAS disease in household contacts is estimated to be 2,000 times higher than the general population risk, substantially higher than that reported for meningococcal disease (500–800 times), which is a notifiable condition in New Zealand (32).

Therefore, identifying highly transmissible iGAS should prompt timely review, collection of throat swab specimens, and consideration of chemoprophylaxis for high-risk household contacts through existing public health communicable disease control services for meningococcal disease and other high-priority close contact infectious diseases (32).

During the study period, GAS primary peritonitis accounted for 4.2% of pediatric iGAS isolates sent to the national reference laboratory from Starship Children's Hospital for *emm*-typing and surveillance. Although this is comparable with a 2016 national surveillance study of pediatric iGAS disease in Finland, which reported a primary peritonitis incidence of 4.6% (7/151) (5), in our series only 5/20 patients with GAS primary peritonitis had their isolates sent for *emm*-typing and surveillance. Starship Hospital is a tertiary referral center, and 3/19 iGAS isolates were cultured at other hospitals in New Zealand. Those isolates could have been sent to ESR by those hospital laboratories, but our observation that only a small number of culture-positive samples at our hospital were sent to ESR suggests that passive surveillance is likely to underestimate the true burden of iGAS in New Zealand. This case series highlights the difficulties of case ascertainment, disease surveillance, and the ability to monitor circulating *emm*-types when a disease is not monitored through prospective national surveillance. In a time of increasing global rates of iGAS disease, the results of this study strengthen calls for enhanced, prospective, national iGAS surveillance (1,6,12,32). Although this cohort is small, strengths include robust case ascertainment from multiple data sources and comprehensive classification of cases through detailed review by a multidisciplinary team of clinicians.

In conclusion, GAS primary peritonitis is an uncommon cause of iGAS disease in children but can cause severe illness. This contemporary case series describes 20 children over a 12.5-year period, 30% of whom met the criteria for STSS and 50% of whom required PICU admission. Our findings reflect the substantial burden of GAS disease in New Zealand. In a time of increasing iGAS rates globally, GAS primary peritonitis should be considered in children experiencing unexplained acute abdomen.

About the Author

Dr. Taylor, a PhD candidate with The University of Auckland, completed this work while employed as a pediatric infectious diseases fellow at Starship Children's Hospital. Her research interests include group A *Streptococcus* and acute poststreptococcal glomerulonephritis.

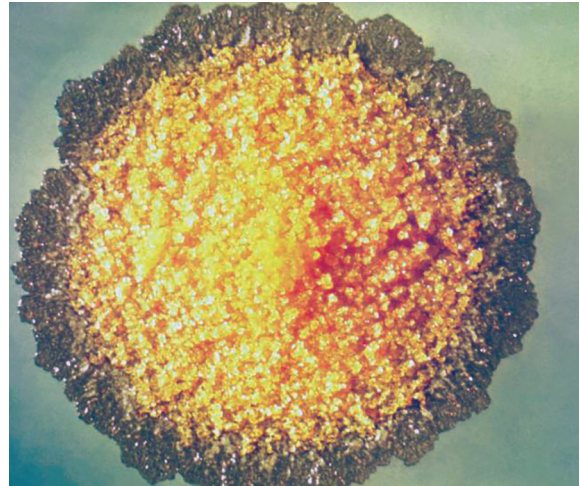
References

1. Miller KM, Lamagni T, Cherian T, Cannon JW, Parks T, Adegbola RA, et al. Standardization of epidemiological surveillance of invasive group A streptococcal infections. *Open Forum Infect Dis*. 2022;9:S31-40. <https://doi.org/10.1093/ofid/ofac281>
2. Safar A, Lennon D, Stewart J, Trenholme A, Drinkovic D, Peat B, et al. Invasive group A streptococcal infection and vaccine implications, Auckland, New Zealand. *Emerg Infect Dis*. 2011;17:983-9. <https://doi.org/10.3201/eid1706.100804>
3. Sharp EA, Linn A, Zitelli BJ. Group A streptococcal pharyngitis associated with primary peritonitis. *BMJ Case Rep*. 2019;12:e229186. <https://doi.org/10.1136/bcr-2019-229186>
4. Westwood DA, Roberts RH. Management of primary group A streptococcal peritonitis: a systematic review. *Surg Infect (Larchmt)*. 2013;14:171-6. <https://doi.org/10.1089/sur.2012.038>
5. Tapiainen T, Launonen S, Renko M, Saxen H, Salo E, Korppi M, et al. Invasive group A streptococcal infections in children: a nationwide survey in Finland. *Pediatr Infect Dis J*. 2016;35:123-8. <https://doi.org/10.1097/INF.0000000000000945>
6. World Health Organization. Increased incidence of scarlet fever and invasive Group A Streptococcus infection – multi-country [cited 2023 Apr 6]. <https://www.who.int/emergencies/disease-outbreak-news/item/2022-DON429>
7. UK Health Security Agency. Group A streptococcus in children – interim clinical guidance summary [cited 2023 Apr 28]. <https://nhs.uk/dorset.nhs.uk/Downloads/aboutus/medicines-management/Other%20Guidelines/PRN00058-group-a-streptococcus-in-children-interim-clinical-guidance-december-2022.pdf>
8. Cobo-Vázquez E, Aguilera-Alonso D, Carrasco-Colom J, Calvo C, Saavedra-Lozano J, Calvo C, et al. Increasing incidence and severity of invasive group A streptococcal disease in Spanish children in 2019–2022. *Lancet Reg Health Eur*. 2023;27:100597.
9. Guy R, Henderson KL, Coelho J, Hughes H, Mason EL, Gerver SM, et al. Increase in invasive group A streptococcal infection notifications, England, 2022. *Euro Surveill*. 2023;28:2200942. <https://doi.org/10.2807/1560-7917.ES.2023.28.1.2200942>
10. MacPhail A, Lee WJL, Kotsanas D, Korman TM, Graham M. A rise in invasive and non-invasive group A streptococcal disease case numbers in Melbourne in late 2022. *Med J Aust*. 2023;218:378-9. <https://doi.org/10.5694/mja2.51909>
11. UK Health Security Agency. Group A streptococcal infections: report on seasonal activity in England, 2022 to 2023 [cited 2023 May 30]. <https://www.gov.uk/government/publications/group-a-streptococcal-infections-activity-during-the-2022-to-2023-season/group-a-streptococcal-infections-report-on-seasonal-activity-in-england-2022-to-2023>
12. Bennet J, Moreland N, Birrell J, Webb R, Kvalsvig A, Roberts S, et al. Likely rise in invasive strep infections in NZ requires a strategy. *Public Health Communication Centre Aotearoa* [cited 2023 Jun 15]. <http://hdl.handle.net/10523/15125>
13. Institute of Environmental Science and Research Ltd (ESR). Invasive group A streptococcal infection in New Zealand, 2016 [cited 2023 May 19]. https://surv.esr.cri.nz/PDF_surveillance/InvasiveGAS/InvGASinfectioninNewZealand2016.pdf
14. Holtestaut T L-BABM. Group A streptococcal primary peritonitis in an otherwise healthy adolescent female. *J Pediatr Surg Case Rep*. 2021;64:101729. <https://doi.org/10.1016/j.epsc.2020.101729>
15. Liang TC, Lu CY, Lu FL, Lee PI, Huang LM. Streptococcal toxic shock syndrome manifesting as peritonitis in a child. *J Formos Med Assoc*. 2002;101:509-13.

16. Goepel JR, Richards DG, Harris DM, Henry L. Fulminant streptococcus pyogenes infection. *BMJ*. 1980;281:1412. <https://doi.org/10.1136/bmj.281.6252.1412>
17. Freij BJ, Votteler TP, McCracken GH Jr. Primary peritonitis in previously healthy children. *Am J Dis Child*. 1984;138:1058-61.
18. Harnden A, Lennon D. Serious suppurative group A streptococcal infections in previously well children. *Pediatr Infect Dis J*. 1988;7:714-8. <https://doi.org/10.1097/00006454-198810000-00010>
19. Torres-Martínez C, Mehta D, Butt A, Levin M. Streptococcus associated toxic shock. *Arch Dis Child*. 1992;67:126-30. <https://doi.org/10.1136/adc.67.1.126>
20. Watson WJ, Powers KS. Primary peritonitis associated with streptococcal toxic shock-like syndrome. *Clin Pediatr (Phila)*. 1999;38:175-7. <https://doi.org/10.1177/000992289903800310>
21. Gillespie RS, Hauger SB, Holt RM. Primary group A streptococcal peritonitis in a previously healthy child. *Scand J Infect Dis*. 2002;34:847-8. <https://doi.org/10.1080/0036554021000026944>
22. Dann PH, Amodio JB, Rivera R, Fefferman NR. Primary bacterial peritonitis in otherwise healthy children: imaging findings. *Pediatr Radiol*. 2005;35:198-201. <https://doi.org/10.1007/s00247-004-1304-7>
23. Sewrey H, Bryant PA. Group A streptococcus causing primary peritonitis in a healthy infant. *Pediatr Infect Dis J*. 2009;28:1146. <https://doi.org/10.1097/INF.0b013e3181b1bd9f>
24. Demitrack J. Primary group A streptococcal peritonitis in a previously healthy child. *Pediatr Infect Dis J*. 2012;31:542-3. <https://doi.org/10.1097/INF.0b013e31824f1b0d>
25. Holden R, Wilmer A, Kollman T. Primary peritonitis due to group A *Streptococcus* in a previously healthy pediatric patient. *Can J Infect Dis Med Microbiol*. 2012;23:e69-70. <https://doi.org/10.1155/2012/105850>
26. Patel RV, Kumar H, More B, Rajimwale A. Primary group A streptococcal septic shock syndrome simulating perforated appendicitis in a previously healthy girl. *BMJ Case Rep*. 2013;2013:bcr2013009502. <https://doi.org/10.1136/bcr-2013-009502>
27. Benidir A, Lim R. Case 1: a 16-year-old female with left lower-quadrant abdominal pain. *Paediatr Child Health*. 2014;19:19-20. <https://doi.org/10.1093/pch/19.1.19>
28. Filan E, Abbas M. Abdominal pain, fever, and infection secondary to an unusual source in a previously healthy child. *Clin Pediatr (Phila)*. 2014;53:607-9. <https://doi.org/10.1177/0009922814526987>
29. Chomton M, Emeriaud G, Bidet P, Rallu F, Ovetchkine P, Gaschignard J. Group A streptococcal primary peritonitis in a healthy girl. *J Paediatr Child Health*. 2017;53:615-6. <https://doi.org/10.1111/jpc.13584>
30. Haskett H, Delair S, Neemann K. Primary group A streptococcal peritonitis in a previously healthy female teenage patient. *Glob Pediatr Health*. 2020;7:2333794X20957647.
31. Sumiyama F, Sakaguchi T, Yamamichi K, Sekimoto M. Peritonitis caused by group A streptococcus: a case report and literature review. *Int J Surg Case Rep*. 2022;92:106839. <https://doi.org/10.1016/j.ijscr.2022.106839>
32. Oliver J, Thielemans E, McMinn A, Baker C, Britton PN, Clark JE, et al. Invasive group A *Streptococcus* disease in Australian children: 2016 to 2018 – a descriptive cohort study. *BMC Public Health*. 2019;19:1750. <https://doi.org/10.1186/s12889-019-8085-2>

Address for correspondence: Amanda Taylor, Pediatric Infectious Diseases Department, Starship Children's Hospital, 2 Park Road, Grafton, Auckland, 1023, New Zealand; email: ATaylor@adhb.govt.nz

EID Podcast *Mycobacterium marinum* Infection after Iguana Bite in Costa Rica



Zoonotic infections associated with animal bite injuries are common and can result in severe illness. Approximately 5 million animal bites occur annually in North America, and 10 million injuries occur globally from dog bites alone. Pathogens causing infections after dog or cat bites are well described; pathogens from other animal bites are less well defined, although their oral microbiota are known.

In this EID podcast, Dr. Niaz Banaei, a professor of pathology and medicine at Stanford University in California, discusses *Mycobacterium marinum* infection after an iguana bite in Costa Rica.

Visit our website to listen:
<https://bit.ly/3Jh2FSI>

**EMERGING
INFECTIOUS DISEASES®**

Article DOI: <https://doi.org/10.3201/eid2911.230211>

EID cannot ensure accessibility for supplementary materials supplied by authors. Readers who have difficulty accessing supplementary content should contact the authors for assistance.

Group A *Streptococcus* Primary Peritonitis in Children, New Zealand

Appendix

Appendix Table. Cases of GAS primary peritonitis admitted to Starship Children's Hospital, New Zealand, January 1, 2010–June 30, 2022, n = 20*

Year	Sex/age	Ethnicity	GAS culture site	Possible skin or pharyngeal source	PICU	Ventilated	Inotropes	Clindamycin or IVIG	STSS	Laparoscopy or laparotomy	Total antibiotic duration (days)	LOS (days)	emm type
2010	M/10 mo	NZ European	Blood, peritoneal swab	No	Yes	No	No	No	No	Yes	28	11	65/69
2010	F/17 mo	NZ European	Blood, peritoneal aspirate	No	No	No	No	No	No	Yes	14	10	X
2010	M/5 y	Other European	Peritoneal aspirate, peritoneal swab	Skin	Yes	Yes	Yes	Clindamycin, IVIG	Yes	Yes	21	9	X
2010	F/11 y	NZ European	Peritoneal swab	Pharyngitis, not swabbed	No	No	No	No	No	Yes	16	9	X
2011	F/4 mo	Pacific	Vaginal swab, peritoneal swab	Skin	No	No	No	No	No	Yes	14	9	X
2011	F/6 y	NZ Māori	Gram positive cocci† Blood, peritoneal aspirate, peritoneal swab	No	Yes	Yes	Yes	No	Yes	Yes	28	28	X
2011	F/2 y	Pacific	Blood, peritoneal aspirate, peritoneal swab	No	Yes	No	No	Clindamycin	No	Yes	42	31	118

Year	Sex/age	Ethnicity	GAS culture site	Possible skin or pharyngeal source	PICU	Ventilated	Inotropes	Clindamycin or IVIG	STSS	Laparoscopy or laparotomy	Total antibiotic duration (days)	LOS (days)	emm type
2013	M/14 mo	Pacific	Blood, peritoneal aspirate	No	Yes	Yes	Yes	No	Yes	Yes	21	21	X
2014	M/3 wks	NZ Māori	Blood, Peritoneal aspirate	No	Yes	Yes	Yes	No	No	Yes	28	28	X
2015	M/8 mo	Pacific	Peritoneal aspirate, peritoneal tissue, peritoneal swab, skin swab	Skin	Yes	No	Yes	No	No	Yes	17	7	X
2016	F/9 mo	Pacific	Peritoneal aspirate, peritoneal swab	Skin, not swabbed	No	No	No	No	Yes	Yes	14	9	X
2016	F/2 y	Pacific	Blood, skin swab	Skin	Yes	No	No	No	No	Yes	28	23	X
2017	F/5 mo	NZ European	Blood, peritoneal aspirate, peritoneal swab	No	Yes	Yes	Yes	No	Yes	Yes	21	16	X
2019	F/2 y	Pacific	Blood, peritoneal tissue, peritoneal swab	No	No	No	No	Clindamycin	No	Yes	28	28	X
2019	M/3 y	NZ European	Peritoneal tissue	No	No	No	No	No	No	Yes	14	5	X
2019	F/13 y	NZ European	Peritoneal tissue	No	No	No	No	No	No	Yes	21	12	X
2021	M/3 y	NZ Māori	Peritoneal aspirate	No	No	No	No	No	No	Yes	21	14	114
2021	M/4 y	NZ European	Peritoneal tissue	No	No	No	No	No	No	Yes	21	9	X
2021	M/5 y	NZ European	Blood	No	No	No	No	No	No	No	21	15	114
2022	F/7 mo	Pacific	Peritoneal aspirate, peritoneal swab	No	Yes	No	No	Clindamycin	Yes	Yes	21	14	88

*GAS, group A *Streptococcus*; IVIG, intravenous immunoglobulin; LOS, length of stay; NZ, New Zealand; PICU, pediatric intensive care unit; STSS, streptococcal toxic shock syndrome.

†Case included following multidisciplinary team discussion and consensus opinion. Vaginal erythema and discharge at presentation was swabbed and culture positive for GAS. One blood culture negative. Only intraoperative peritoneal sample collected were swabs which was not suitable for molecular methods but had gram-positive cocci seen on Gram stain.