

About the Author

Dr. Duarte-Benvenuto is a veterinarian and a doctorate student at the Laboratory of Wildlife Comparative Pathology in University of São Paulo, Brazil. Her primary research interest is wildlife disease and conservation, especially of aquatic mammals.

References

1. Millán J, Di Cataldo S, Volokhov DV, Becker DJ. Worldwide occurrence of haemoplasmas in wildlife: Insights into the patterns of infection, transmission, pathology and zoonotic potential. *Transbound Emerg Dis*. 2020;68:3236–56.
2. Sykes JE, Tasker S. Hemoplasma infections. In: Sykes JE, editor. *Canine and feline infectious diseases*. St. Louis: Saunders; 2013. p. 390–398.
3. Descloux, E., Mediannikov, O., Gourinat, A.C., Colot, J., Chauvet, M., Mermoud, I. et al. Flying fox hemolytic fever, description of a new zoonosis caused by *Candidatus Mycoplasma haemohominis*. *Clin Infect Dis*. 2021;73:e1445–52. <https://doi.org/10.1093/cid/ciaa1648>
4. Pires dos Santos A, Pires dos Santos R, Biondo AW, Dora JM, Goldani LZ, Tostes de Oliveira S, et al. Hemoplasma infection in HIV-positive patient, Brazil. *Emerg Infect Dis*. 2008;14:1922–4. <https://doi.org/10.3201/eid1412.080964>
5. Sacristán I, Acuña F, Aguilar E, García S, López MJ, Cevidanes A, et al. Assessing cross-species transmission of hemoplasmas at the wild-domestic felid interface in Chile using genetic and landscape variables analysis. *Sci Rep*. 2019;9:16816. <https://doi.org/10.1038/s41598-019-53184-4>
6. Volokhov DV, Norris T, Rios C, Davidson MK, Messick JB, Gulland FM, et al. Novel Hemotrophic mycoplasma identified in naturally infected California sea lions (*Zalophus californianus*). *Vet Microbiol*. 2011;149:262–8. <https://doi.org/10.1016/j.vetmic.2010.10.026>
7. International Union for Conservation of Nature and Natural Resources. The IUCN red list of threatened species [cited 2021 Jun 18]. <https://www.iucnredlist.org>
8. da Silva VMF, Martin AR. A study of the Boto, or Amazon River Dolphin (*Inia geoffrensis*), in the Mamirauá Reserve, Brazil: operation and techniques. *Occas Pap IUCN Species Surviv Comm*. 2001;23:121–30.
9. Cabello J, Altet L, Napolitano C, Sastre N, Hidalgo E, Dávila JA, et al. Survey of infectious agents in the endangered Darwin's fox (*Lycalopex fulvipes*): high prevalence and diversity of Hemotrophic mycoplasmas. *Vet Microbiol*. 2013;167:448–54. <https://doi.org/10.1016/j.vetmic.2013.09.034>
10. Harasawa R, Orusa R, Giangaspero M. Molecular evidence for Hemotrophic mycoplasma infection in a Japanese badger (*Meles meles anakuma*) and a raccoon dog (*Nyctereutes procyonoides viverrinus*). *J Wildl Dis*. 2014;50:412–5. <https://doi.org/10.7589/2013-09-229>

Address for correspondence: Aricia Duarte-Benvenuto, Laboratório de Patologia Experimental e Comparada, 87 Prof. Dr. Orlando Marques de Paiva Ave, São Paulo 05508270, Brazil; email address: aricia.benvenuto@gmail.com

Human Thelaziosis Caused by *Thelazia callipaeda* Eyeworm, Hungary

Hajnalka Juhász, Géza Thury, Mária Szécsényi, Edit Tóth-Molnár, Katalin Burián, Zoltán Deim, Gabriella Terhes

Author affiliation: University of Szeged, Szeged, Hungary\

DOI: <https://doi.org/10.3201/eid2812.220757>

Ocular infections with *Thelazia callipaeda* eyeworms in Europe have become more common. We report a case in Hungary caused by *T. callipaeda* eyeworms in a 45-year-old woman who had no travel history abroad.

Thelazia spp. (Spirurida, Thelaziidae) are vectorborne zoonotic nematodes that can parasitize conjunctiva and surrounding structures of wild and domestic animals as well as humans (1). Before 2022, a total of 16 species of *Thelazia* had been described; 3 species, *T. callipaeda*, *T. californiensis*, and *T. gulosa*, are known to infect humans. *T. callipaeda* nematodes, commonly known as eyeworms, cause autochthonous cases in Europe (2). The earliest reported endemic infection in Europe was detected in a dog in the Piedmont region of Italy in 1989. Since then, several animal and human cases have been documented throughout Europe (Appendix Table 1, <https://wwwnc.cdc.gov/EID/article/28/12/22-0757-App1.pdf>) (1–4). In Europe, under natural conditions, the only known vector and intermediate host of *T. callipaeda* eyeworms is the lachryphagous male *Phortica variegata* fly (1,5). The biologic activity of the fly is affected by temperature (20°C–25°C) and relative humidity (50%–75%) (1,6). The most common clinical manifestations of *T. callipaeda* infections are lacrimation, foreign body sensation, itchiness, conjunctivitis, and follicular hypertrophy of the conjunctiva; the affected eye may also show severe keratitis and corneal ulceration. Treatment of this infection in humans is primarily the mechanical removal of worms, which is more difficult in their immature stages (7).

In Hungary, *T. callipaeda* infection has been described in dogs (3). We report a case of conjunctivitis in a human caused by *T. callipaeda* eyeworms. Our goal is to draw the scientific community's attention to this spillover event.

A 45-year-old woman in Hungary was referred to an ophthalmologist in September 2020; she had a foreign-body sensation and redness in her left eye for a

week. Slit-lamp examination revealed conjunctivitis. Empiric tobramycin and dexamethasone therapies were initiated. At the time of follow-up, 3 thin, creamy white live worms were removed from the conjunctival fornices of her left eye (Figure). Left eye examination revealed follicular conjunctival hypertrophy. The cornea was not affected, visual acuity was 20/20 on both eyes, and intraocular pressure was in the normal range. The patient's medical history was uneventful. Laboratory examination showed no elevated leukocytes, C-reactive protein, or erythrocyte sedimentation rate. The patient had no peripheral blood eosinophilia. Because of worsened conjunctivitis, 2% boric acid was applied for 5 days after removal of the worms. On the last follow-up visit, the patient had no symptoms.

Two worms were sent to the Department of Medical Microbiology, University of Szeged (Szeged, Hungary). We examined them under a light microscope (Leica DM 100; Leica Microsystems, <https://www.leica-microsystems.com>). Wet-mount preparation showed the presence of a characteristic vase-shaped buccal cavity (Figure, panel C) and serrated cuticula with transverse striations. The position of the vulva was anterior to the esophago-junction (8). The anterior half of the abdominal cavity contained first-stage larvae; the posterior part contained eggs. The nematodes were 15 mm and 14 mm long. We identified them as female *T. callipaeda* eyeworms on the basis of

morphologic features. We isolated total DNA from one using QIAamp DNA mini kit (QIAGEN, <https://www.qiagen.com>) in accordance with tissue protocol; we then performed an in-house PCR targeting *cox1* as described previously by Čabanová et al (9). Sequence analysis of the amplified PCR product (GenBank accession no. OP278871) showed 100% homology with *T. callipaeda* haplotype 1 strains in GenBank (Appendix Figure 1).

We describe an autochthonous case of a patient with *T. callipaeda* eyeworm ocular infection in Hungary. The patient had no travel history abroad. In July, she visited the Bükk National Park in northeastern Hungary, where she saw a lot of flies. This vector is widely distributed in southern and central Europe and exists in Hungary as well (1,10). Its lachryphagous activity depends mostly on temperature, so climatic changes affect the spread of infection toward the north, affecting new areas (1,6). Until December 2017, a total of 10 canine thelaziosis cases were identified by Farkas et al. in Hungary (3). Most of them visited the same park located in Borsod-Abaúj-Zemplén as our patient (3). That study also suggested that wild carnivores, mainly red foxes, had a role in spreading thelaziosis beyond the border (3). The emergence of human thelaziosis may be explained by the fact that the number of red foxes in Hungary has tripled during the past 50 years (Appendix Figure 2) (Appendix reference

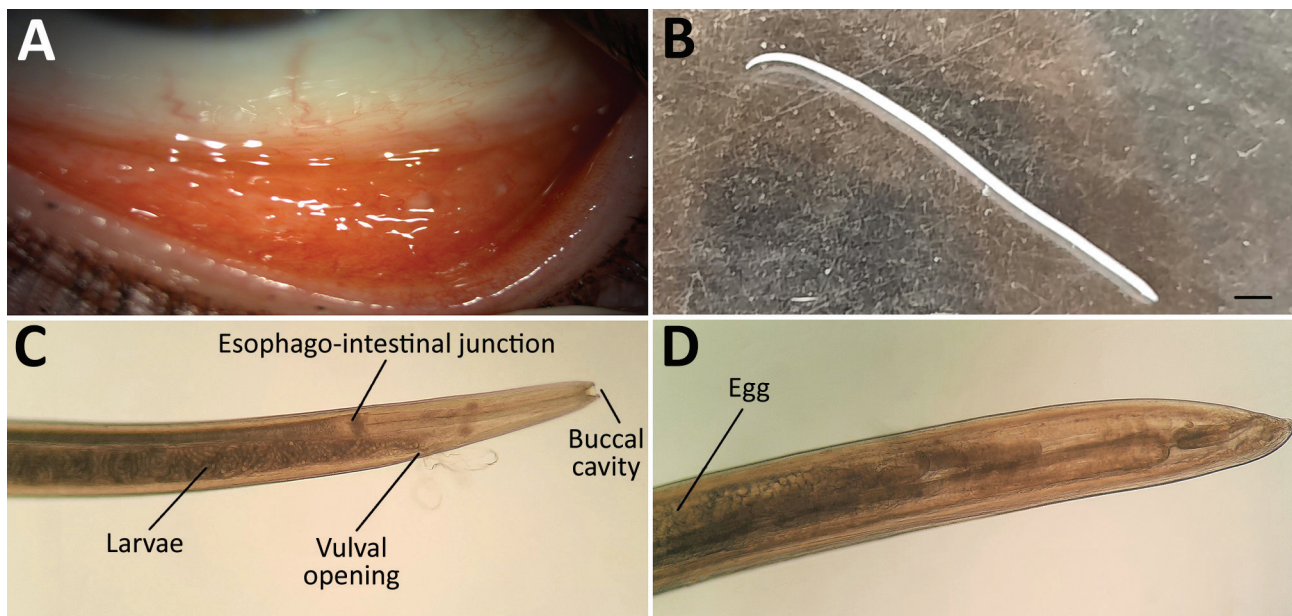


Figure. Imaging results for *Thelazia callipaeda* eyeworm infection in a woman in Hungary. A) Follicles in the inferior tarsal conjunctiva in the patient's left eye 5 days after removal of an adult female *T. callipaeda* worm. B) Female worm removed from the patient's left eye. Scale bar indicates 1 mm. C, D) Morphologic characteristics of the *T. callipaeda* worm from the patient (C) and eggs visible within the specimen (D). Original magnification $\times 100$.

11). In human case-patients, the first-choice therapy is to remove the worms mechanically by flushing the conjunctival sac with sterile physiologic saline under local anesthesia (Appendix reference 12).

From a therapeutic and epidemiologic standpoint, it is important to differentiate between infectious and allergic conjunctivitis. Furthermore, diagnosis can be difficult because immature larvae can hide in the excretory ducts of the lacrimal glands (7). Our findings indicate the need for education and raised awareness about this infection especially for ophthalmologists. Early and adequate diagnosis can help to prevent complications such as corneal ulceration.

About the Author

Ms. Juhász is a biologist specializing in clinical microbiology in the Department of Medical Microbiology, University of Szeged, Szeged, Hungary. Her primary research interests are human viral, bacterial, and parasitic infections, focusing on respiratory tract pathogens.

References

- Palfreyman J, Graham-Brown J, Caminade C, Gilmore P, Otranto D, Williams DJL. Predicting the distribution of *Phortica variegata* and potential for *Thelazia callipaeda* transmission in Europe and the United Kingdom. *Parasit Vectors*. 2018;11:272. <https://doi.org/10.1186/s13071-018-2842-4>
- do Vale B, Lopes AP, da Conceição Fontes M, Silvestre M, Cardoso L, Coelho AC. Systematic review on infection and disease caused by *Thelazia callipaeda* in Europe: 2001–2020. *Parasite*. 2020;27:52. <https://doi.org/10.1051/parasite/2020048>
- Farkas R, Takács N, Gyurkovszky M, Henszelmann N, Kisgergely J, Balka G, et al. The first feline and new canine cases of *Thelazia callipaeda* (Spirurida: Thelaziidae) infection in Hungary. *Parasit Vectors*. 2018;11:338. <https://doi.org/10.1186/s13071-018-2925-2>
- Morgado ACT, do Vale B, Ribeiro P, Coutinho T, Santos-Silva S, de Sousa Moreira A, et al. First report of human *Thelazia callipaeda* infection in Portugal. *Acta Trop*. 2022;231:106436. <https://doi.org/10.1016/j.actatropica.2022.106436>
- Rolbiecki L, Izdebska JN, Franke M, Iliszko L, Fryderyk S. The vector-borne zoonotic nematode *Thelazia callipaeda* in the eastern part of Europe, with a clinical case report in a dog in Poland. *Pathogens*. 2021;10:55. <https://doi.org/10.3390/pathogens10010055>
- Pombi M, Marino V, Jaenike J, Graham-Brown J, Bernardini I, Lia RP, et al. Temperature is a common climatic descriptor of lachryphagous activity period in *Phortica variegata* (Diptera: Drosophilidae) from multiple geographical locations. *Parasit Vectors*. 2020;13:89. <https://doi.org/10.1186/s13071-020-3955-0>
- do Vale B, Lopes AP, da Conceição Fontes M, Silvestre M, Cardoso L, Coelho AC. Thelaziosis due to *Thelazia callipaeda* in Europe in the 21st century – a review. *Vet Parasitol*. 2019; 275:108957. <https://doi.org/10.1016/j.vetpar.2019.108957>
- Otranto D, Lia RP, Buono V, Traversa D, Giangaspero A. Biology of *Thelazia callipaeda* (Spirurida, Thelaziidae) eyeworms in naturally infected definitive hosts. *Parasitology*. 2004;129:627–33. <https://doi.org/10.1017/S0031182004006018>
- Čabanová V, Kocák P, Vichová B, Miterpáková M. First autochthonous cases of canine thelaziosis in Slovakia: a new affected area in Central Europe. *Parasit Vectors*. 2017;10:179. <https://doi.org/10.1186/s13071-017-2128-2>
- Papp L. Dipterous guilds of small-sized feeding sources in forests of Hungary. *Acta Zool Acad Sci Hung*. 2002; 48:197–213.

Address for correspondence: Gabriella Terhes, Department of Medical Microbiology, University of Szeged, H-6725 Szeged, Semmelweis street 6, Szeged, Hungary; email: terhes.gabriella@med.u-szeged.hu

Severe Human Case of Zoonotic Infection with Swine-Origin Influenza A Virus, Denmark, 2021

Klara M. Andersen, Lasse S. Vestergaard, Jakob N. Nissen, Sophie J. George, Pia Ryt-Hansen, Charlotte K. Hjulsgager, Jesper S. Krog, Marianne N. Skov, Søren Alexandersen, Lars E. Larsen, Ramona Trebbien

Author affiliations: Technical University of Denmark, Kongens Lyngby, Denmark (K.M. Andersen); Statens Serum Institut, Copenhagen, Denmark (K.M. Andersen, L.S. Vestergaard, J.N. Nissen, C.K. Hjulsgager, J.S. Krog, S. Alexandersen, R. Trebbien); University of Copenhagen, Copenhagen (S.J. George, P. Ryt-Hansen, L.E. Larsen); Odense University Hospital, Odense, Denmark (M.N. Skov)

DOI: <https://doi.org/10.3201/eid2812.220935>

During routine surveillance at the National Influenza Center, Denmark, we detected a zoonotic swine influenza A virus in a patient who became severely ill. We describe the clinical picture and the genetic characterization of this variant virus, which is distinct from another variant found previously in Denmark.

Human Thelaziosis Caused by *Thelazia callipaeda* Eyeworm, Hungary

Appendix

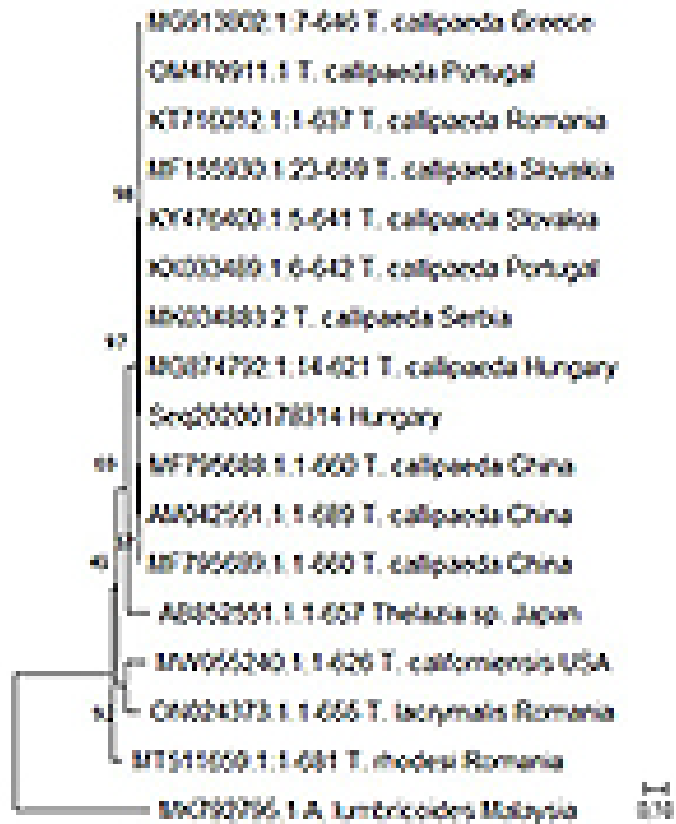Appendix References

11. Csányi S, Márton M, Major FC, Schally G. Hungarian game management database. 2020/2021 hunting year. Gödöllő, Hungary: National Wildlife Management Repository; 2021.
12. Shen J, Gasser RB, Chu D, Wang Z, Yuan X, Cantacessi C, et al. Human thelaziosis—a neglected parasitic disease of the eye. *J Parasitol.* 2006;92:872–6. [PubMed https://doi.org/10.1645/GE-823R.1](https://doi.org/10.1645/GE-823R.1)

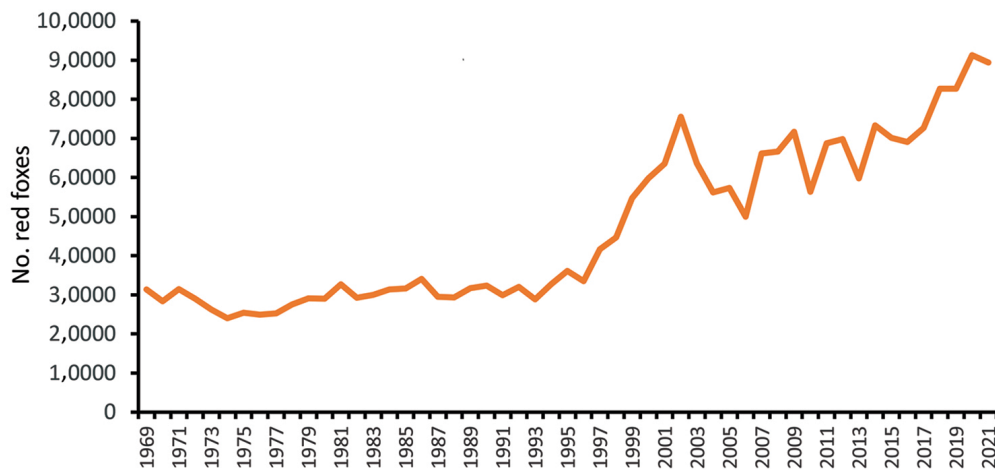
Appendix Table. Reports of animal and human cases of *Thelazia callipaeda* infection from Europe*

Country	Animal cases	Human cases
Italy	x	x
France	x	x
Switzerland	x	
Germany	x	x
Spain	x	x
Portugal	x	x
Belgium	x	
Bosnia and Herzegovina	x	
Croatia	x	x
Serbia	x	x
Romania	x	
Greece	x	
Bulgaria	x	
Slovakia	x	
United Kingdom	x	
Turkey	x	
Austria	x	
Hungary	x	
Czech Republic	x	
Moldova	x	

*Sources: Palfreyman et al. (1); do Vale et al., (2); Farkas et al. (3); Morgado et al. (4)



Appendix Figure 1. Maximum-likelihood tree shows the relationships between *cox1* sequences in the case of our isolate (Seq20200178314) and other *Thelazia* spp. retrieved from GenBank. *A. lumbricoides* is designated as an outgroup.



Appendix Figure 2. Changes in the number of red foxes (*Vulpes vulpes*) in Hungary during the last 50 years.