

About the Author

Dr. Di Micco is a general surgery resident at Spital Schwyz, Switzerland. His principal research interests are translational medicine, abdominal surgery, and prevention of surgical wound infections.

References

1. Grady EN, MacDonald J, Liu L, Richman A, Yuan ZC. Current knowledge and perspectives of *Paenibacillus*: a review. *Microb Cell Fact*. 2016;15:203. <https://doi.org/10.1186/s12934-016-0603-7>
2. Sáez-Nieto JA, Medina-Pascual MJ, Carrasco G, Garrido N, Fernandez-Torres MA, Villalón P, et al. *Paenibacillus* spp. isolated from human and environmental samples in Spain: detection of 11 new species. *New Microbes New Infect*. 2017;19:19–27. <https://doi.org/10.1016/j.nmni.2017.05.006>
3. Saffert RT, Cunningham SA, Ihde SM, Monson Jobe KE, Mandrekar J, Patel R. Comparison of Bruker Biotyper matrix-assisted laser desorption ionization-time of flight mass spectrometer to BD Phoenix automated microbiology system for identification of gram-negative bacilli. *J Clin Microbiol*. 2011;49:887–92. <https://doi.org/10.1128/JCM.01890-10>
4. Celandroni F, Salvetti S, Gueye SA, Mazzantini D, Lupetti A, Senesi S, et al. Identification and pathogenic potential of clinical bacillus and *Paenibacillus* isolates. *PLoS One*. 2016;11:e0152831. <https://doi.org/10.1371/journal.pone.0152831>
5. Noskin GA, Suriano T, Collins S, Sesler S, Peterson LR. *Paenibacillus macerans* pseudobacteremia resulting from contaminated blood culture bottles in a neonatal intensive care unit. *Am J Infect Control*. 2001;29:126–9. <https://doi.org/10.1067/mic.2001.111535>
6. Ouyang J, Pei Z, Lutwick L, Dalal S, Yang L, Cassai N, et al. Case report: *Paenibacillus thiaminolyticus*: a new cause of human infection, inducing bacteremia in a patient on hemodialysis. *Ann Clin Lab Sci*. 2008;38:393–400.
7. Szaniawski MA, Spivak AM. Recurrent *Paenibacillus* infection. *Oxf Med Case Reports*. 2019;2019:omz034.
8. Kuno Y. *Bacillus thiaminolyticus*, a new thiamin-decomposing bacterium. *Proc Jpn Acad*. 1951;27:362–5. <https://doi.org/10.2183/pjab1945.27.362>
9. Haven TR, Caldwell DR, Jensen R. Role of predominant rumen bacteria in the cause of polioencephalomalacia (cerebrocortical necrosis) in cattle. *Am J Vet Res*. 1983;44:1451–5.
10. Hehnly C, Zhang L, Paulson JN, Almeida M, von Bredow B, Wijetunge DSS, et al. Complete genome sequences of the human pathogen *Paenibacillus thiaminolyticus* Mbale and type strain *P. thiaminolyticus* NRRL B-4156. *Microbiol Resour Announc*. 2020;9:e00181–20. <https://doi.org/10.1128/MRA.00181-20>

Address for correspondence: Reto Nüesch, Department of Internal Medicine, Spital Schwyz, 10 Waldeggstrasse, 6430 Schwyz, Switzerland; email: reto.nueesch@spital-schwyz.ch

Confirmed Cases of Ophidiomycosis in Museum Specimens from as Early as 1945, United States

Jeffrey M. Lorch, Steven J. Price, Julia S. Lankton, Andrea N. Drayer

Author affiliations: US Geological Survey National Wildlife Health Center, Madison, Wisconsin, USA (J.M. Lorch, J.S. Lankton); University of Kentucky, Lexington, Kentucky, USA (S.J. Price, A.N. Drayer)

DOI: <https://doi.org/10.3201/eid2707.204864>

Ophidiomycosis represents a conservation threat to wild snake populations. The disease was reported in North America early in the 21st century, but the history of ophidiomycosis has not been investigated. We examined museum specimens and confirmed cases of ophidiomycosis >50 years before the disease's reported emergence.

Emerging fungal pathogens of wildlife are recognized as major threats to global biodiversity, causing population declines and extinction events in a variety of host species (1). *Ophidiomyces ophidiicola*, the causative agent of ophidiomycosis, is one such pathogen recognized as a conservation threat to wild snakes (2). The disease first gained attention in 2008 when fatal infections emerged in eastern massasauga rattlesnakes (*Sistrurus catenatus*) in Illinois, USA (3), and has since been documented throughout North America and Europe (2,4). The earliest retrospective detection of *O. ophidiicola* in snakes was from 2000 (5). We report the earliest known confirmed cases of ophidiomycosis in free-living snakes in the United States, dating back to 1945.

We investigated the historical occurrence of ophidiomycosis in snakes in the United States by examining specimens preserved in formalin or ethanol at the University of Wisconsin Zoological Museum (UWZM; Madison, WI, USA) and Morehead State University Museum Collection (Morehead, KY, USA). We visually examined 524 specimens representing 30 snake species from 19 states in the eastern United States collected during 1900–2012 (Appendix 1, <https://wwwnc.cdc.gov/EID/article/27/7/20-4864-App1.xlsx>). To reduce risk for cross-contamination, we first examined snakes for clinical signs of ophidiomycosis within the glass jars in which they were stored. When specimens were removed from the jars for sampling, new gloves were worn to handle

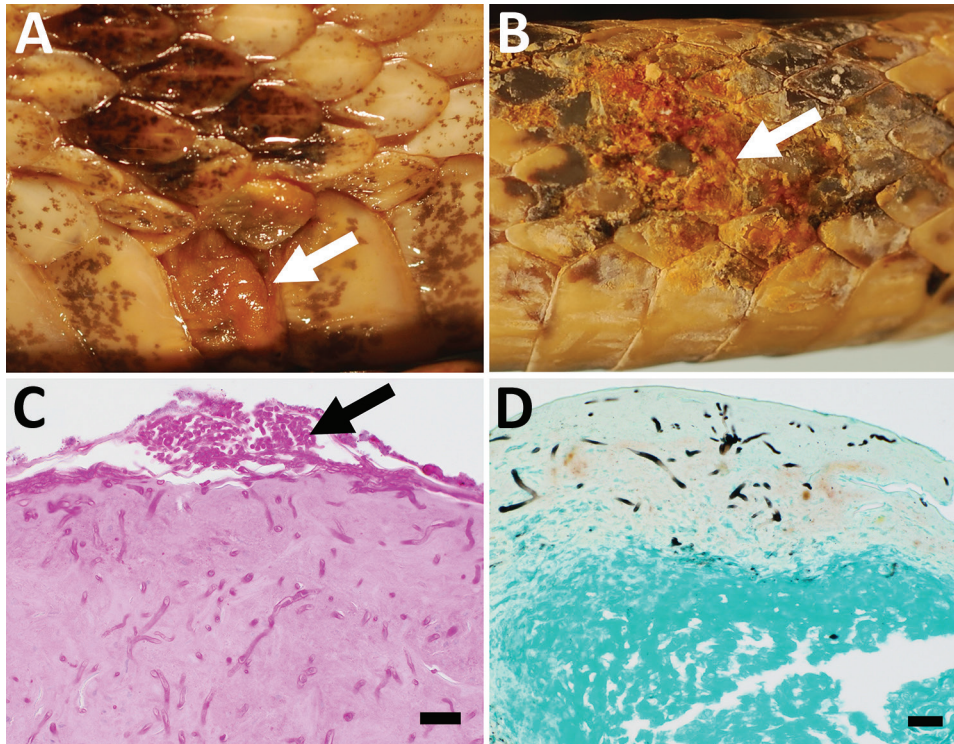


Figure. Gross and histologic lesions in museum snake specimens with confirmed ophidiomycosis, United States. A, B) *Crotalus horridus* (A; University of Wisconsin Zoology Museum [UWZH] accession no. 22773) and *Cemophora coccinea* (B; UWZH accession no. 13822) specimens with thickened necrotic scales (arrows). C, D) Histologic sections of lesioned skin from the same *C. horridus* (C; UWZH accession no. 22773) and *C. coccinea* (D; UWZH accession no. 13822) specimens showing arthroconidia (arrow) and intralesional fungal hyphae consistent with *Ophidiomyces ophidiicola* infection. Scale bars indicate 20 μ m.

each snake. We observed clinical signs consistent with ophidiomycosis (Figure) in 47 (9.0%) snakes (6). These specimens represented 12 species from 7 states with collection dates ranging from 1929 to 1983 (Appendix 1).

Clinical signs of ophidiomycosis are not pathognomonic, and a confirmed diagnosis requires compatible histopathologic lesions and the detection of *O. ophidiicola* (6). Because these confirmatory steps involve destructive sampling of museum material, we selected a subset of snakes ($n = 12$) for these analyses. We targeted specimens with large (>0.5 cm²) or

multiple skin lesions from distant geographic areas and collected ≥ 25 years before the reported 2008 emergence of ophidiomycosis (3) (Table). From selected snakes, we excised and formalin-fixed portions of lesioned skin, routinely processed them for light microscopy, and stained with periodic acid-Schiff and Grocott methenamine silver methods. We also collected small pieces of lesioned skin (≈ 4 mm²) for PCR-based detection of *O. ophidiicola*. We extracted DNA from dehydrated tissue by using the Gentra Puregene Tissue Kit (QIAGEN, <https://www.qiagen.com>); we used 10 μ L of the kit-provided proteinase K per sample.

Table. Museum snake specimens with clinical signs of ophidiomycosis that were subjected to histopathologic examination and PCR specific for *Ophidiomyces ophidiicola*, United States*

Snake species	Museum accession no.	Museum collection	State collected	Date collected	Ophidiomycosis histopathology	PCR result†	Ophidiomycosis diagnosis‡
<i>Crotalus horridus</i>	UWZH 22773	UWZM	WI	1958 Aug	Positive	Positive	Confirmed
<i>C. horridus</i>	UWZH 23927	UWZM	TN	1973 Apr 13	Positive	Negative	Apparent
<i>C. horridus</i>	UWZH 23930	UWZM	TN	1973 Apr 13	Positive	Negative	Apparent
<i>Cemophora coccinea</i>	UWZH 13833	UWZM	FL	1945	Positive	Positive	Confirmed
<i>Lampropeltis triangulum</i>	UWZH 22583	UWZM	WI	1982 Apr 25	Positive	Negative	Apparent
<i>Pantherophis spiloides</i>	UWZH 23931	UWZM	TN	1973 Apr 13	Positive	Positive	Confirmed
<i>Agkistrodon contortrix</i>	582	MSUMC	KY	1979 Oct 29	Equivocal§	Negative	Possible
<i>Coluber constrictor</i>	603	MSUMC	KY	1980 May 6	Positive	Negative	Apparent
<i>C. constrictor</i>	632	MSUMC	KY	1980 May 16	Negative	Negative	Possible
<i>Regina septemvittata</i>	496	MSUMC	KY	1979 May 30	Equivocal	Negative	Possible
<i>R. septemvittata</i>	511	MSUMC	KY	1979 Jun 2	Equivocal	Negative	Possible
<i>R. septemvittata</i>	634	MSUMC	KY	1980 May 18	Equivocal	Negative	Possible

*MSUMC, Morehead State University Museum Collection; Oo, *Ophidiomyces ophidiicola*; UWZM, University of Wisconsin Zoology Museum.

†Samples are listed as positive if ≥ 1 PCR assay targeting the internal transcribed spacer region or mitochondrial NADH dehydrogenase subunit 1 gene was positive. See Appendix 1 (<https://wwwnc.cdc.gov/EID/article/27/7/20-4864-App1.xlsx>) for assay-specific results.

‡Based on Baker et al. (6).

§Equivocal indicates some histologic features consistent with ophidiomycosis were present but ≥ 1 diagnostic features were not observed (Appendix 1).

Negative controls consisted of blank extractions. For PCR, we used existing primers that specifically target the internal transcribed spacer region (ITS) of *O. ophidiicola* (6) and a newly designed PCR assay that targets mitochondrial NADH dehydrogenase subunit 1 (*nad1*) (Appendix 2, <https://wwwnc.cdc.gov/EID/article/27/7/20-4864-App2.pdf>). We targeted these 2 loci, which exist at high copy numbers in the genome, because amplifiable DNA was expected to be at low abundance in the preserved specimens. We cloned and sequenced PCR amplicons of the appropriate size to confirm the presence of *O. ophidiicola*. We conducted tissue collection, DNA extraction, and PCR under strict protocols (e.g., unidirectional workflow and regular decontamination of work surfaces and equipment) to prevent contamination of samples.

Of the 12 snakes subjected to histopathological analyses, 7 (58.3%) had microscopic lesions with intralesional fungi consistent with ophidiomycosis (6) (Table; Figure). We detected DNA from *O. ophidiicola* in 3 (50%) of the 6 specimens from UWZM that had been stored in 70% ethanol (Table). We did not detect DNA of *O. ophidiicola* in snakes from the Morehead State University Museum Collection (n = 6), likely because these specimens were stored long-term in formalin, which is known to affect the recovery of amplifiable nucleic acid. These results highlight the importance of targeting specimens stored in ethanol rather than formalin for molecular-based detection of pathogens in archival material.

We amplified the ITS target from 2 of the 3 specimens and *nad1* target from all 3 specimens; these sequences were 100% identical to existing *O. ophidiicola* sequences in GenBank. The 3 additional specimens from UWZM were strongly suspected to represent cases of ophidiomycosis on the basis of the presence of arthroconidia in histologic sections of lesioned skin (6); however, fungal DNA from these specimens may not have been suitable for PCR amplification. Negative controls performed as expected. The 3 PCR-positive specimens met the diagnostic criteria for confirmed cases of ophidiomycosis (6); they were collected in Florida in 1945, Wisconsin in 1958, and Tennessee in 1973 (Table). These cases predate the earliest previously known detection of *O. ophidiicola* in free-living snakes in North America by as much as 55 years (5).

Museum specimens can provide crucial insights into the history of emerging infectious diseases. Preserved animal specimens have been used to trace the origin and spread of other fungal pathogens, such as *Pseudogymnoascus destructans* (white-nose syndrome in bats) and *Batrachochytrium* spp. (chytridiomycosis

in amphibians) (8–10). By using a similar approach, we demonstrate that ophidiomycosis was circulating in the eastern United States for decades before its recognition as an emerging disease. Future work focusing on how such factors as climate change, environmental disturbance, and underlying health of snake populations influence ophidiomycosis dynamics might reveal the mechanism by which ophidiomycosis is emerging (2).

Acknowledgments

We thank the University of Wisconsin Zoological Museum and Morehead State University Museum Collection for allowing us to examine and destructively sample specimens.

This work was funded by the US Geological Survey and McIntire-Stennis Cooperative Forestry Research Program (#1014910).

Data for this study are available at <https://doi.org/10.5066/P9FLC1XK>.

About the Author

Dr. Lorch is a diagnostic microbiologist and research scientist at the US Geological Survey National Wildlife Health Center, Madison, Wisconsin. His research focuses on emerging infectious diseases of wildlife and the development of molecular tools for use in wildlife disease diagnostics.

References

1. Fisher MC, Henk DA, Briggs CJ, Brownstein JS, Madoff LC, McCraw SL, et al. Emerging fungal threats to animal, plant and ecosystem health. *Nature*. 2012;484:186–94. <https://doi.org/10.1038/nature10947>
2. Lorch JM, Knowles S, Lankton JS, Michell K, Edwards JL, Kapfer JM, et al. Snake fungal disease: an emerging threat to wild snakes. *Philos Trans R Soc Lond B Biol Sci*. 2016;371(1709):20150457.
3. Allender MC, Dreslik M, Wylie S, Phillips C, Wylie DB, Maddox C, et al. *Chrysosporium* sp. infection in eastern massasauga rattlesnakes. *Emerg Infect Dis*. 2011;17:2383–4. <https://doi.org/10.3201/eid1712.110240>
4. Franklinos LHV, Lorch JM, Bohuski E, Rodriguez-Ramos Fernandez J, Wright ON, Fitzpatrick L, et al. Emerging fungal pathogen *Ophidiomyces ophidiicola* in wild European snakes. *Sci Rep*. 2017;7:3844. <https://doi.org/10.1038/s41598-017-03352-1>
5. Allender MC, Phillips CA, Baker SJ, Wylie DB, Narotsky A, Dreslik MJ. Hematology in an eastern massasauga (*Sistrurus catenatus*) population and the emergence of *Ophidiomyces* in Illinois, USA. *J Wildl Dis*. 2016;52:258–69. <https://doi.org/10.7589/2015-02-049>
6. Baker SJ, Haynes E, Gramhofer M, Stanford K, Bailey S, Christman M, et al. Case definition and diagnostic testing for snake fungal disease. *Herpetol Rev*. 2019;50:279–85.
7. Bohuski E, Lorch JM, Griffin KM, Blehert DS. TaqMan real-time polymerase chain reaction for detection of *Ophidiomyces*

- ophiodiicola*, the fungus associated with snake fungal disease. *BMC Vet Res.* 2015;11:95. <https://doi.org/10.1186/s12917-015-0407-8>
8. Martel A, Blooi M, Adriaensen C, Van Rooij P, Beukema W, Fisher MC, et al. Wildlife disease. Recent introduction of a chytrid fungus endangers Western Palearctic salamanders. *Science.* 2014;346:630–1. <https://doi.org/10.1126/science.1258268>
 9. Burrowes PA, De la Riva I. Unraveling the historical prevalence of the invasive chytrid fungus in the Bolivian Andes: implications in recent amphibian declines. *Biol Invasions.* 2017;19:1781–94. <https://doi.org/10.1007/s10530-017-1390-8>
 10. Campana MG, Kurata NP, Foster JT, Helgen LE, Reeder DM, Fleischer RC, et al. White-Nose Syndrome Fungus in a 1918 bat specimen from France. *Emerg Infect Dis.* 2017;23:1611–2. <https://doi.org/10.3201/eid2309.170875>

Address for correspondence: Jeffrey M. Lorch, US Geological Survey National Wildlife Health Center, 6006 Schroeder Rd, Madison, WI 53711, USA; email: jlorch@usgs.gov

Buffalopox Disease in Livestock and Milkers, India

Parimal Roy, Andrew Chandramohan

Author affiliation: Tamil Nadu Veterinary and Animal Sciences University, Chennai, India

DOI: <https://doi.org/10.3201/eid2707.202111>

Buffalopox outbreaks caused by vaccinia virus were observed in villages of Tamil Nadu, India, among lactating buffaloes and cows. Milkers also had lesions on their fingers. Because vaccinia virus is known to have extended its host range in Brazil, we recommend continuous surveillance to understand cross-species transmission and to curtail disease effects.

In India, sporadic outbreaks of buffalopox, which can be caused by vaccinia virus (VACV), have been reported among cattle and buffaloes (1–3) and also in humans (3). We describe an outbreak affecting 120 lactating buffaloes and 40 lactating cows in Kannivadi, Navapatti, Alathuranpatti, Maniakaranpatti, Muthukumarapatti, S.Pudur, and E.Chittor,

Dindigul district; and in Krishnarayapuram, Karur district, in Tamil Nadu, India in 2004. Pock lesions (0.5–1 cm diameter) were seen over the bodies of lactating buffaloes but restricted to only the udder and teats of lactating cows (Figure, panel A). Buffalopox did not cause death in the animals we reviewed; it affected more buffaloes (30%–50%) than cows (20%–30%). Suckling calves developed pock lesions on the forehead, lips, and mouth. Three milkers who worked with the affected animals experienced multiple pock lesions (1 cm diameter) on the fingers, interdigital webs, wrist and forearm (Figure, panel B) and generalized effects including fever (100°F) and enlargement of axillary lymph nodes.

To investigate the causative agent, we used existing clinical samples. Scab samples were collected randomly from 20 affected animals (both buffaloes and cows). We examined scab suspensions under transmission electron microscope (EM) at 80 KV and inoculated the suspension in BHK21 cell line for virus isolation. We examined scab homogenates and cell culture fluid by PCR for differential diagnosis of cowpox virus and VACV infection (4). EM revealed typical brick-shaped pox virus particles of $\approx 290 \times 270$ nm with irregularly arranged superficial filaments formed by tubules (Figure, panel C). After 2 blind passages, we noticed in BHK21 cell lines cytopathogenic effects such as cellular rounding, cellular fusion, and intracytoplasmic inclusion bodies (Figure, panel D) after 48–60 hours of infection; PCR analysis revealed the causative agent to be VACV.

During the global eradication of smallpox, strains of VACV were used as vaccine. VACV infection sometimes transmitted from the vascular lesion of vaccinae to domestic animals, usually cattle; in turn, infected animals transmitted VACV to susceptible humans (5). Several outbreaks in cattle and humans that were thought to be cowpox were in fact caused by VACV (1,6,7). The infected animals were treated with parenteral injection of antimicrobial drugs for 1 week to control secondary bacterial infection and an antiinflammatory drug for 3 days to reduce pain and inflammation. Animal workers were also advised to clean the animals' lesions with 1% potassium permanganate solution followed by tropical application over the pock lesions with indigenous product of neem leaf extract and turmeric powder suspended in glycerin. Individual animals recovered in ≈ 1 month. Similarly affected humans were diagnosed at primary healthcare centers and treated with oral antimicrobial drugs and analgesics for 1 week, which reduced pain and pustules. Healing was complete in 3 weeks' time.

Confirmed Cases of Ophidiomycosis in Museum Specimens from as Early as 1945, United States

Appendix 2

PCR-Based Detection of *Ophidiomyces ophidiicola* in Museum Specimens

An 82-nt portion of the internal transcribed spacer region of *Ophidiomyces ophidiicola* (*Oo*) was targeted for amplification by using the previously described (*I*) primers Oo-rt-ITS-F (5' – GAGTGTATGGGAATCTGTTTC – 3') and Oo-rt-ITS-R (5' – GGTCAAACCGGAAAGAATG – 3') under the following cycling conditions: 94°C for 5 minutes; 48 cycles of 94°C for 30 seconds, 58.8°C for 30 seconds, 68°C for 30 seconds; and a final extension at 68°C for 5 minutes.

Formalin fixation of tissues is known to reduce or eliminate amplifiable nucleic acids, and successful amplification is dependent on the target sequence being intact. For this reason, we designed a second PCR assay that targeted a small fragment of the NADH dehydrogenase subunit 1 (*nad1*) present on the mitochondrial genome of *Oo*. Because a large quantity of mitochondria can be present within a single fungal cell, *nad1* potentially exists at a higher copy number than the internal transcribed spacer region and therefore may be more likely to amplify in samples for which little amplifiable DNA remains. Primers Oo-*nad1*-F (5' – ACTTGATTGTTTCTCTAGTC – 3') and Oo-*nad1*-R (5' – AGGGAAAGAAGCTCTAAC – 3') were designed to amplify an 85-nt portion of *nad1* that exhibits a high degree of interspecific variability for ascomycete fungi. Cycling conditions for the PCR were as follows: 94°C for 5 min; 48 cycles of 94°C for 30 sec, 50°C for 30 sec, 68°C for 30 sec; and a final extension at 68°C for 5 min. In a screening test, the assay was shown to amplify the *nad1* region of three *Oo* isolates tested: strains UAMH 10296 (UAMH Centre for Global Microfungal Biodiversity Culture Collection), ATCC MYA-4974 (American Type Culture Collection), NWHC 23913–1 (US Geological Survey National Wildlife Health Center Culture Collection); GenBank accession

numbers MW358097-MW358099. However, the assay did not amplify DNA from 19 closely related fungi in the order Onygenales (*Arthroderma quadrifidum* strain UAMH 2941, *Chrysosporium indicum* strain UAMH 10212, *Nannizziopsis arthrosporoides* strain CBS 133988 [Centraalbureau voor Schimmelcultures], *N. chlamydospora* strain CBS 133985, *N. crocodili* strain UAMH 9666, *N. dermatitidis* strain UAMH 7583, *N. draconii* strain CBS 133987, *N. guarroi* strain CBS 124553, *N. hominis* strain UAMH 7859, *N. infrequens* strain UAMH 10417, *N. obscura* strain UAMH 5875, *N. pluriseptata* strain CBS 133989, *N. vriesii* strain UAMH 3527, *Paranannizziopsis californiense* strain UAMH 10693, *Paranannizziopsis crustacea* strain UAMH 10199, *Paranannizziopsis longisporum* strain CBS 133990, *Pseudoamauroascus australiensis* strain UAMH 8392, *Trichophyton terrestre* strain UAMH 657, and *Uncinocarpus reesii* strain UAMH 3880) or other fungi commonly found on the skin of snakes (2; *Purpureocillium lilacinum* strain NWHC24022–1, *Bionectria* sp. strains NWHC26452–1 and NWHC26464–4), indicating that the assay was specific to *Oo*.

References

1. Bohuski E, Lorch JM, Griffin KM, Blehert DS. TaqMan real-time polymerase chain reaction for detection of *Ophidiomyces ophiodiicola*, the fungus associated with snake fungal disease. BMC Vet Res. 2015;11:95. [PubMed https://doi.org/10.1186/s12917-015-0407-8](https://doi.org/10.1186/s12917-015-0407-8)