

samples from the local community were positive for SFG, and 4.3% (1/23) were positive for TG (Appendix Table 1), indicating a high seroprevalence of SFG and co-circulation of TG in the region.

Because of the treating physicians' unawareness of the prevalence of rickettsioses, the patient's illness was misdiagnosed and incorrectly treated. In light of the fatal cases of *R. sibirica* subsp. *sibirica* infection recently documented in Russia and China (8–10), our report highlights the risk for rickettsial diseases among the public in the Qinghai–Tibet Plateau region and the urgent need for a large-scale seroepidemiologic survey.

Acknowledgments

We thank Pierre Rivaller for analyzing the metagenomic sequences and reviewing this manuscript.

This study was supported by the National Science and Technology Major Projects on Infectious Disease Control and prevention (grant no. 2018ZX10714-002) and Development of Capacity for Pathogen Detection (grant no. 13103110200015003) from the National Institute for Communicable Disease Control and Prevention at the China Centers for Disease Control and Prevention.

About the Author

Dr. Teng is a research associate at the National Institute for Communicable Disease Control and Prevention, China Centers for Disease Control and Prevention. His research interests include the detection and isolation of rickettsia and the epidemiology of rickettsioses.

References

1. Merhej V, Angelakis E, Socolovschi C, Raoult D. Genotyping, evolution and epidemiological findings of *Rickettsia* species. *Infect Genet Evol.* 2014;25:122–37.
2. Fang LQ, Liu K, Li XL, Liang S, Yang Y, Yao HW, et al. Emerging tick-borne infections in mainland China: an increasing public health threat. *Lancet Infect Dis.* 2015; 15:1467–79. [https://doi.org/10.1016/S1473-3099\(15\)00177-2](https://doi.org/10.1016/S1473-3099(15)00177-2)
3. Li J, Hu W, Wu T, Li HB, Hu W, Sun Y, et al. Japanese spotted fever in eastern China, 2013. *Emerg Infect Dis.* 2018;24:2107–9. <https://doi.org/10.3201/eid2411.170264>
4. Abdad MY, Abou Abdallah R, Fournier PE, Stenos J, Vasoo S. A concise review of the epidemiology and diagnostics of rickettsioses: *Rickettsia* and *Orientia* spp. *J Clin Microbiol.* 2018;56:e01728-17. <https://doi.org/10.1128/JCM.01728-17>
5. Han R, Yang J, Niu Q, Liu Z, Chen Z, Kan W, et al. Molecular prevalence of spotted fever group rickettsiae in ticks from Qinghai Province, northwestern China. *Infection, genetics and evolution: journal of molecular epidemiology and evolutionary genetics in infectious diseases.* *Infect Genet Evol.* 2018;57:1–7.
6. Ying L, Zeng-kui L, Gang C, Ming K, Dao-xin L, Yan-ming Z. Identification and phylogenetic analysis of spotted fever group *Rickettsia* isolated from Qinghai province [in Chinese]. *Chin J Vet Sci.* 2014;34:1956–61.
7. Jian Y, Li J, Adjou Moumouni PF, Zhang X, Tumwebaze MA, Wang G, et al. Human spotted fever group *Rickettsia* infecting Yaks (*Bos grunniens*) in the Qinghai-Tibetan Plateau area. *Pathogens.* 2020;9:E249. <https://doi.org/10.3390/pathogens9040249>
8. Li H, Fu XY, Jiang JF, Liu RX, Li R, Zheng YC, et al. Severe illness caused by *Rickettsia sibirica* subspecies *sibirica* BJ-90 infection, China. *Emerg Microbes Infect.* 2017;6:e107. <https://doi.org/10.1038/emi.2017.95>
9. Rudakov N, Samoylenko I, Shtrek S, Igolkina Y, Rar V, Zhirakovskaia E, et al. A fatal case of tick-borne rickettsiosis caused by mixed *Rickettsia sibirica* subsp. *sibirica* and “*Candidatus Rickettsia tarasevichiae*” infection in Russia. *Ticks Tick Borne Dis.* 2019;10:101278. <https://doi.org/10.1016/j.ttbdis.2019.101278>
10. Jia N, Jiang JF, Huo QB, Jiang BG, Cao WC. *Rickettsia sibirica* subspecies *sibirica* BJ-90 as a cause of human disease. *N Engl J Med.* 2013;369:1176–8. <https://doi.org/10.1056/NEJMc1303625>

Address for correspondence: Aiping Qin, State Key Laboratory of Infectious Diseases Prevention and Control, National Institute for Communicable Disease Control and Prevention, Chinese Center for Disease Control and Prevention, 155 Changbai Rd, Changping, Beijing 102206, China; email: qinaiping@icdc.cn

Eosinophilic Meningitis and Intraocular Infection Caused by *Dirofilaria* sp. Genotype Hongkong

Aruna S. Jyotsna, Kollencheri Puthenveetil Vinayan, Lalitha Biswas, Sujithra Haridas, Arun G. Roy, Paramal Suresh, Anil Kumar

Author affiliation: Amrita Institute of Medical Sciences, Amrita Viswa Vidyapeetham Cochin, India

DOI: <https://doi.org/10.3201/eid2705.203599>

Eosinophilic meningitis caused by human dirofilial infection is rare. We report a case of eosinophilic meningitis and concomitant intraocular dirofilial infection in India. Sequencing of the mitochondrial genome identified the worm as *Dirofilaria* sp. genotype Hongkong, a close relative of *D. repens* nematodes.

Dirofilariasis is a group of mosquito-borne parasitoses. The most prevalent *Dirofilaria* species causing infection are *D. immitis* and *D. repens* nematodes (1). Dogs are the definitive hosts in the life cycle, in which microfilaremia is observed. Humans are aberrant hosts, and the worms usually remain infertile (1,2). Human dirofilariasis is reported mostly as 1 worm in the subconjunctival or subcutaneous spaces. Surgical extraction of the worm constitutes definitive therapy. These worms are rarely observed inside the eye (1,2). Identification of the worm by using morphologic features is difficult because a large number of *Dirofilaria* species have similar features.

Diagnosis of eosinophilic meningitis is based mainly on clinical features and microscopic identification of eosinophils in the central nervous system. Helminthic infections, such as angiostrongylosis, baylisascariasis, and gnathostomiasis, are most commonly implicated in eosinophilic meningitis (3). We report a rare case of eosinophilic meningitis and concomitant intraocular dirofilarial infection. Sequencing of the mitochondrial genome of the extracted worm identified it as *Dirofilaria* sp. genotype Hongkong, a close relative of *D. repens* (4).

A 17-year-old woman came to our institute in Kochi, India, because of acute onset of severe headache, irritability, visual blurring, and diplopia, after 3 weeks of intermittent fever. She had meningeal signs, bilateral lateral rectus palsy, and papilledema. Peripheral eosinophilia (14.2%) was observed. Magnetic resonance imaging of the brain (Appendix Figure 1, <https://wwwnc.cdc.gov/EID/article/27/5/20-3599-App1.pdf>) showed diffuse leptomeningeal enhancement. Cerebrospinal fluid showed lymphocytic pleocytosis (1,040 cells/ μ L), major eosinophilia (37%), and protein and glucose levels within reference ranges.

A live worm was detected in the anterior chamber of her left eye (Figure, panel A), confirmed by slit lamp examination (Figure, panel B; Video, <https://wwwnc.cdc.gov/EID/article/27/5/20-3599-V1.htm>). The lens showed cataractous changes. Indirect ophthalmoscopy showed inflammatory changes in retinal pigment epithelium, suggestive of a migratory tract. Serologic analysis for helminthic antibodies was not conducted because serologic testing was not available. A white, thread-like worm (length \approx 15 mm) was extracted after the worm was paralyzed by injection of lignocaine into the anterior chamber of the eye (Figure, panel C).

Because a PCR was available, histopathologic analysis was not conducted. Morphologic features or sex could not be determined. The worm specimen was subjected to multiplex PCR for *D. repens* and *D. immitis* using an equimolar combination of general and species-specific primers: *Diro_12S_F* (5'-GTTCCAGAATAATCGGCTA-3'), *Diro_12S_R* (5'-ATTGACGGATGGTTTGTACC-3'), *D. immitis_F* (5'-TTTTTACTTTTTTGGTAATG-3'), and *D. repens_R* (5'-AAAAGCAACACAAATAAAA-3'). The cytochrome c oxidase subunit 1 (COX1) region was amplified by using primers *Fil_COX1F* (5'-GCTTTTCTTTTTGGKTTACTTTT-3') and *Fil_COX1R* (5'-TAGTRTCATAAAAAGAAGTATTA-3') (5).

Although the specimen was identified as a *D. repens* worm, Sanger sequencing of the COX1 and 12S rDNA PCR products was performed by using the Big-Dye Terminator v3.1 Cycle Sequencing Kit (Applied Biosystems, <https://www.thermofisher.com>) and the Genetic Analyzer 3130XL (Applied Biosystems). Sequences of 12S rRNA and COX1 genes obtained were deposited in GenBank (accession nos. MT984272 and MT984209).

Phylogenetic analysis of the 12S rRNA (MT984272) and COX1 (MT984209) sequences obtained from the

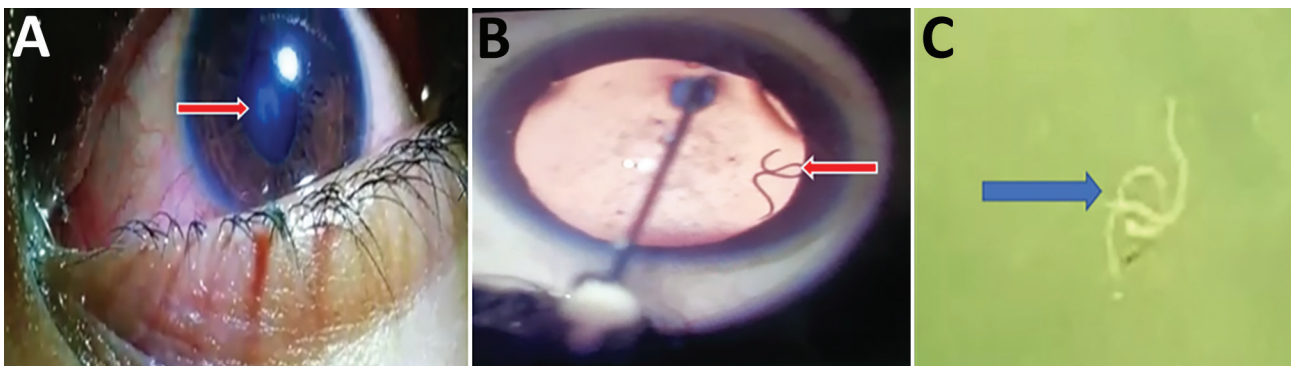


Figure. Eosinophilic meningitis and intraocular infection caused by *Dirofilaria* sp. genotype Hongkong in a patient in Kochi, India. A) Organism (arrow) in the left eye of patient during routine clinical examination. The organism caused an abnormal shape of the pupil. B) Live worm (arrow) in anterior chamber of the left eye. This image was obtained while lignocaine was being injected. C) Gross specimen of the worm (arrow) after extraction. Worm is in saline in a Petri dish.

isolate was performed by using the maximum-likelihood method with 1,000 bootstrap replications and MEGA X version 7 (<https://www.megasoftware.net>). Both the 12S rRNA and the COX1 sequences obtained from the human isolate were in the same cluster with *Dirofilaria* sp. genotype Hongkong and were separated from other *Dirofilaria* species (5,6) (Appendix Figure 2). Peripheral blood smears were negative for microfilaria. Symptoms of the patient resolved slowly after worm extraction and initiation of treatment with steroids.

Migrating worms in humans might cause a variety of clinical problems, which could be caused by mechanical effects or immune responses. Intraocular parasites might induce severe damage to various structures in the eye. Literature on eosinophilic meningitis and concomitant ocular parasites is limited. Clinical manifestations of eosinophilic meningitis are usually attributed to the severe inflammatory response incited by migrating worms, even though they are rarely demonstrated in vivo. Eosinophilic meningitis caused by *Angiostrongylus cantonensis* worms has been frequently reported in the Asia-Pacific region (7). *Dirofilaria* infection rarely results in eosinophilic meningitis (1,2).

Poppert et al. reported a case of *D. repens* infection, which was subsequently identified as *Dirofilaria* sp. genotype Hongkong, which caused subcutaneous infection and concomitant eosinophilic meningoencephalitis in a traveler returning from Kerala, India, and Sri Lanka to Germany (8). Subconjunctival infection with *Dirofilaria* sp. genotype Hongkong has also been reported in a patient returning to Austria after a 7-week stay in India (9). A recent study from Kerala, India, suggested that most of *D. repens* infections reported from southern India have the *Dirofilaria* sp. Hongkong genotype (10).

Demonstration of a live, intraocular worm and its subsequent identification as *Dirofilaria* sp. genotype Hongkong by using sequencing added a new dimension to this case of eosinophilic meningitis. Infection with the *Dirofilaria* sp. Hongkong genotype, blood eosinophilia, and eosinophilic meningitis are the 3 strikingly similar features between our case-patient and Poppert et al. (8), suggesting that *Dirofilaria* sp. genotype Hongkong might induce a more systemic eosinophilic reaction than *D. repens*.

Sequencing using panfilarial primers might help characterize most filarial species. Such an approach might clarify the etiopathogenesis of eosinophilic meningitis, leading to newer therapeutic and preventive strategies.

About the Author

Dr. Jyotsna is a resident in pediatric neurology at Amrita Institute of Medical Sciences and Research Centre, Kochi, Kerala, India. Her primary research interest is neurologic manifestations of infectious diseases.

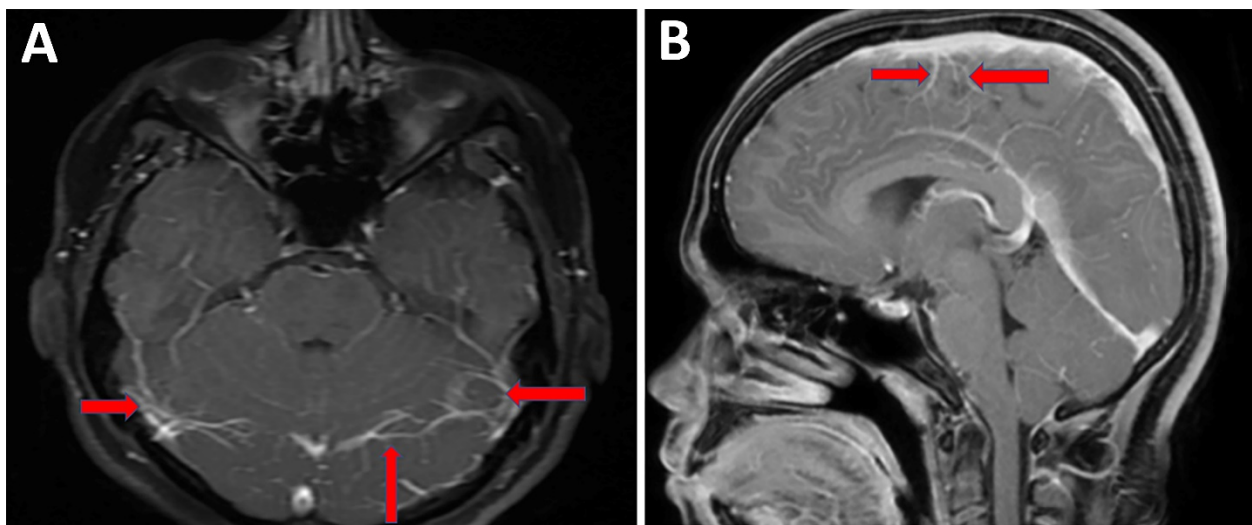
References

1. Genchi C, Rinaldi L, Mortarino M, Genchi M, Cringoli G. Climate and *Dirofilaria* infection in Europe. *Vet Parasitol.* 2009;163:286–92. <https://doi.org/10.1016/j.vetpar.2009.03.026>
2. Simón F, Siles-Lucas M, Morchón R, González-Miguel J, Mellado I, Carretón E, et al. Human and animal dirofilariasis: the emergence of a zoonotic mosaic. *Clin Microbiol Rev.* 2012;25:507–44. <https://doi.org/10.1128/CMR.00012-12>
3. Graeff-Teixeira C, da Silva AC, Yoshimura K. Update on eosinophilic meningoencephalitis and its clinical relevance. *Clin Microbiol Rev.* 2009;22:322–48. <https://doi.org/10.1128/CMR.00044-08>
4. To KK, Wong SS, Poon RW, Trendell-Smith NJ, Ngan AH, Lam JW, et al. A novel *Dirofilaria* species causing human and canine infections in Hong Kong. *J Clin Microbiol.* 2012;50:3534–41. <https://doi.org/10.1128/JCM.01590-12>
5. Gioia G, Lecová L, Genchi M, Ferri E, Genchi C, Mortarino M. Highly sensitive multiplex PCR for simultaneous detection and discrimination of *Dirofilaria immitis* and *Dirofilaria repens* in canine peripheral blood. *Vet Parasitol.* 2010;172:160–3. <https://doi.org/10.1016/j.vetpar.2010.04.027>
6. To KK, Wong SS, Poon RW, Trendell-Smith NJ, Ngan AH, Lam JW, et al. A novel *Dirofilaria* species causing human and canine infections in Hong Kong. *J Clin Microbiol.* 2012;50:3534–41. <https://doi.org/10.1128/JCM.01590-12>
7. Wang QP, Wu ZD, Wei J, Owen RL, Lun ZR. Human *Angiostrongylus cantonensis*: an update. *Eur J Clin Microbiol Infect Dis.* 2012;31:389–95. <https://doi.org/10.1007/s10096-011-1328-5>
8. Poppert S, Hodapp M, Krueger A, Hegasy G, Niesen WD, Kern WV, et al. *Dirofilaria repens* infection and concomitant meningoencephalitis. *Emerg Infect Dis.* 2009;15:1844–6. <https://doi.org/10.3201/eid1511.090936>
9. Winkler S, Pollreisz A, Georgopoulos M, Bagò-Horvath Z, Auer H, To KK, et al. *Candidatus* *Dirofilaria hongkongensis* as causative agent of human ocular filariasis after travel to India. *Emerg Infect Dis.* 2017;23:1428–31. <https://doi.org/10.3201/eid2308.170423>
10. Pradeep RK, Nimisha M, Pakideery V, Johns J, Chandy G, Nair S, et al. Whether *Dirofilaria repens* parasites from south India belong to zoonotic *Candidatus* *Dirofilaria hongkongensis* (*Dirofilaria* sp. *hongkongensis*)? *Infect Genet Evol.* 2019;67:121–5. <https://doi.org/10.1016/j.meegid.2018.10.019>

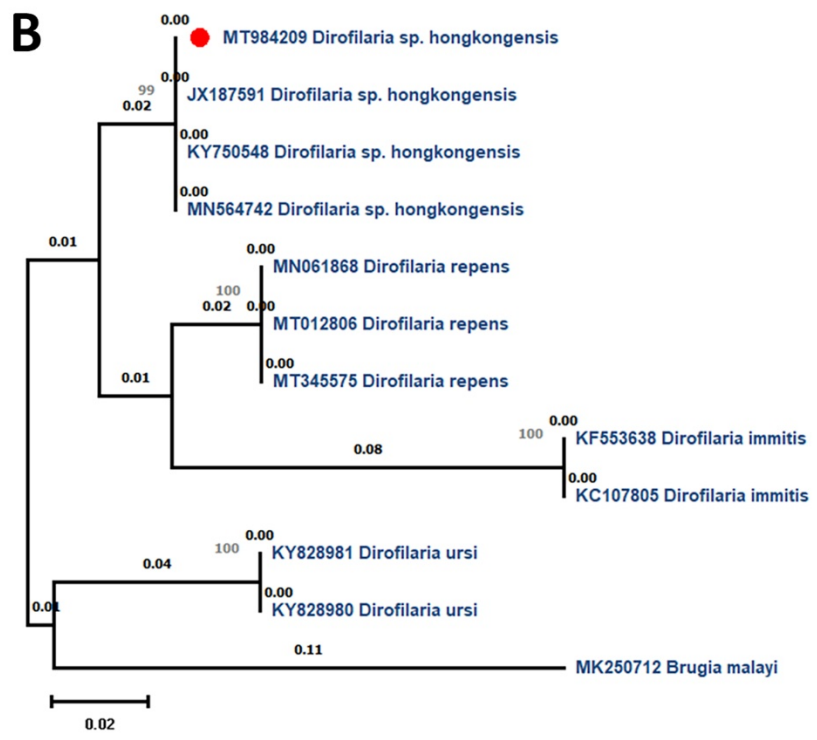
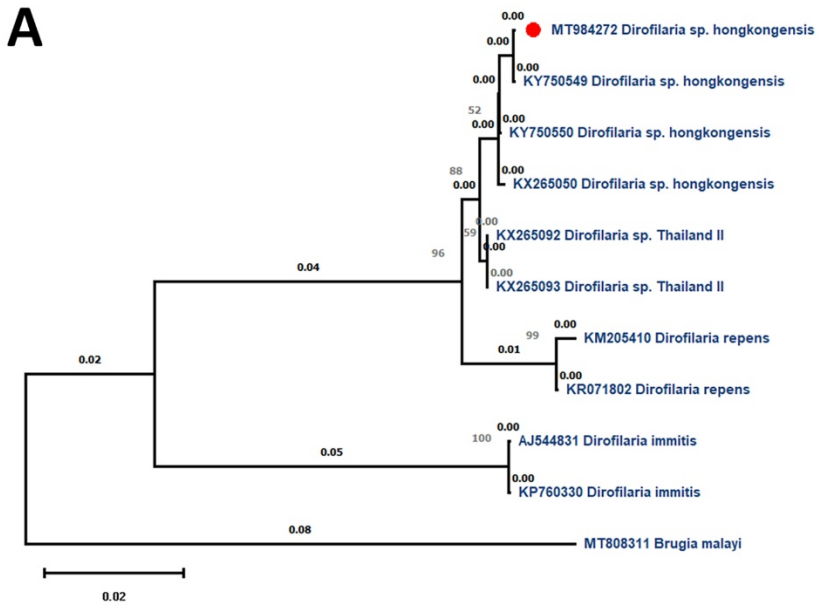
Address for correspondence: Kollencheri P. Vinayan, Department of Pediatric Neurology, Amrita Institute of Medical Sciences and Research Centre, Ponnekkara, Edapally, Kochi 682041 India; email: vinayankp@aims.amrita.edu

Eosinophilic Meningitis and Intraocular Infection Caused by *Dirofilaria* sp. Genotype Hongkong

Appendix



Appendix Figure 1. Magnetic resonance imaging of brain of patient infected with *Dirofilaria* sp. genotype Hongkong. A) Post contrast, axial T1 image and B) sagittal image show diffuse leptomeningeal enhancement.



Appendix Figure 2. Phylogenetic analysis of *Dirofilaria* sp. genotype Hongkong worm isolated from the patient. A) 12S rRNA gene sequences of the *Dirofilaria* species. *Dirofilaria* sp. genotype Hongkong. B) Phylogenetic tree of cytochrome c oxidase subunit 1 gene sequences of the *Dirofilaria* species. *Brugia malayi* was used as the outgroup. Numbers along branches are bootstrap values. Red dots indicate *Dirofilaria* isolated in the present study. Scale bars indicate nucleotide substitutions per site.