

# *Leishmania donovani* Infection with Atypical Cutaneous Manifestations, Himachal Pradesh, India, 2014–2018

Lovlesh Thakur, Kiran K. Singh, Hemant R. Kushwaha, Sudarshan K. Sharma, Vinay Shankar, Ajeet Negi, Ghanshyam Verma, Sandhya Kumari, Aklank Jain, Manju Jain

We conducted a molecular study of parasite sequences from a cohort of cutaneous leishmaniasis patients in Himachal Pradesh, India. Results revealed atypical cutaneous disease caused by *Leishmania donovani* parasites. *L. donovani* variants causing cutaneous manifestations in this region are different from those causing visceral leishmaniasis in northeastern India.

Leishmaniasis is a complex disease with cutaneous, mucocutaneous, or visceral manifestations depending on the parasite species and host immunity. Despite continued elimination efforts, leishmaniasis continues to afflict known and newer endemic regions, where 0.5–0.9 million new cases of visceral leishmaniasis (VL) and 0.6–1.0 million new cases of cutaneous leishmaniasis (CL) occur every year (1). An increase in VL and CL cases from newer foci and atypical disease manifestation pose a challenge to leishmaniasis control programs (2–7). Unlike the known species-specific disease phenotype, parasite variants can cause atypical disease, so that *Leishmania* species generally associated with VL can cause CL and vice versa.

In India, VL caused by *L. donovani* parasites in the northeastern region and CL caused by *L. tropica* in the western Thar Desert represent the prevalent forms of the disease (2). Himachal Pradesh is a more recently leishmaniasis-endemic state in northwest where VL and CL coexist; CL incidence is higher than VL incidence and most cases are attributable to *L. donovani* instead of *L. tropica* infection (8,9). Sharma

et al. conducted limited molecular analysis of a few CL cases and reported preliminary findings (8). For an in-depth study on the involvement of *L. donovani* parasites in CL cases, we conducted a comprehensive molecular analysis of CL cases in Himachal Pradesh.

## The Study

During 2014–2018, an increase in CL cases occurred in Himachal Pradesh; case reports came from different tehsils (i.e., townships) in Kinnaur, Shimla, and Kullu and the previously nonendemic districts of Mandi and Solan (Appendix Table 1, Figure 1, <https://wwwnc.cdc.gov/EID/article/26/8/19-1761-App1.pdf>). We confirmed 60 CL cases indigenous to the state with detailed patient information, demonstration of the presence of Leishman-Donovan bodies and CL-specific histopathologic changes in skin lesional specimens, and PCR detection of parasitic infection (Appendix).

We conducted PCR and restriction fragment-length polymorphism (RFLP) analysis of parasite species-specific internal transcribed spacer 1 (ITS1) sequences by using appropriate standard controls. We detected the expected ≈320-bp product with a *Hae*III RFLP pattern specific to *L. donovani* complex in all patient biopsy specimens, indicating *L. donovani*, *L. infantum*, or both as the causative agent of infection (Appendix Figure 4) (10).

BLAST analysis (<https://blast.ncbi.nlm.nih.gov/Blast.cgi>) of 44 ITS1 test sequences showed all the samples to be closest to *L. donovani*, having maximum identity to *L. donovani* isolates from Bhutan (GenBank accession nos. JQ730001–2) and possibly *L. infantum*. None of the CL cases were consistent with *L. tropica* infection, unlike in a previous report (8). To distinguish whether HP isolates were *L. donovani*, *L. infantum*, or both and to infer genetic and geographic relatedness between

Author affiliations: Central University of Punjab, Bathinda, India (L. Thakur, K.K. Singh, A. Jain, M. Jain); Jawaharlal Nehru University, New Delhi, India (H.R. Kushwaha); Indira Gandhi Medical College, Shimla, India (S.K. Sharma, A. Negi, G. Verma, S. Kumari); Maharishi Markandeshwar Medical College and Hospital, Kumarhatti-Solan, India (V. Shankar)

DOI: <https://doi.org/10.3201/eid2608.191761>

these isolates and standard reference strains, we performed ITS1 microsatellite repeat analysis and phylogenetic classification (11–13). The 4 ITS1 polymorphic microsatellite repeat analysis indicate HP

isolates different from *L. infantum* and closest to the *L. donovani* isolates from Bhutan (Table 1; Figure 1, panel A). We detected a polymorphism in the third poly (TA) microsatellite locus with 5 repeats and

**Table 1.** Standard *Leishmania* strains used in ITS1-based microsatellite polymorphism and phylogenetic analysis of cutaneous leishmaniasis isolates, Himachal Pradesh, India, 2014–2018\*

Standard <i>Leishmania</i> strains (place of origin)	WHO code	Genbank accession no.	Zymodeme	Disease form	Strain type†	ITS1 polymorphic microsatellite stretches (nucleotide position, bp)			
						Poly C (24–39)	Poly A (24–39)	Poly TA (61–76)	Poly A (124–134)
VL- and CL-causing <i>L. infantum</i> and <i>L. donovani</i> parasite strains									
<i>L. infantum</i> (Tunisia)	MHOM/TN/80/IPT1	AJ000289	MON-1	VL	A	3	6	4	8
<i>L. donovani</i> (India)	MHOM/IN/00/DEVI	AJ634376	MON-2	VL	H	2	8	5	7
<i>L. donovani</i> (Sri Lanka)	MHOM/LK/2002/L60c	AM901447	MON-37	CL	ND	2	8	5	7
<i>L. donovani</i> (Bangladesh)	ND	KT921417	ND	VL	ND	2	8	5	7
<i>L. donovani</i> (Kenya)	MHOM/KE/85/NLB323	AJ000297	MON-37	VL	G	2	8	5	7
<i>L. donovani</i> (Sudan)	MHOM/SD/75/LV139	AJ000291	ND	CL	E	2	8	6	8
	MHOM/SD/93/9S	AJ634372	MON-18	VL	F	2	9	5	7
<i>L. donovani</i> (Ethiopia)	MHOM/ET/67/HU3	AJ634373	MON-18	VL	F	2	9	5	7
<i>L. donovani</i> (China)	MHOM/CN/00/Wangjie1	AJ000294	MON-35	VL	C	3	6	4	7
<i>L. donovani</i> (HP, India)	MHOM/IN/83/CHANDIGARH	AM901449	MON-37	VL	ND	2	8	2, TAA, 3	7
<i>L. donovani</i> (Bhutan)	Trashigang1	JQ730001	ND	VL	ND	2	8	2, TAA, 3	8
	Samtse1	JQ730002	ND	VL	ND	2	9	2, TAA, 3	8
CL-causing <i>L. donovani</i> isolates from Himachal Pradesh‡									
HPCL22	–	MG982955	ND	CL	ND	Heterogeneous		2, TAA, 3	8
HPCL27	–	MG982958	ND	CL	ND	Heterogeneous		2, TAA, 3	8
HPCL28	–	MG982959	ND	CL	ND	Heterogeneous		2, TAA, 3	8
HPCL32	–	MG982963	ND	CL	ND	Heterogeneous		2, TAA, 3	8
HPCL42	–	MG982972	ND	CL	ND	Heterogeneous		2, TAA, 3	8
HPCL45	–	MG982975	ND	CL	ND	Heterogeneous		2, TAA, 3	8
HPCL47	–	MG982977	ND	CL	ND	Heterogeneous		2, TAA, 3	8
HPCL49	–	MG982978	ND	CL	ND	Heterogeneous		2, TAA, 3	8
HPCL52	–	MG982981	ND	CL	ND	Heterogeneous		2, TAA, 3	8
HPCL55	–	MG982983	ND	CL	ND	Heterogeneous		2, TAA, 3	8
CL-causing standard WHO <i>Leishmania</i> species									
<i>L. major</i>	MHOM/SU/73/5ASKH	AJ000310	MON-4	CL	ND	4	6	6	6
<i>L. tropica</i>	MHOM/SU/60/OD	EU326226	LON-7	CL	ND	4	9	1, TTA, 2	3,C,4A
<i>L. mexicana</i>	MHOM/MX/85/SOLIS	AJ000313	MON-152	CL	ND	2	8	1,	3,C,7A
<i>L. braziliensis</i>	MHOM/BR/00/LTB300	FN398338	MON-166	CL	ND	2	6	1	5
<i>L. amazonensis</i>	MHOM/BR/73/M2269	HG512964	MON-132	CL	ND	2	7	1	3,C,6A

\*CL, cutaneous leishmaniasis; HP, Himachal Pradesh; ITS1, internal transcribed spacer 1; ND, not determined; VL, visceral leishmaniasis; WHO, World Health Organization.

†ITS sequences strain type according to Kuhls et al. (13).

‡These species represent 10/44 samples used in polymorphic microsatellite analysis.



**Table 2.** Standard *Leishmania* strains used in partial 6PGDH amino acid–based phylogenetic analysis of cutaneous leishmaniasis isolates, Himachal Pradesh, India, 2014–2018\*

Species (place of origin)	WHO code	Zymodeme	GenBank accession no.	Pathology
<b>WHO standards</b>				
<i>L. donovani</i> (India)	MHOM/IN/0000/DEVI	MON-2	AM157147	VL
<i>L. major</i> (Turkmenistan)	MHOM/TM/1973/5ASKH	ND	AY706107	CL
<i>L. infantum</i>	ND	ND	XM_001469106	ND
<i>L. mexicana</i>	MHOM/BZ/82/BEL21	ND	AY386372	CL
<i>L. tropica</i>	ND	ND	AY045763	CL
<i>L. amazonensis</i>	ND	ND	AY168562	CL
<b>Regional standards</b>				
<i>L. donovani</i> (China)	MHOM/CN/90/9044	ND	JX021389	VL
<i>L. donovani</i> (Kenya)	IMAR/KE/1962/LRC–L57	MON-37	AJ888902	ND
<i>L. donovani</i> (Sri Lanka)	MHOM/LK/2010/OVN3	MON-37	JX481773	VL
<i>L. donovani</i> (Sri Lanka)	MHOM/LK/2002/L59	MON-37	AJ888888	CL
<i>L. donovani</i> (Bangladesh)	MHOM/BD/1997/BG1	ND	AJ888899	VL
<i>L. donovani</i> (Brazil)	ND	ND	AY168567	ND
<i>L. donovani</i> (Kerala, India)	ND	ND	KJ461872	CL

\*6PGDH, 6-phosphogluconate dehydrogenase gene; CL, cutaneous leishmaniasis; ND, not determined; VL, visceral leishmaniasis; WHO, World Health Organization.

the third poly (TA) stretch (12). However, Himachal Pradesh isolates were distinct at the first poly C and the second poly A microsatellite tracts and had heterogeneous base sequences. Thus, these isolates represent *L. donovani* genetic variants; none showed the ITS1 sequence type previously assigned to the referred *L. donovani* isolates by Kuhls et al. (13). Our phylogenetic analysis of 44 ITS1 test sequences and ITS1 reference sequences placed all the CL-causing *L. donovani* isolates from Himachal Pradesh into a discrete cluster different from the VL-causing *L. donovani* from India and elsewhere and the CL-causing *L. donovani* isolates from Sri Lanka. The Himachal Pradesh CL isolates within the cluster exhibited considerable heterogeneity (Table 1; Figure 1, panel B; Appendix Table 4).

Sequences of the 6-phosphogluconate dehydrogenase gene (6PGDH) exhibit a high degree of polymorphism and have been used to identify *Leishmania* species and differentiate region-specific zymodemes (14). We performed multiple sequence alignment of the representative partial 6PGDH amino acid sequences from Himachal Pradesh isolates by using the homologous 6PGDH protein sequences of the reference *Leishmania* isolates to determine their genetic and geographic relatedness (Table 2; Figure 2, panel A; Appendix Table 4, Figure 5). Himachal Pradesh isolates exhibited a 6PGDH sequence specific to Mon-37 and different from Mon-2 (having aspartic acid in place of asparagine) at position 326 (Figure 2, panel A). Thus, CL-causing *L. donovani* from Himachal Pradesh were distinct from the most common VL-causing India Mon-2 *L. donovani* and the Bangladesh *L. donovani* isolate, whereas they were similar to the CL-causing *L. donovani* isolate from Kerala and CL- and VL-causing Mon-37

isolates from Sri Lanka and the isolates from Kenya, Brazil, and China.

Phylogenetic analysis of 6PGDH amino acid sequences of CL isolates grouped them into a heterogeneous cluster; variants were closer to a viscerotropic *L. donovani* isolate from Sri Lanka and distinct from the VL-causing *L. donovani* isolates from India and Bangladesh and CL-causing isolates from Kerala and Sri Lanka (Figure 2, panel B). However, the HPCL55 isolate (GenBank accession no. MH208450) grouped differently. The HPCL49 isolate (GenBank accession no. MH208446) showed relatedness to the standard *L. infantum* strain, although ITS1 analysis using BLAST and microsatellite repeat sequences showed regions of similarity with *L. donovani*. ITS1 and 6PGDH sequence analysis suggest that Himachal Pradesh isolates from CL patients consist of heterogeneous *L. donovani* variants and possibly represent hybrid genotypes.

None of the CL patients had VL-specific symptoms or VL history. Ten of 43 patient blood samples tested positive for rK39 antibody, and 37 of 51 samples were positive for the circulating parasite DNA with *L. donovani*-specific ITS1 (Appendix Figure 6, panel A, B). The result suggests asymptomatic systemic *L. donovani* infection in a fraction of CL patients.

## Conclusions

The presence of leishmaniasis in Himachal Pradesh is not yet well known in India and globally (15). Our epidemiologic study shows newer CL pockets during 2014–2018; thus, the state needs to be recognized as leishmaniasis-endemic by public health authorities (Appendix Figure 1). We conclude that CL cases in Himachal Pradesh are caused by *L. donovani* variants



distinct from the viscerotropic *L. donovani* strain from northeast India. The CL isolates in Himachal Pradesh exhibit considerable heterogeneity and indicate the possible existence of genetic hybrids. The scenario appears somewhat similar to Sri Lanka and Kerala, where *L. donovani* parasites cause cutaneous disease, albeit with differences in the region-specific *L. donovani* variants. In lieu of the coexistence of VL and CL in Himachal Pradesh, parasite isolates from VL patients also need to be characterized. To understand the biology of atypical *L. donovani* variants with cutaneous manifestations and to genetically differentiate the dermatropic versus viscerotropic potential of *L. donovani* variants, comparison of CL- and VL-causing isolates in Himachal Pradesh using whole-genome sequence analysis is required.

*L. donovani* parasites in the blood of some CL patients represent human reservoirs similar to asymptomatic VL carriers, and the parasite variants have the potential to cause full-blown VL manifestations. An elaborate surveillance program dedicated to the Himachal Pradesh region is urgently required for better diagnosis, treatment, prediction of parasite variants in different afflicted pockets, and prevention of transmission of the disease to other regions.

### Acknowledgments

We thank Greg Matlashewski for his helpful suggestions and comments to improve the manuscript, Wen Wei Zhang for technical suggestions, and Rentala Madhubala for generously gifting *Leishmania donovani* and *L. major* standard cultures.

### About the Author

Ms. Thakur is a PhD student in the Department of Zoology at the Central University of Punjab, Bathinda, Punjab, India. Her primary research interests include the epidemiology and pathogenesis of infectious and parasitic diseases.

### References

1. World Health Organization. Leishmaniasis. 2019 [cited 2019 Sep 1]. <https://www.who.int/en/news-room/fact-sheets/detail/leishmaniasis>
2. Thakur L, Singh KK, Shanker V, Negi A, Jain A, Matlashewski G, et al. Atypical leishmaniasis: a global perspective with emphasis on the Indian subcontinent. *PLoS Negl Trop Dis*. 2018;12:e0006659. <https://doi.org/10.1371/journal.pntd.0006659>
3. Sandhya R, Rakesh P, Dev S. Emergence of visceral leishmaniasis in Kollam District, Kerala, southern India. *Int J Community Med Public Health*. 2019;6:1350–2. <https://doi.org/10.18203/2394-6040.ijcmph20190639>
4. Kumar NP, Srinivasan R, Anish TS, Nandakumar G, Jambulingam P. Cutaneous leishmaniasis caused by *Leishmania donovani* in the tribal population of the Agasthyamala Biosphere Reserve Forest, Western Ghats, Kerala, India. *J Med Microbiol*. 2015;64:157–63. <https://doi.org/10.1099/jmm.0.076695-0>
5. Siriwardana Y, Zhou G, Deepachandi B, Akarawita J, Wickremarathne C, Warnasuriya W, et al. Trends in recently emerged *Leishmania donovani* induced cutaneous leishmaniasis, Sri Lanka, for the first 13 Years. *BioMed Res Int*. 2019;2019:4093603. <https://doi.org/10.1155/2019/4093603>
6. Sharma NL, Mahajan VK, Negi AK. Epidemiology of a new focus of localized cutaneous leishmaniasis in Himachal Pradesh. *J Commun Dis*. 2005;37:275–9. PubMed
7. Kumari S, Garg A. Lip leishmaniasis: a new emerging clinical form of cutaneous leishmaniasis from sub-Himalayan Region. *Journal of Medical Science and Clinical Research*. 2018;06:62–9.
8. Sharma NL, Mahajan VK, Kanga A, Sood A, Katoch VM, Mauricio I, et al. Localized cutaneous leishmaniasis due to *Leishmania donovani* and *Leishmania tropica*: preliminary findings of the study of 161 new cases from a new endemic focus in Himachal Pradesh, India. *Am J Trop Med Hyg*. 2005;72:819–24. <https://doi.org/10.4269/ajtmh.2005.72.819>
9. Sharma NL, Sood A, Arora S, Kanga A, Mahajan V, Negi A, et al. Characteristics of *Leishmania* spp. isolated from a mixed focus of cutaneous and visceral leishmaniasis in Himachal Pradesh (India). *Internet J Third World Med*. 2009;7(8).
10. el Tai NO, Osman OF, el Fari M, Presber W, Schönian G. Genetic heterogeneity of ribosomal internal transcribed spacer in clinical samples of *Leishmania donovani* spotted on filter paper as revealed by single-strand conformation polymorphisms and sequencing. *Trans R Soc Trop Med Hyg*. 2000;94:575–9. [https://doi.org/10.1016/S0035-9203\(00\)90093-2](https://doi.org/10.1016/S0035-9203(00)90093-2)
11. Dávila AM, Momen H. Internal-transcribed-spacer (ITS) sequences used to explore phylogenetic relationships within *Leishmania*. *Ann Trop Med Parasitol*. 2000;94:651–4. <https://doi.org/10.1080/00034983.2000.11813588>
12. Yangzom T, Cruz I, Bern C, Argaw D, den Boer M, Vélez ID, et al. Endemic transmission of visceral leishmaniasis in Bhutan. *Am J Trop Med Hyg*. 2012;87:1028–37. <https://doi.org/10.4269/ajtmh.2012.12-0211>
13. Kuhls K, Mauricio IL, Pratloug F, Presber W, Schönian G. Analysis of ribosomal DNA internal transcribed spacer sequences of the *Leishmania donovani* complex. *Microbes Infect*. 2005;7:1224–34. <https://doi.org/10.1016/j.micinf.2005.04.009>
14. Ranasinghe S, Zhang W-W, Wickremasinghe R, Abeygunasekera P, Chandrasekharan V, Athauda S, et al. *Leishmania donovani* zymodeme MON-37 isolated from an autochthonous visceral leishmaniasis patient in Sri Lanka. *Pathog Glob Health*. 2012;106:421–4. <https://doi.org/10.1179/2047773212Y.0000000054>
15. World Health Organization. Leishmaniasis country profile–2015, India. 2017 [cited 2019 Sep 1]. [https://www.who.int/leishmaniasis/burden/India\\_2015-hl.pdf?ua=1](https://www.who.int/leishmaniasis/burden/India_2015-hl.pdf?ua=1)

Address for correspondence: Manju Jain, Department of Biochemistry, Central University of Punjab, City Campus, Mansa Rd, Bathinda, Punjab, 151001, India, email: manjujainmda@gmail.com

# *Leishmania donovani* Infection with Atypical Cutaneous Manifestations, Himachal Pradesh, India, 2014–2018

## Appendix

### Material and Methods

#### Study Design and Ethics

Lesional biopsies and blood samples were collected from the CL patients reporting at Department of Dermatology, Indira Gandhi Medical College (IGMC), Shimla and Mahatma Gandhi Medical Services Complex (MGMSC) Khaneri in Rampur, Himachal Pradesh, India. Informed consent was obtained from all the patients in the study. The study was conducted on 60 CL patients, in the age group of 4 to 70 years at the time of diagnosis over the period from 2014 to 2018. Baseline characteristics of the patients with clinical details were compiled from the standard case report forms (Appendix Table 2). Patient history regarding the visit to endemic areas, residence, place where the disease was acquired, age with lesion duration, location and distribution was recorded on the date of sample collection. Lesional 4 mm punch biopsies were taken from the active edge of the lesions from 57 patients and processed for parasite detection, histopathological and molecular studies. Blood samples were taken to assess seroprevalence of rK39 antibody. The protocol of the present study was approved by the Institutional Ethics Committee IGMC, Shimla, H.P., Approval no. HFW (MS) G-5 (Ethics)/2014–10886 and Central University of Punjab, Punjab, Approval no. CUPB/IEC/2016/034.

#### Clinical Diagnostics

Lesional biopsy samples were processed for parasite detection using Giemsa stained touch smears, Hematoxylin and Eosin (H & E) stained paraffin-embedded tissue sections as per standard protocol (1,2). Laboratory grown reference strains, *L. donovani* and *L. major* to be used as controls in different experiments, were grown under promastigote supporting growth conditions in RPMI with 5% FBS, Penicillin (100 units/ml) and Streptomycin (100ug/ml).

A part of the lesional biopsy from the CL cases was processed for examining CL specific histopathological changes. The samples were processed in 10% NBF, embedded in paraffin and processed to 4 to 5 µm thick tissue sections. Tissue sections were stained with H&E and examined for epidermal and dermal histopathological changes specific to cutaneous lesions (2).

#### **Serum Isolation and rK39 Strip Assay**

Blood samples collected from 50/60 patients were used to isolate sera. The rK39 immunochromatographic rapid diagnostic test was performed to determine the seroprevalence of rK39 antibody as per manufacturer instructions (InBios International, Inc. Seattle, WA 98104). Briefly, 20 µl of serum was loaded on to the strip followed with addition of chase buffer solution. Samples were read after 10 minutes and considered positive for the presence of anti-K39 IgG with two distinct red lines corresponding to the, test region and the control region.

#### **Molecular Analysis**

Skin lesion specimens from 57/60 patients and laboratory-grown *L. donovani* and *L. major* cultures (used as controls) were used to isolate Genomic DNA (gDNA) as described previously (3). gDNA from patients' blood samples was also isolated to analyze presence of circulating parasite. gDNA from the test and control samples was used to perform species-specific ribosomal internal transcribed spacer 1 region (ITS1) PCR-RFLP assay and 6-phosphogluconate dehydrogenase (6PGDH) gene amplification (Appendix Figure 4, 5). Both ITS1 and 6PGDH amplification products were sequenced for species identification and to decipher genetic relatedness of the HP isolates with other region-specific VL and CL causing *Leishmania* isolates (4–8).

#### **ITS1 PCR-RFLP**

Parasite specific ITS1PCR amplification was done for all the samples with primers LITSR (5'-CTGGATCATTTTCCGATG-3') and L5.8S (5'-TGATACCACTTATCGCACTT-3') as described previously (3,4). Briefly 50–100 ng of gDNA was used as template and amplified with 10 pmol of each primer using Go Taq Green Master mix, 1X (Promega, Cat # M7122) in a reaction volume of 25 µl. Reaction conditions comprised an initial denaturation at 95°C for 2 min, 34 cycles of denaturation at 95°C for 20 sec, annealing at 53°C for 30 sec and extension at 72°C for 1 min with the final extension at 72°C for 6 min. The PCR product of ~ 320 bp size was



subjected to *Hae*III RFLP with overnight *Hae*III digestion at 37°C and run on 2.5% agarose gel to identify the *Leishmania* species.

#### **6PGDH PCR**

6PGDH amplification was done with primers 6PGDH-F: AATCGAGCAGCTCAAGGAAG and 6PGDH-R: GAGCTTGGCGAGAATCTGAC as described previously (7, 8). 50–100 ng of gDNA was amplified with 10 pmol of each primer using Go Taq Green Master mix, 1X (Promega, Cat # M7122) in a reaction volume of 25 µl. The reaction conditions comprised denaturation at 95°C for 5 min, 30 cycles of denaturation at 95°C for 1 min, annealing at 56°C for 30 secs and extension at 72°C for 1 min with the final extension at 72°C for 10 min. The PCR product was run on 1.8% agarose gel.

#### **Sequencing and Phylogenetic Analysis**

DNA sequencing of ITS1 and 6PGDH PCR products was done for identification of *Leishmania* species/species variants in relation to CL and VL causing standard *Leishmania* isolates from different regions (Table 1, <https://wwwnc.cdc.gov/EID/article/26/8/19-1761-T1.htm>; Table 2, <https://wwwnc.cdc.gov/EID/article/26/8/19-1761-T2.htm>). ITS1 PCR products from 44 samples and 6PGDH PCR products from 28 samples were outsourced for Sanger sequencing. ITS1 sequences from 44 specimens with Accession numbers MG982941 to MG982984 and 6PGDH sequences from 28 specimens with Accession numbers MH208423 to MH208450 were deposited in Genbank (Appendix Table 4).

The homologous gene sequences for ITS1 and 6PGDH of standard WHO *Leishmania* species specific isolates and region specific *L. donovani* isolates were retrieved from the NCBI-GenBank database. ITS1 nt query sequences from 44 specimens were analyzed using BLAST and multiple alignment software, MUSCLE using default parameters (9). The final alignment was made using BioEdit sequence alignment editor (version 7.0.5.3). The maximum likelihood tree from the aligned sequences was obtained with 5000 bootstraps with default parameters using the *dnaml* program of the phylip package (10). The final tree was plotted using FigTree software (version 1.4.3). To analyze 6PGDH protein sequences, gene sequences from 28 CL samples were translated into the corresponding homologous protein sequences using translate tool at ExPASy. The representative protein sequences of the seven clusters obtained from the 28 test 6PGDH protein sequences were analyzed in relation to the homologous 6PGDH protein sequences of the

reference *Leishmania* strains using the methods explained previously. The partial 6PGDH sequence alignment was made using Jalview multiple alignment editor version 2.10.4b1 (11). The maximum likelihood tree was obtained with 5000 bootstraps using the *proml* program of the phylip package with default parameters (10).

## **Results Section**

### **Disease Epidemiology**

During the period from 2014–2018, an increase in CL cases in the routine skin OPD was recorded in IGMC, Shimla and MGMSC, Khaneri, Rampur. A detailed record of patients suspected with CL was taken at the time of diagnosis (Appendix Table 2). In our study on 60 CL patients, there was an almost equivalent frequency of females (51.6%) and males (48.3%) ranging in age from 4 years to 70 years. The majority of the patients belonged to the indigenous students and the farming community. All the patients had localized cutaneous skin lesions predominantly on exposed body parts with involvement of the face in majority of the cases. The time gap between the appearance of lesions and disease diagnostics on the day of sample collection, ranged from 10 days to 2.6 years with most cases reporting within 3–4 months of disease occurrence, indicating a lack of awareness among local population. Most of the patients had one or two raised and itchy lesions presented as plaques, nodules and/or papules, often ulcerated unlike those present in post kala azar dermal leishmaniasis. Around 26% of cases had mucocutaneous like lesions extending to the inner nose consistent with previous reports (12, 13; Appendix Table 2).

### **Clinical Diagnostics**

Clinical confirmation of the CL cases was performed by microscopic examination of Giemsa stained lesion touch smears, H & E stained biopsy sections for the presence of LD bodies and by parasite-specific ITS1 and 6PGDH PCR analysis (Appendix Figure 2, panels A–C; Appendix Table 2). Giemsa stained tissue smears were LD positive for 50% (23/46) of the samples processed with non-availability of the smears for 14 patients. 38% (19/50) H&E stained biopsy sections were positive for LD bodies. Only 11 patients demonstrated LD positivity in both the tissue smears and the histologic sections. Patients negative for LD bodies were, however, positive for the infection based on the PCR based parasite detection. Also, the CL

lesion-specific histopathological analysis of biopsy sections performed for 50 patients exhibited characteristic dermal and epidermal changes to variable extents (Appendix Figure 3, panels A–F; Appendix Table 3). The characteristic CL lesion-specific epidermal changes with acanthosis and papillomatosis along with varying degree of keratosis accompanied granulomatous inflammation as assessed by a trained pathologist. These findings confirmed that all the 60 CL cases were positive for *Leishmania* infection and displayed varying degrees of CL specific lesional pathologies.

## References

1. Bain BJ, Bates I, Laffan MA. Dacie and Lewis practical haematology e-book. London: Elsevier Health Sciences; 2016 [cited 2020 Apr 3]. <https://www.elsevier.com/books/dacie-and-lewis-practical-haematology/bain/978-0-7020-6696-2>
2. Lever WF, Elder DE, Elenitsas R, Johnson BL, Murphy GF. Lever's histopathology of the skin. Philadelphia: Wolters Kluwer Health; 2009.
3. Salotra P, Sreenivas G, Pogue GP, Lee N, Nakhasi HL, Ramesh V, et al. Development of a species-specific PCR assay for detection of *Leishmania donovani* in clinical samples from patients with kala-azar and post-kala-azar dermal leishmaniasis. J Clin Microbiol. 2001;39:849–54. [PubMed https://doi.org/10.1128/JCM.39.3.849-854.2001](https://doi.org/10.1128/JCM.39.3.849-854.2001)
4. el Tai NO, Osman OF, el Fari M, Presber W, Schönian G. Genetic heterogeneity of ribosomal internal transcribed spacer in clinical samples of *Leishmania donovani* spotted on filter paper as revealed by single-strand conformation polymorphisms and sequencing. Trans R Soc Trop Med Hyg. 2000;94:575–9. [PubMed https://doi.org/10.1016/S0035-9203\(00\)90093-2](https://doi.org/10.1016/S0035-9203(00)90093-2)
5. Dávila AM, Momen H. Internal-transcribed-spacer (ITS) sequences used to explore phylogenetic relationships within *Leishmania*. Ann Trop Med Parasitol. 2000;94:651–4. [PubMed https://doi.org/10.1080/00034983.2000.11813588](https://doi.org/10.1080/00034983.2000.11813588)
6. Yangzom T, Cruz I, Bern C, Argaw D, den Boer M, Vélez ID, et al. Endemic transmission of visceral leishmaniasis in Bhutan. Am J Trop Med Hyg. 2012;87:1028–37. [PubMed https://doi.org/10.4269/ajtmh.2012.12-0211](https://doi.org/10.4269/ajtmh.2012.12-0211)
7. Siriwardana HV, Noyes HA, Beeching NJ, Chance ML, Karunaweera ND, Bates PA. *Leishmania donovani* and cutaneous leishmaniasis, Sri Lanka. Emerg Infect Dis. 2007;13:476–8. [PubMed https://doi.org/10.3201/eid1303.060242](https://doi.org/10.3201/eid1303.060242)

8. Ranasinghe S, Zhang W-W, Wickremasinghe R, Abeygunasekera P, Chandrasekharan V, Athauda S, et al. *Leishmania donovani* zymodeme MON-37 isolated from an autochthonous visceral leishmaniasis patient in Sri Lanka. *Pathog Glob Health*. 2012;106:421–4. [PubMed](#) <https://doi.org/10.1179/2047773212Y.0000000054>
9. Edgar RC. MUSCLE: multiple sequence alignment with high accuracy and high throughput. *Nucleic Acids Res*. 2004;32:1792–7. [PubMed](#) <https://doi.org/10.1093/nar/gkh340>
10. Felsenstein J. PHYLIP (phylogeny inference package) version 3.6. 2005 [cited 2019 Dec 11]. <http://evolution.genetics.washington.edu/phylip.html>
11. Clamp M, Cuff J, Searle SM, Barton GJ. The Jalview Java alignment editor. *Bioinformatics*. 2004;20:426–7. [PubMed](#) <https://doi.org/10.1093/bioinformatics/btg430>
12. Thakur L, Singh KK, Shanker V, Negi A, Jain A, Matlashewski G, et al. Atypical leishmaniasis: a global perspective with emphasis on the Indian subcontinent. *PLoS Negl Trop Dis*. 2018;12:e0006659. [PubMed](#) <https://doi.org/10.1371/journal.pntd.0006659>
13. Kumari S, Garg A. Lip leishmaniasis: a new emerging clinical form of cutaneous leishmaniasis from sub-Himalayan Region. *Journal of Medical Science and Clinical Research*. 2018;06:62–9.
14. Sharma NL, Mahajan VK, Negi AK. Epidemiology of a new focus of localized cutaneous leishmaniasis in Himachal Pradesh. *J Commun Dis*. 2005;37:275–9.

**Appendix Table 1.** Expansion of older and newer endemic pockets of atypical CL in Himachal Pradesh

Districts*	Blocks/Tehsils		References
	Newer blocks/tehsils	Earlier reported blocks/tehsils	
Kinnaur	Kalpa, Sangla	Nichar, Pooh	(14)
Shimla	Shimla, Nankhari, Kotkhari, Mashobra, Theog, Chaupal, Basantpur, Rohru	Rampur, Kumarsain	(13)
Kullu	Banjar	Aani, Nirmand	
Newer districts	Newer blocks/tehsils		
Solan	Kunihar		
Mandi	Karsog, Thunag, Nehri, Sarkaghat		

\*For older districts, reports cover all reported through 2017.

**Appendix Table 2.** Baseline characteristics and clinical findings: cutaneous leishmaniasis patients from Himachal Pradesh

Total no. of CL cases, N = 60)	No. (%) by age group, y			Persons with occupations most affected (students and farmers)	Duration till clinical diagnosis	Patients with *MCL-like lesions	Parasite detection, No. (%)				
	0-20	21-40	>40				Total	Giemsa touch smears LD +ve= 23/46 (50)	H&E biopsy sections LD+ve= 19/50 (38)	ITS1 PCR +ve = 47/57 (≈82)	6PGDH PCR +ve = 33/55 (60)
Male, 29/60	10/29 (34.5)	14/29 (48.3)	5/29 (17.2)	12/20 (60)	25 d to 2.6 y	6/29 (20.7)	+ve	10/21 (47.6)	10/23 (43.47)	23/57 (40.3)	16/55 (29)
							-ve	8/21 (38.1)	13/23 (56.52)	6/57 (10.5)	11/55 (20)
							Doubtful	2/21 (9.5)			
							Not Done	8/29	6/29		
Female, 31/60	8/31 (25.8)	12/31 (38.7)	11/31 (35.5)	13/20 (65)	10 d to 1.6 y	10/31 (32.3)	+ve	13/25 (52)	9/27 (33.3)	24/57 (42.1)	17/55 (31)
							-ve	10/25 (40)	18/27 (66.6)	4/57 (7)	11/55 (20)
							Doubtful	3/25 (12)			
							Not done	6/31	4/31		

**Appendix Table 3.** Histopathological features of CL specific lesions in ACL patients from Himachal Pradesh

Histopathological feature	No. (%) ACL cases, N = 50
<b>Epidermal changes</b>	
Acanthosis	28 (56)
Papillomatosis	11 (22)
Hyperkeratosis	19 (38)
Parakeratosis	15 (30)
Spongiosis	3 (6)
Subcorneal blister	7 (14)
<b>Dermal changes</b>	
Granuloma	22 (44)
Histiocytes	19 (38)
Epithelioid cells	39 (78)
Plasma cells	37 (74)
Giant cell	3 (6)
Lymphocytes	23 (46)
Neutrophils	30 (60)
Microabscess formation	3 (6)
Occasional eosinophils	11 (22)
Civatte bodies	1 (2)
Fibrosis	3 (6)
Spongiosis	3 (6)
LD bodies	19 (38)

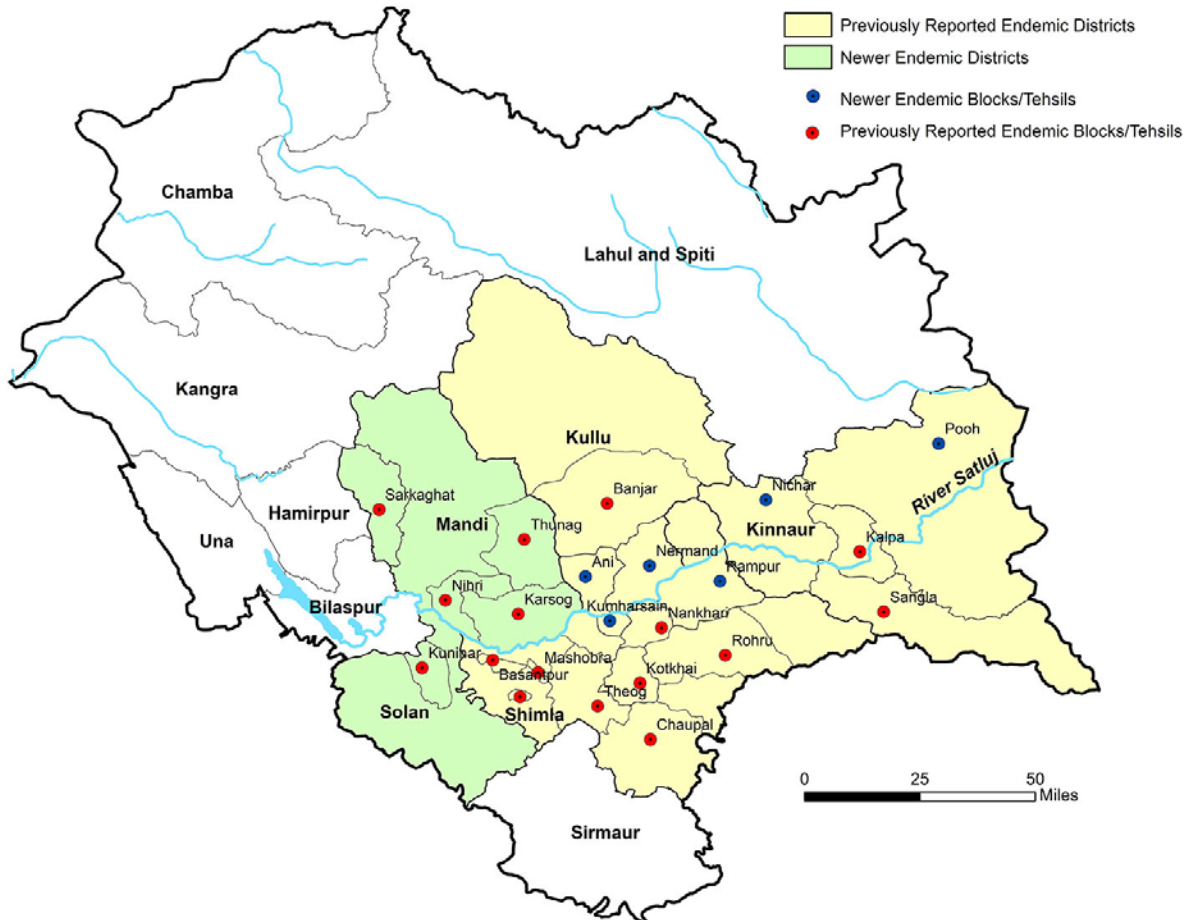\*ACL, atypical cutaneous leishmaniasis

**Appendix Table 4.** Accession numbers of ITS1 and 6PGDH sequences of *L. donovani* isolates from dermal lesions of cutaneous leishmaniasis patients from Himachal Pradesh\*

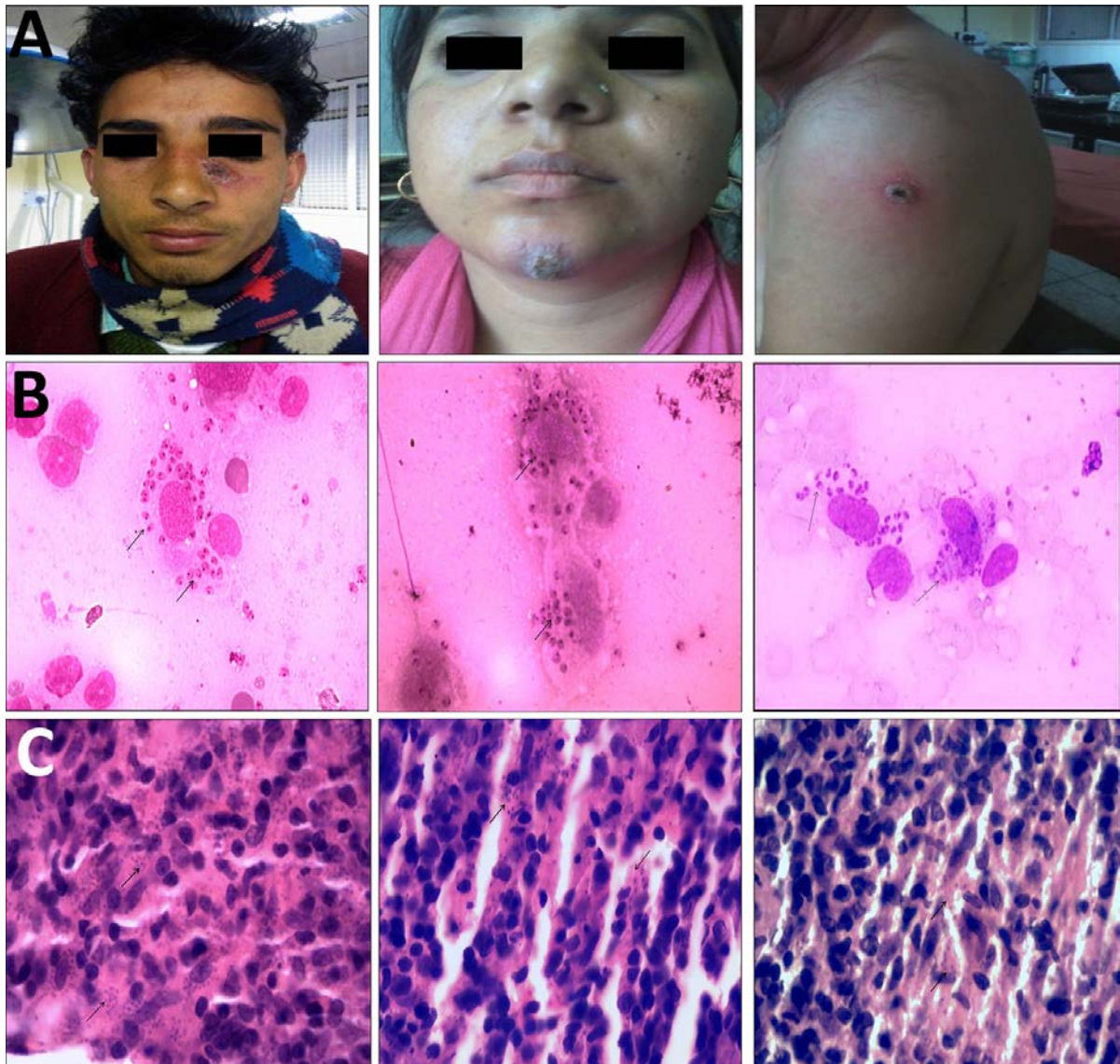
Sample no.	ITS1 accession no.	6PGDH accession no.
HPCL1	MG982941	MH208423
HPCL4	MG982942	
HPCL6	MG982943	MH208424
HPCL7	MG982944	MH208425
HPCL8	MG982945	
HPCL10	MG982946	
HPCL11	MG982947	MH208426
HPCL12	MG982948	MH208427
HPCL13	MG982949	MH208428
HPCL15	MG982950	MH208429
HPCL17	MG982951	
HPCL18	MG982952	
HPCL19	MG982953	MH208430
HPCL20	MG982954	MH208431
HPCL22	MG982955	
HPCL24	MG982956	
HPCL26	MG982957	MH208432
HPCL27	MG982958	MH208433
HPCL28	MG982959	MH208434
HPCL29	MG982960	MH208435
HPCL30	MG982961	
HPCL31	MG982962	
HPCL32	MG982963	
HPCL33	MG982964	
HPCL34	MG982965	MH208436
HPCL35	MG982966	MH208437
HPCL36	MG982967	
HPCL37	MG982968	
HPCL38	MG982969	MH208438
HPCL39	MG982970	MH208439
HPCL41	MG982971	MH208440
HPCL42	MG982972	MH208441
HPCL43	MG982973	
HPCL44	MG982974	MH208442
HPCL45	MG982975	MH208443
HPCL46	MG982976	MH208444
HPCL47	MG982977	MH208445
HPCL49	MG982978	MH208446

Sample no.	ITS1 accession no.	6PGDH accession no.
HPCL50	MG982979	MH208447
HPCL51	MG982980	
HPCL52	MG982981	MH208448
HPCL54	MG982982	MH208449
HPCL55	MG982983	MH208450
HPCL57	MG982984	

\*ITS1, internal transcribed spacer 1.

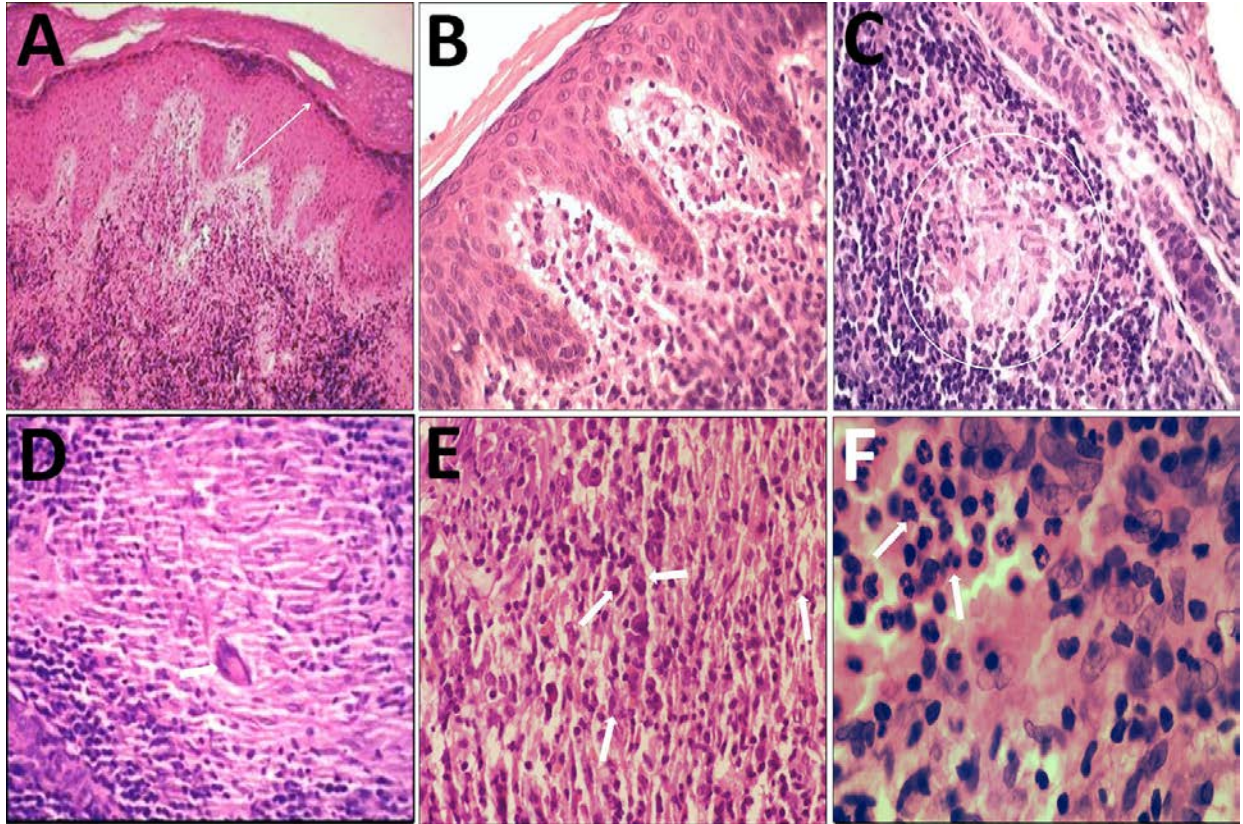


**Appendix Figure 1.** District map of Himachal Pradesh showing geographic distribution of atypical cutaneous leishmaniasis (ACL) cases in the newly endemic state. ACL cases from the skin OPD of reference hospitals (Indira Gandhi Medical College and Mahatma Gandhi Medical Services Complex, Shimla) and our data on patients enrolled in the study form the basis of data for disease distribution. Disease endemicity in state districts is indicated by different colors: yucca yellow shading for previously reported endemic districts and tzavorite green shading for newly emerging endemic districts. Regions with blue and red dots indicate previously reported and newly emerging endemic Blocks/Tehsils in the endemic districts of the state, respectively. The map was created using ArcGIS 10.3 software. The map showing regional distribution of disease was geo-referenced with UTM projection taking WGS84 datum. The unit of measurement for the scale bar is Kilometers.

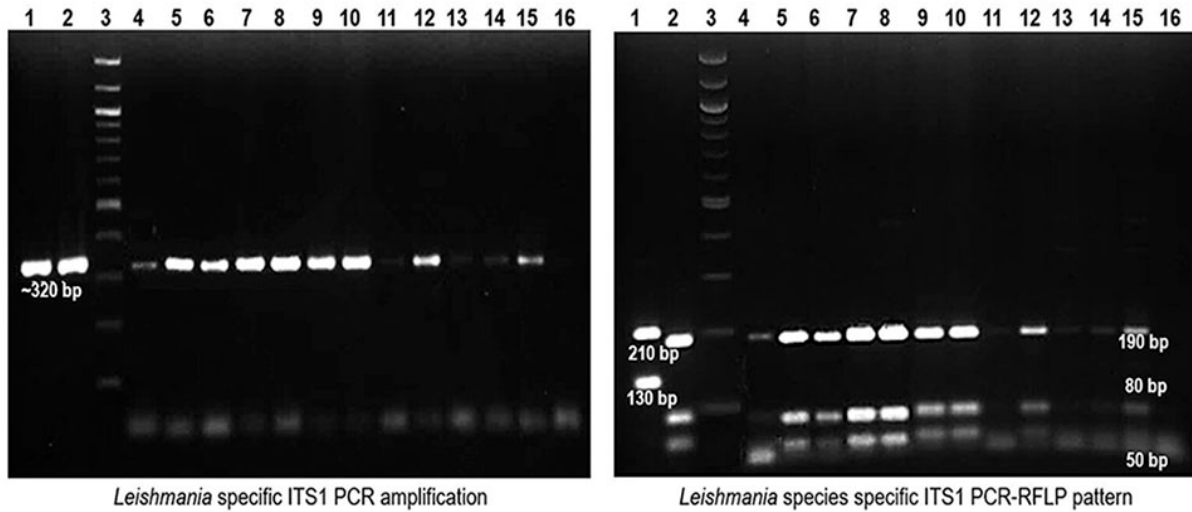


**Appendix Figure 2.** A) CL patients with characteristic lesions on exposed parts of the body. B) Giemsa stained tissue touch smears from patients with cutaneous leishmaniasis showing intracellular and extracellular LD bodies (arrowed). Original magnification x100. C) Hematoxylin & Eosin stained CL lesional biopsy sections showing intracellular and extracellular LD bodies (arrowed). Original magnification x100.

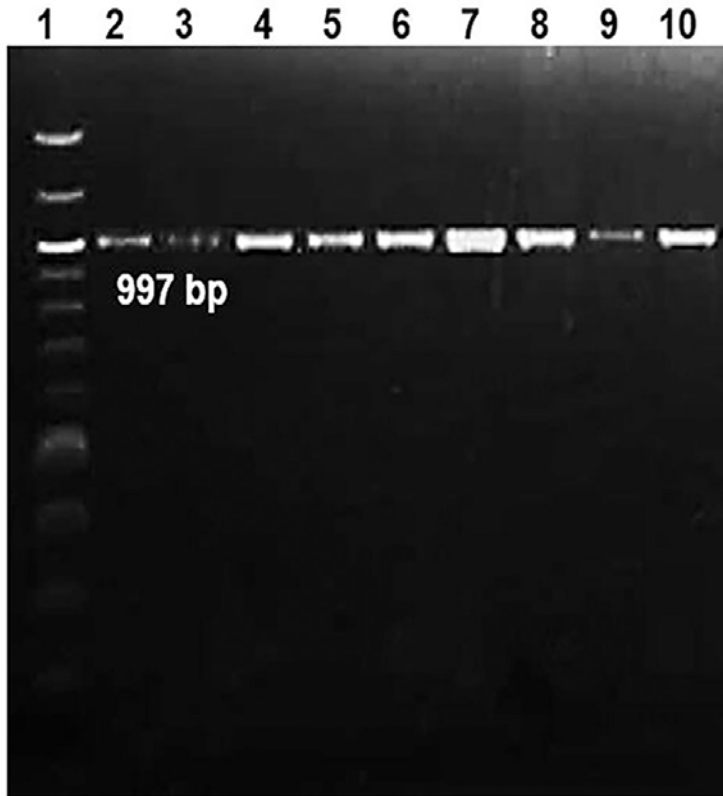




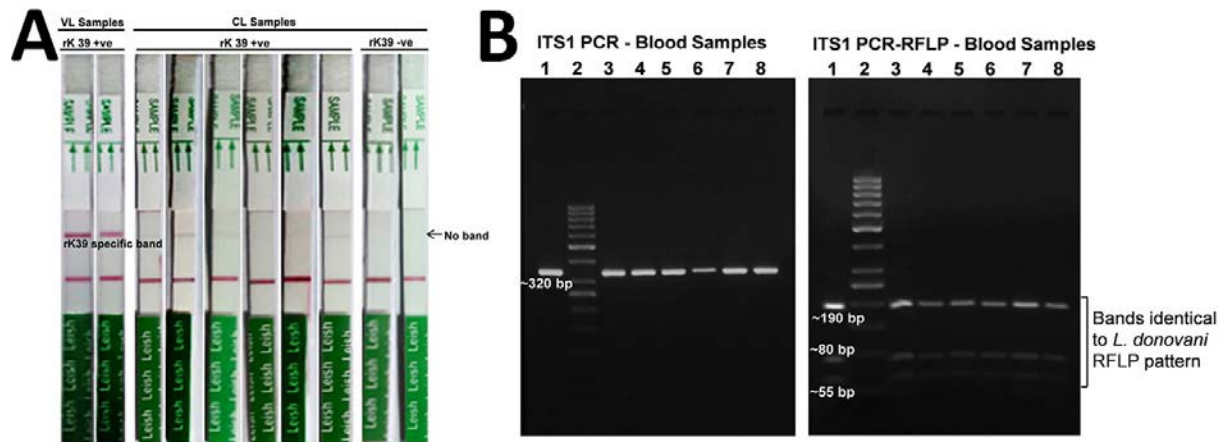
**Appendix Figure 3.** Histopathological characteristics of CL lesional tissue biopsies. Representative histopathological observations on Hematoxylin & Eosin stained tissue biopsy sections from CL patients. A) Mild acanthosis. Original magnification x4. B) Papillomatosis. Original magnification x10. C) Epithelioid cell granuloma (circled). Original magnification x40. D) Langhans giant cell (arrowed). Original magnification x40. E) Diffuse inflammatory cell infiltrate showing plasma cells and epithelioid cells. Original magnification x40. F) Microabscess. Original magnification x40.



**Appendix Figure 4:** *Leishmania* species-specific ITS1 PCR on DNA isolated from lesional biopsy samples from cutaneous leishmaniasis (CL) patients and *HaeIII* PCR-RFLP analysis of ITS1 region in test samples and standard *Leishmania* cultures used as positive controls. ITS1 PCR on cutaneous leishmaniasis patient samples. Lanes: 1, *L. major*; 2, *L. donovani*; 3, 100 bp DNA marker; 4–15, CL test samples; 16, water control. *HaeIII* RFLP of ITS1 PCR amplicon for *Leishmania* species identification. Lanes: 1, *L. major*; 2, *L. donovani*; 3, 100 bp DNA ladder; 4–15, CL test samples; 16, water control. ITS1, internal transcribed spacer 1; RFLP, restriction fragment length polymorphism.



**Appendix Figure 5:** 6PGDH PCR on cutaneous leishmaniasis (CL) patient lesional biopsy test samples. Lanes: 1, 100 bp DNA ladder; 2, *L. donovani*; 3–10, CL patient samples from Himachal Pradesh. 6PGDH, 6-phosphogluconate dehydrogenase gene.



**Appendix Figure 6.** Systemic circulation of *L. donovani* in CL patients. A) Rapid Immunochromatographic rK39 dipstick test using serum samples from cutaneous leishmaniasis patients and visceral leishmaniasis patients used as positive controls for detection of circulatory *L. donovani* specific anti-rK39 antibody. The single and double band reflects negative and positive results respectively. B)

ITS1 *Leishmania* species-specific PCR on DNA from blood samples of specific ACL patients. ITS1-PCR product of ~320 bp in test samples and standard *L. donovani* positive control samples. Lanes: 1, *L. donovani* (positive control); 2, 50 bp DNA ladder; 3 to 8, CL test samples. *Hae*III PCR-RFLP analysis of ITS1. Lanes: 1, *L. donovani* (positive control); 2, 50 bp DNA ladder; 3 to 8, CL test samples.