

3. McVey DS, Drolet BS, Ruder MG, Wilson WC, Nayduch D, Pfannenstiel R, et al. Orbiviruses: a North American perspective. *Vector Borne Zoonotic Dis.* 2015;15:335–8. <http://dx.doi.org/10.1089/vbz.2014.1699>
4. Pybus MJ, Ravi M, Pollock C. Epizootic hemorrhagic disease in Alberta, Canada. *J Wildl Dis.* 2014;50:720–2. <http://dx.doi.org/10.7589/2014-02-024>
5. Howerth EW, Stallknecht DE, Kirkland PD. Bluetongue, epizootic hemorrhagic disease, and other orbivirus-related diseases. In: Williams ES, Barker IK, editors. *Infectious diseases of wild mammals.* Ames (IA): Iowa State University Press; 2001. p. 82–9.
6. Pasick J, Handel K, Zhou EM, Clavijo A, Coates J, Robinson Y, et al. Incursion of epizootic hemorrhagic disease into the Okanagan Valley, British Columbia in 1999. *Can Vet J.* 2001;42:207–9.
7. Wirth WW, Dyce AL, Peterson BV. An atlas of wing photographs with a summary of the numerical characters of the Nearctic species of *Culicoides* (Diptera: Ceratopogonidae). *Contrib Am Entomol Inst.* 1985;22:1–46.
8. Stallknecht DE, Allison AB, Park AW, Phillips JE, Goekjian VH, Nettles VF, et al. Apparent increase of reported hemorrhagic disease in the midwestern and northeastern USA. *J Wildl Dis.* 2015;51:348–61. <http://dx.doi.org/10.7589/2013-12-330>
9. Pfannenstiel RS, Mullens BA, Ruder MG, Zurek L, Cohnstaedt LW, Nayduch D. Management of North American *Culicoides* biting midges: current knowledge and research needs. *Vector Borne Zoonotic Dis.* 2015;15:374–84. <http://dx.doi.org/10.1089/vbz.2014.1705>
10. Jewiss-Gaines A, Barelli L, Hunter FF. First records of *Culicoides sonorensis* (Diptera: Ceratopogonidae), a known vector of bluetongue virus, in southern Ontario. *J Med Entomol.* 2017; 54:757–62.

Address for correspondence: Samantha E. Allen, University of Guelph, 50 Stone Rd E, Guelph, ON N1G 2W1, Canada; email: sallen02@uoguelph.ca

Effects of Political Instability in Venezuela on Malaria Resurgence at Ecuador–Peru Border, 2018

Robinson Jaramillo-Ochoa,¹ Rachel Sippy,¹ Daniel F. Farrell,¹ Cinthya Cueva-Aponte,¹ Efraín Beltrán-Ayala, Jose L. Gonzaga, Tania Ordoñez-León, Fernando A. Quintana, Sadie J. Ryan, Anna M. Stewart-Ibarra

Author affiliations: Ministerio de Salud Pública del Ecuador, Machala, Ecuador (R. Jaramillo-Ochoa, J.L. Gonzaga, T. Ordoñez-León); State University of New York Upstate Medical

University, Syracuse, New York, USA (R. Sippy, D.F. Farrell, C. Cueva-Aponte, A.M. Stewart-Ibarra); University of Florida, Gainesville, Florida, USA (R. Sippy, S.J. Ryan); Universidad Técnica, Machala (E. Beltrán-Ayala); Ministerio de Salud de Peru, Tumbes, Peru (F.A. Quintana)

DOI: <https://doi.org/10.3201/eid2504.181355>

Mass migration from Venezuela has increased malaria resurgence risk across South America. During 2018, migrants from Venezuela constituted 96% of imported malaria cases along the Ecuador–Peru border. *Plasmodium vivax* predominated (96%). Autochthonous malaria cases emerged in areas previously malaria-free. Heightened malaria control and a response to this humanitarian crisis are imperative.

Malaria is a vectorborne parasitic infection caused by *Plasmodium* spp. and transmitted by *Anopheles* mosquitoes, characterized by fever and hemolysis with chronic and fatal potential (1). Despite substantial strides toward elimination in the Americas, malaria remains a major concern; ≈975,700 cases occurred and 138 million persons were at risk in 2017 (2). Most malaria cases in South America occur in the Amazon region, and *P. vivax* is more common than *P. falciparum* (3).

P. vivax and *P. falciparum* malaria were historically endemic to the Ecuador–Peru coastal border region. During 1990–2012, a total of 62,000 malaria cases were reported from El Oro Province, Ecuador, and 85,605 from Tumbes Region, Peru (4). Through vector control and active case surveillance and response, malaria was eliminated from El Oro Province in 2011 and Tumbes Region in 2012 (4). However, malaria cases elsewhere in Ecuador increased from 378 in 2013 (5) to 1,279 in 2017 (6). Peru and other countries in the region also reported increased malaria in 2017, indicating a major risk for re-introduction to elimination areas (2). In 2017, Venezuela alone accounted for more than half of all malaria cases in the Americas (2).

The public health sector in Venezuela is struggling with infectious disease epidemics, including malaria (7), despite a historically successful malaria control program (3). The worsening social and economic crisis has led to large-scale migration from and within Venezuela. The shortage of antimalarial drugs and lax in-country control efforts have exacerbated the situation, affecting countries throughout South America (8). Many people from Venezuela are migrating through Colombia and Ecuador to reach Peru and the southern cone of South America, stopping at various locations along the way (Figure). We report a series of imported malaria cases in migrants from Venezuela and the first autochthonous cases of malaria in the Ecuador–Peru border region since local elimination.

¹These authors contributed equally to this article.

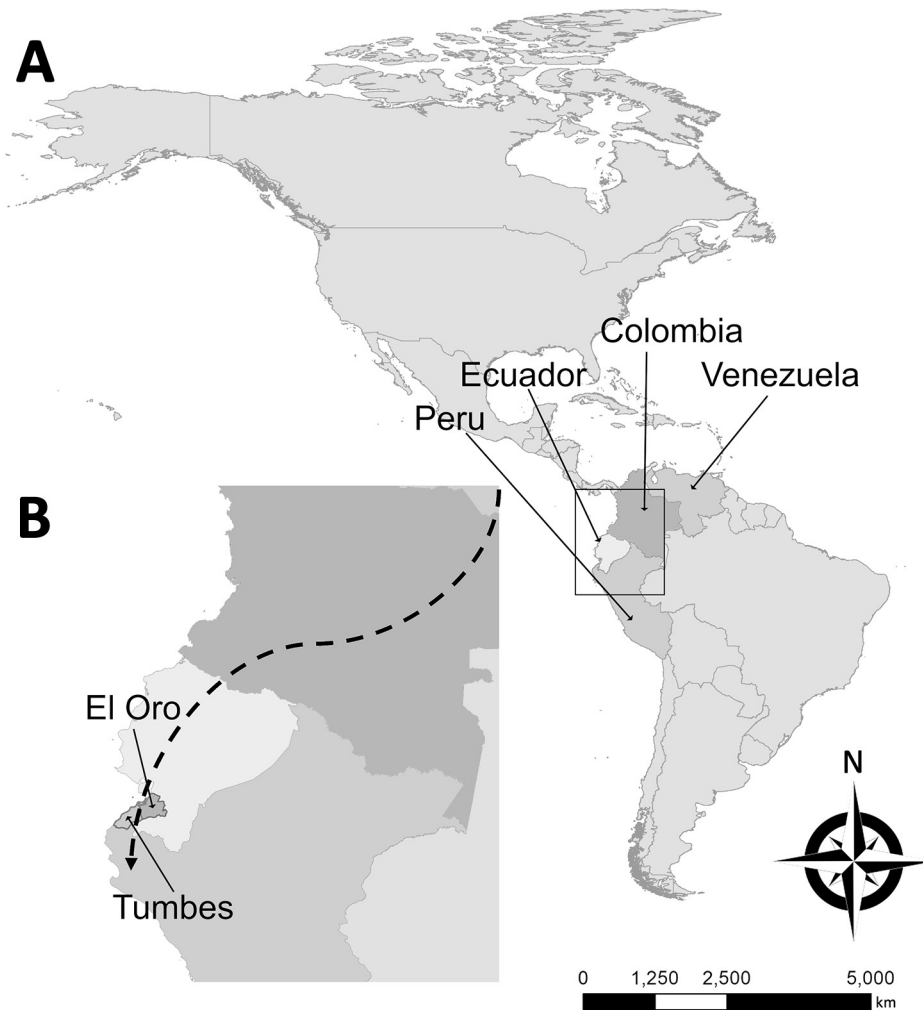


Figure. Probable migration route of imported malaria cases described in study of effects of political instability in Venezuela on malaria resurgence at the Ecuador–Peru border, 2018. A) Locations of the 4 countries along the migration route in South America; B) El Oro Province and Tumbes Region on the Ecuador–Peru border. The city of Huaquillas, Ecuador, is 70 km southwest of Machala, the location of the single autochthonous malaria case in this province. Huaquillas is the primary border crossing from Ecuador into Peru. Tumbes, the source of the 3 autochthonous cases in Peru, is the capital of Tumbes Region and is 22 km from the border. Dashed line in panel B broadly denotes the migration route taken from Venezuela through Colombia and Ecuador to Peru. Note the proximity of these countries and additional potential malarial resurgence through migration to Central America, the Caribbean, and the United States.

During February–November 2018, seven malaria cases (6 *P. vivax*, 1 *P. falciparum*) were detected in adults in El Oro Province and reported to the Ecuadorian Ministry of Health (Appendix, <https://wwwnc.cdc.gov/EID/article/25/4/18-1355-App1.pdf>). Five cases occurred in recent migrants from Venezuela, and 1 was imported from Peru. The most recent case (no. 7), reported in November 2018, was autochthonous. *Plasmodium* spp. infection was confirmed at the national reference laboratory in Guayaquil, Ecuador. Active surveillance within 1 km of each case-patient's residence revealed no acute cases, and collateral thick blood smears were negative. Entomologic teams documented *Aedes aegypti* and *Culex* spp. mosquitoes in the homes but no *Anopheles* mosquitoes. The residences all had basic infrastructure and no history of malaria since local elimination in 2011.

During May–October 2018, a total of 20 *P. vivax* malaria cases were detected in adults in Tumbes Region and reported to the Peruvian Ministry of Health (Appendix). Seventeen cases occurred in Venezuelan migrants now

living in the province, and 3 were autochthonous cases in persons residing in Tumbes. An epidemiologic investigation revealed that the autochthonous case-patients had no history of travel outside of Tumbes Region.

We cannot definitively state whether the migrants from Venezuela were exposed to malaria in Venezuela or during transit. Regardless, this population represents a highly vulnerable group with complex treatment issues. Malaria should be considered in the differential diagnosis for febrile patients from Venezuela and for local populations in nearby parts of South America. The transience of the migrant population presents treatment follow-up issues. The incubation period for *P. vivax* malaria is 12–18 days and, for *P. falciparum* malaria, 9–14 days. Case-patients (Appendix) often exhibited inadequately or untreated malaria. Imported cases are the likely source of the locally transmitted cases in Tumbes Region and El Oro Province because the primary mosquito vectors (*An. albimanus* and *An. punctimacula*) remain abundant in this area (9). Another concern is relapse of dormant *P. vivax* hypnozoites, which can occur up to

several years after initial infection (*I*). Issues with primaquine (i.e., *CYP2D6*-poor metabolizers or hemolysis risk in patients with glucose-6-phosphate dehydrogenase deficiency) complicate treatment of dormant hypnozoites that cause relapse (*I*). A new treatment, tafenoquine, which still causes hemolysis in glucose-6-phosphate dehydrogenase deficiency, was recently approved in the United States as a single dose for prevention of *P. vivax* malaria relapse (*10*), although this medication might not reach at-risk groups in South America. Ecuador and Peru currently follow the Pan American Health Organization guidelines regarding primaquine use (<https://www.paho.org/hq/dmdocuments/2011/TreatmentGuidelines-2nd-ed-2010-eng.pdf>).

Local ministries of health responded quickly to these cases and implemented case surveillance. However, reductions in resources after elimination of local malaria transmission in 2011–2012 severely limited malaria control efforts in Ecuador and Peru. Imported cases of malaria at the Ecuador–Peru border region pose a serious threat of continued resurgence in local transmission. We urge international solutions for Venezuela’s humanitarian crisis and augmentation of infectious disease surveillance and control along migration routes and in surrounding regions.

About the Author

Dr. Jaramillo-Ochoa is an epidemiologist working for the Ministry of Health for the Health District of the city of Machala, El Oro Province, Ecuador. His primary research interests include the epidemiology of vectorborne diseases and monitoring and evaluating vector-control interventions.

References

- Ashley EA, Pyae Phyo A, Woodrow CJ. Malaria. *Lancet*. 2018; 391:1608–21. [http://dx.doi.org/10.1016/S0140-6736\(18\)30324-6](http://dx.doi.org/10.1016/S0140-6736(18)30324-6)
- World Health Organization. World malaria report 2018. Geneva: The Organization; 2018.
- Recht J, Siqueira AM, Monteiro WM, Herrera SM, Herrera S, Lacerda MVG. Malaria in Brazil, Colombia, Peru and Venezuela: current challenges in malaria control and elimination. *Malar J*. 2017;16:273. <http://dx.doi.org/10.1186/s12936-017-1925-6>
- Krisner LK, Krisner J, Ambuludi M, Arichabala A, Beltrán-Ayala E, Navarrete P, et al. Successful malaria elimination in the Ecuador–Peru border region: epidemiology and lessons learned. *Malar J*. 2016;15:573. <http://dx.doi.org/10.1186/s12936-016-1630-x>
- World Health Organization. World malaria report 2014: Ecuador. Geneva: The Organization; 2014.
- Ministerio de Salud Pública de Ecuador. Gaceta Vectorial SE 1–52, 2017. 2018 Jan 3 [cited 2018 Apr 15]. <https://www.salud.gob.ec/wp-content/uploads/2017/07/Gaceta-Vectorial-SE52.pdf>
- Hotez PJ, Basañez MG, Acosta-Serrano A, Grillet ME. Venezuela and its rising vector-borne neglected diseases. *PLoS Negl Trop Dis*. 2017;11:e0005423. <http://dx.doi.org/10.1371/journal.pntd.0005423>
- Grillet ME, Villegas L, Oletta JF, Tami A, Conn JE. Malaria in Venezuela requires response. *Science*. 2018;359:528.
- Ryan SJ, Lippi CA, Boersch-Supan PH, Heydari N, Silva M, Adrian J, et al. Quantifying seasonal and diel variation in *Anopheles* and *Culex* human biting rates in southern Ecuador. *Malar J*. 2017;16:479. <http://dx.doi.org/10.1186/s12936-017-2121-4>
- Frampton JE. Tafenoquine: first global approval. *Drugs*. 2018;78:1517–23. <http://dx.doi.org/10.1007/s40265-018-0979-2>

Address for correspondence: Anna M. Stewart-Ibarra, Institute for Global Health & Translational Science, State University of New York Upstate Medical University, 505 Irving Ave, Syracuse, NY 13210, USA; email: stewart@upstate.edu

***Rickettsia parkeri* and *Candidatus Rickettsia andeanae* in Ticks of the *Amblyomma maculatum* Group, Mexico**

Jesús Delgado-de la Mora,¹
Sokani Sánchez-Montes,¹
Jesús D. Licona-Enríquez,¹
David Delgado-de la Mora,¹
Christopher D. Paddock, Lorenza Beati,
Pablo Colunga-Salas, Carmen Guzmán-Cornejo,
María L. Zambrano, Sandor E. Karpathy,
Andrés M. López-Pérez,
Gerardo Álvarez-Hernández

Author affiliations: Instituto Nacional de Ciencias Médicas y Nutrición Salvador Zubirán, Mexico City, Mexico (J. Delgado-de la Mora); Universidad Nacional Autónoma de México, Mexico City (S. Sánchez-Montes, P. Colunga-Salas, C. Guzmán-Cornejo, A.M. López-Pérez); Centro Médico Nacional Siglo XXI, Mexico City (J.D. Licona-Enríquez); Instituto Tecnológico de Sonora, Sonora, Mexico (D. Delgado-de la Mora); Centers for Disease Control and Prevention, Atlanta, Georgia, USA (C.D. Paddock, M.L. Zambrano, S.E. Karpathy); Georgia Southern University, Statesboro, Georgia, USA (L. Beati); Universidad de Sonora, Sonora (G. Álvarez-Hernández)

DOI: <https://doi.org/10.3201/eid2504.181507>

We report *Rickettsia parkeri* and *Candidatus Rickettsia andeanae* in ticks of the *Amblyomma maculatum* group collected from dogs in Sonora, Mexico. Molecular characterization of these bacteria was accomplished by DNA amplification and sequence analysis of portions of the rickettsial genes *gltA*, *htrA*, *ompA*, and *ompB*.

¹These authors contributed equally to this article.

Effects of Political Instability in Venezuela on Malaria Resurgence at Ecuador–Peru Border, 2018

Appendix

Clinical and Demographic Details for Malaria Cases from El Oro Province, Ecuador, and the Tumbes Region, Peru, in 2018

Case Descriptions: El Oro Province, Ecuador

Six cases of malaria were reported in El Oro Province from February to November 2018. Details are presented below and in Appendix Table 1.

Case 1: A 27-year-old woman from Venezuela, at 8 weeks' gestation, entered Ecuador in February 2018 with fever, chills, diaphoresis, and headache. She endorsed a prior history of incomplete treatment for *Plasmodium vivax* and *P. falciparum* on multiple occasions in Venezuela (Ciudad Bolívar). Thick blood smear revealed *P. vivax*. She received treatment with chloroquine, and subsequent thick blood smears (on days 7, 14, 21, 28) were negative. She continued with chloroquine preventive treatment until delivery.

Case 2: A 22-year-old man from Venezuela entered Ecuador in June 2018, with no prior history of malaria. His symptoms began 2 days after entry into Ecuador, and included fever, chills, diaphoresis, and headache. He was initially seen at an outpatient clinic and was prescribed amoxicillin and paracetamol. Six days later, he presented to a public hospital in the city of Machala, El Oro Province, Ecuador, with arthralgias, productive cough, and jaundice. While a cough is not usually thought of in malaria presentation, and in diagnosis, this has been reported in the literature (1). Diagnostic tests for dengue and leptospirosis were negative. Thick blood smear revealed *P. vivax*. He completed unspecified antimalarial treatment and follow-up thick blood smears (days 7, 14, 21, 28) were negative.

Case 3: A 41-year-old woman from Venezuela entered Ecuador in May 2018 with a past medical history of malaria on at least 16 occasions. She reported incomplete treatment due to lack of antimalarial medications in Venezuela and did not finish antimalarial treatment when *P. vivax* malaria was initially diagnosed in the city of Guayaquil, Ecuador (185 km north of Machala). She arrived in late July to the city of Machala, where *P. vivax* malaria was diagnosed again. She received treatment with chloroquine and primaquine for 7 days, and follow-up thick blood smears were negative. According to the Ecuadorean Ministry of Health team, she was treated an additional 14 days with primaquine to ensure killing of hypnozoites.

Case 4: A 51-year-old man entered Ecuador from the Peruvian Amazon (Canton Andoas) in August 2018 with fever, chills, and headache. He reported a history of malaria on 36 occasions. On August 22, *P. falciparum* malaria was diagnosed in Machala via thick blood smear. He was treated according to Pan American Health Organization guidelines (<https://www.paho.org/hq/dmdocuments/2011/TreatmentGuidelines-2nd-ed-2010-eng.pdf>).

Case 5: A 33-year-old man entered Ecuador in August 2018, having left Venezuela 10 days earlier. He had worked in the malaria-endemic Amazon region of Venezuela and had a history of malaria on at least 6 occasions. He reported treatment only with chloroquine in Venezuela. Symptoms (fever, chills, headache) began about 1 month after his arrival in Ecuador, and thick blood smear on September 17 showed *P. vivax*. He received unspecified antimalarial treatment. Follow-up thick blood smears (days 7,14,21, and 28) were negative.

Case 6: A 32-year-old man was diagnosed with *P. vivax* malaria in Venezuela (Bolívar state) 5 months prior, where he received treatment with chloroquine for 3 days and primaquine for 7 days. He left Venezuela in July 2018 and entered Ecuador 6 days later. His symptoms began in November of 2018, and included fever, chills, and headache. At that time, he presented twice to a health center in Machala, Ecuador, with unremarkable workup, including negative thick blood smears, and was treated symptomatically with paracetamol. One week later, he returned to the health center with jaundice, hepatosplenomegaly, and altered liver function test results. Thick blood smear

on November 14 showed *P. vivax*. He was treated with chloroquine and primaquine. Two of 4 follow-up thick blood smears (days 7, 14, 21, and 28) were negative. It was thought this was a relapse of *P. vivax* from liver hypnozoites; however, autochthonous transmission cannot be excluded.

Case 7: A 66-year-old man residing in the border city of Huaquillas in El Oro Province is thought to have the first autochthonous case of malaria in the province since 2011. The patient self-treated symptoms with paracetamol and sought medical care after 4 days with no improvement. A thick blood smear on November 28 revealed *P. vivax*, and the patient was treated with primaquine. Local control measures were implemented by the Ecuador Ministry of Health. No additional cases were found in the 1-km area around the patient's home.

Tumbes Region, Peru

Twenty cases of malaria were reported from May to November 2018 in the Tumbes Region, Peru (Appendix Table 2). Additional clinical details are unavailable at this time.

Reference

1. Anstey NM, Jacups SP, Cain T, Pearson T, Ziesing PJ, Fisher DA, et al. Pulmonary manifestations of uncomplicated *falciparum* and *vivax* malaria: cough, small airways obstruction, impaired gas transfer, and increased pulmonary phagocytic activity. *J Infect Dis.* 2002;185:1326–34. [PubMed http://dx.doi.org/10.1086/339885](http://dx.doi.org/10.1086/339885)

Appendix Table 1. Summary of malaria cases from El Oro Province, Ecuador, in 2018*

Case no.	Age, y/Sex	Origin	Pregnant	Month of entry to Ecuador, 2018	Symptoms	Month of diagnosis, 2018	History of malaria	Diagnosis	Follow-up
1	27/F	Venezuela	Yes	Feb	Fever, chills, diaphoresis, headache	February	Yes	<i>P. vivax</i>	Negative
2	22/M	Venezuela	NA	Jun	Fever, chills, diaphoresis, headache, arthralgias, productive cough, and jaundice	June	No	<i>P. vivax</i>	Negative
3	41/F	Venezuela	No	May	No details	July	Yes	<i>P. vivax</i>	Negative
4	51/M	Peru	NA	Aug	Fever, chills and headache	August	Yes	<i>P. falciparum</i>	Negative
5	33/M	Venezuela	NA	Aug	Fever, headache and chills	September	Yes	<i>P. vivax</i>	Negative
6	32/M	Venezuela	NA	Jul	Fever, headache and chills, jaundice, hepatosplenomegaly	November	Yes	<i>P. vivax</i>	Negative
7	66/M	Huaquillas	NA	Local resident	No details	November	Yes	<i>P. vivax</i>	Negative

*All cases were diagnosed by thick blood smear and received complete treatment. NA, not applicable.

Appendix Table 2. Summary of malaria cases from Tumbes Province, Peru, 2018*

Case no.	Age, y/sex	Origin	Symptoms	Date of diagnosis, 2018	Diagnosis
1	24/M	Venezuela	Fever, chills, diaphoresis, headache	May	<i>P. vivax</i>
2	59/M	Venezuela	Fever, chills, diaphoresis, headache	May	<i>P. vivax</i>
3	30/F	Venezuela	Fever, chills, diaphoresis, headache	Jun	<i>P. vivax</i>
4	53/F	Tumbes	Fever, chills, diaphoresis, headache	Jun	<i>P. vivax</i>
5	18/M	Venezuela	Fever, chills, diaphoresis, headache	Jul	<i>P. vivax</i>
6	20/F	Venezuela	Fever, chills, diaphoresis, headache	Jul	<i>P. vivax</i>
7	26/F	Venezuela	Fever, chills, diaphoresis, headache	Jul	<i>P. vivax</i>
8	22/M	Venezuela	Fever, chills, diaphoresis, headache	Jul	<i>P. vivax</i>
9	25/F	Venezuela	Fever, chills, diaphoresis, headache	Jul	<i>P. vivax</i>
10	35/M	Venezuela	Fever, chills, diaphoresis, headache	Jul	<i>P. vivax</i>
11	22/M	Venezuela	Fever, chills, diaphoresis, headache	Jul	<i>P. vivax</i>
12	48/F	Tumbes	Fever, chills, diaphoresis, headache	Jul	<i>P. vivax</i>
13	39/M	Venezuela	Fever, chills, diaphoresis, headache	Aug	<i>P. vivax</i>
14	21/M	Venezuela	Fever, chills, diaphoresis, headache	Aug	<i>P. vivax</i>
15	23/M	Venezuela	Fever, chills, diaphoresis, headache	Aug	<i>P. vivax</i>
16	18/M	Venezuela	Fever, chills, diaphoresis, headache	Aug	<i>P. vivax</i>
17	39/M	Venezuela	Fever, chills, diaphoresis, headache	Oct	<i>P. vivax</i>
18	22/M	Venezuela	Fever, chills, diaphoresis, headache	Nov	<i>P. vivax</i>
19	41/M	Venezuela	Fever, chills, diaphoresis, headache	Nov	<i>P. vivax</i>
20	35/F	Tumbes	Fever, chills, diaphoresis, headache	Nov	<i>P. vivax</i>

*Additional details unavailable.