

Capillaria Ova and Diagnosis of Trichuris trichiura Infection in Humans by Kato-Katz Smear, Liberia

Kerstin Fischer, Abakar Gankpala,
Lincoln Gankpala, Fatorma K. Bolay,
Kurt C. Curtis, Gary J. Weil, Peter U. Fischer

We examined human stool samples from Liberia for soil-transmitted helminth ova by Kato-Katz smear and by quantitative PCR. Twenty-five samples were positive for *Trichuris trichiura* by smear but negative by quantitative PCR. Reexamination of samples showed that they contained *Capillaria* eggs that resemble *T. trichiura* in Kato-Katz smears.

Kato-Katz smears are the most commonly used diagnostic tool for detecting and quantifying soil-transmitted helminth (STH) infections in field surveys (1). Although this method has some shortcomings, its advantages are field suitability and fast microscopic enumeration of worm eggs. Whereas sensitivity is low for light infections because of the small amount of stool examined (≈ 41 mg), the specificity of Kato-Katz for diagnosis of *Ascaris lumbricoides* and *Trichuris trichiura* infection is considered to be high (2). In contrast, hookworm eggs are difficult to differentiate by morphology, but quantitative PCR (qPCR) enables differentiation among *Necator americanus*, *Ancylostoma duodenale*, and *A. ceylanicum* eggs (3–5).

Among helminth eggs found in human feces, the barrel-shaped eggs of *T. trichiura* worms are considered to be characteristic, with a length of 50–55 μm , a width of 22–24 μm , and clearly protruding bipolar plugs (6). Similar eggs of other members of the *Trichiuridae* family may be differentiated from *T. trichiura* eggs by size and morphology when observed at high magnification, but these eggs have rarely been found in human fecal samples (7–9). Therefore, the presence of eggs of zoonotic members of the *Trichiuridae* family is generally not considered a confounder for detecting *T. trichiura* by Kato-Katz smear.

Author affiliations: Washington University School of Medicine, St. Louis, Missouri, USA (K. Fischer, K.C. Curtis, G.J. Weil, P.U. Fischer); National Public Health Institute of Liberia, Charlesville, Liberia (A. Gankpala, L. Gankpala, F.K. Bolay)

DOI: <https://doi.org/10.3201/eid2408.180184>

The Study

To assess the effect of mass drug administration using ivermectin and albendazole for the elimination of lymphatic filariasis on STH prevalence and intensity, we collected stool samples over a period of 3 years in 2 different areas in Foya district (Lofa County) in northwestern Liberia and in Harper district (Maryland County) in southeastern Liberia (10). We examined a single stool sample per subject by microscopy (magnification $\times 100$) with duplicate Kato-Katz smears (41-mg template). We preserved aliquots of randomly selected specimens on FTA cards (GE Healthcare, Little Chalfont, UK) or in RNAlater (ThermoFisher, Waltham, MA, USA) and shipped them to Washington University School of Medicine (St. Louis, MO, USA) for analysis by qPCR. Two experienced microscopists (L.G., A.T. Momolu) examined the samples by Kato-Katz smear in both study areas. For detection of STH by qPCR, we extracted DNA from ≈ 100 mg of stool and tested it as described by Pilotte et al. (5) with a Quantstudio 6 Flex Thermocycler (Applied Biosystems, Carlsbad, CA, USA) and TaqMan Fast Advanced Mastermix (Applied Biosystems). We used the following primers and probes to detect *Schistosoma mansoni* DNA: forward primer 5'-TGTGGGAGTCTTTGGTTGTT-3', reverse primer 5'-CAACATGACTGGGAA-CAGGA-3', probe 5'-AGGTTTCAGGTGG/ZEN/GTGTGTTACGAA-31ABkFQ-3'.

We tested 353 stool samples from Foya district by Kato-Katz smear; 31 (8.8%) were positive for *A. lumbricoides* eggs, 231 (65.4%) for hookworm eggs, 27 (7.6%) for *T. trichiura*-like eggs, and 276 (78.2%) for *S. mansoni* eggs. We tested 225 samples from Harper district by Kato-Katz smear; 163 (72.4%) were positive for *A. lumbricoides* eggs, 65 (28.9%) for hookworm eggs, and 51 (22.7%) for *T. trichiura* eggs (Table 1). There was good agreement between the results of the Kato-Katz and qPCR tests for the specimens from Harper (80.5%–91.6%), but generally qPCR had higher sensitivity. Our results were consistent with results previously reported with samples from other areas (3,11). Agreement between the 2 diagnostic tests for samples from Foya ranged from 77.3% to 92.9%, but the sensitivity of the qPCR was unexpectedly low, a finding that was especially true for *Ascaris* and *Trichuris* infection (Table 1). Whereas samples positive for *Ascaris* by Kato-Katz but negative by qPCR had low egg counts, samples positive for *Trichuris* by Kato-Katz

Table 1. Comparison of sensitivity of Kato-Katz smear and quantitative PCR results for 778 stool samples tested for soil-transmitted helminths, Foya and Harper districts, Liberia

Site and species	No. positive*	Kato-Katz smear sensitivity, %	qPCR sensitivity, %	McNemar p value
Foya district, n = 353				
<i>Ascaris lumbricoides</i>	34	91.2	17.6	<0.0001
Hookworm†	247	93.5	83.4	<0.0001
<i>Trichuris trichiura</i>	27	100	7.4	<0.0001
<i>Schistosoma mansoni</i>	307	89.9	84.0	0.0573
Harper district, n = 225				
<i>A. lumbricoides</i>	180	90.6	98.9	0.0013
Hookworm†	99	65.7	89.9	0.0005
<i>T. trichiura</i>	86	59.3	94.2	0.0001

*Samples that tested positive by either method.

†Hookworm was *Necator americanus*. No *Ancylostoma duodenale* was detected.

but negative by qPCR had higher counts; 7 samples contained $\geq 1,000$ barrel-shaped eggs/g of stool (Table 2). We repeated DNA extraction and qPCR and also used an alternative qPCR for *T. trichiura* (3), but these tests did not improve the agreement between microscopy and qPCR results.

To check further whether Kato-Katz-positive, qPCR-negative stool samples contained *T. trichiura* eggs, we examined direct smears of stool samples preserved in RNA later by microscopy (magnification $\times 100$ and $\times 400$) (Figure 1). The samples positive by qPCR contained eggs (6 measured) with typical *T. trichiura* morphology; these eggs had a mean (\pm SD) length of 52 μm (± 2.4 μm) and width of 25.5 μm (± 1.3 μm). In contrast, qPCR-negative samples contained eggs (31 measured) with a mean (\pm SD) length of 51.8 μm (± 1.5 μm)

and width of 32.7 μm (± 2.1 μm). The qPCR-negative samples also had less pronounced plugs and a thick, striated shell, features that are consistent with eggs of *Capillaria hepatica* (syn. *Calodium hepaticum*) and some other *Capillaria* species (*Trichuridae*). Eggs of *C. philippinensis* or *C. aerophila* that have been observed in human stool samples previously were either smaller or larger than the *Capillaria* eggs found in Lofa (12,13). Because polar plugs of these eggs are less prominent than those of *T. trichiura*, and because their shapes are sometimes more oval or round, they can also be confused with *A. lumbricoides* eggs by low-power microscopy, especially if only a few eggs were detected (Figure 1).

Members of the subfamily *Capillariidae* are animal parasites with somewhat divergent life cycles, and most

Table 2. Demographics and Kato-Katz and qPCR results for patients positive for *Trichuris trichiura* infection by microscopy, Liberia*

Year	Demographics			Microscopy, epg				qPCR, cycle threshold				
	Patient no.	Age, y/sex	Village	Tt	Al	Hk	Sm	Tt	Al	Na	Sm	
2014	P320529	45/F	Yallahun	576	0	360	24	Neg	Neg	31.7	30.5	
	P320683	35/F	Kpombu	12	0	0	0	Neg	Neg	Neg	28.4	
	P320695	16/M	Kpombu	24	0	0	72	Neg	Neg	Neg	23.8	
	P320620	15/M	Foya-Dunddu	12	120	0	288	Neg	Neg	32.2	23.5	
	P320746	9/F	Bandenin	24	0	0	0	Neg	Neg	Neg	26.51	
	P320452	7/F	Felaloe	12	0	0	120	Neg	Neg	Neg	23.9	
	P320596	6/F	Foya-Dunddu	12	0	0	90	Neg	Neg	Neg	27.6	
	P320656	6/F	Kpombu	120	0	0	504	Neg	Neg	Neg	21.3	
2016	P331772	36/M	Kpombu	3,048	0	12	24	Neg	Neg	Neg	Neg	
	P331921	35/M	Felaloe	60	0	0	12	Neg	Neg	Neg	Neg	
	P331783	34/F	Kpombu	420	0	0	0	Neg	Neg	Neg	Neg	
	P330724	26/M	Keyabendu	4,224	0	0	456	Neg	Neg	Neg	30.4	
	P331791	6/F	Kpombu	12	0	156	12	Neg	Neg	33.1	33.4	
	P331962	6/F	Bandenin	12	0	0	168	Neg	Neg	Neg	29.6	
	P331983	6/F	Bandenin	36	0	0	5,304	Neg	Neg	Neg	28.1	
	2017	P341287	61/M	Mendikorma	1,464	0	0	0	Neg	Neg	Neg	33.1
P341282		56/M	Mendikorma	540	0	216	0	Neg	Neg	28.3	Neg	
P341284		50/M	Mendikorma	60	0	0	132	Neg	Neg	Neg	Neg	
P342148		45/M	Keyabendu	1,368	0	0	192	Neg	Neg	34.5	Neg	
P340246		39/M	Kamatahun	120	0	0	216	Neg	Neg	Neg	30.0	
P340307		19/F	Bambuloe	2,028	0	0	1,188	Neg	Neg	Neg	24.1	
P340133		12/M	Fokolahun	1,020	16,392	0	0	25.3	16.7	Neg	Neg	
P340183		9/F	Kpelloe	72	0	0	0	Neg	Neg	Neg	36.0	
			Ndama									
P341308		9/F	Mendikorma	36	0	108	0	Neg	Neg	Neg	28.5	
P341326		9/M	Mendikorma	456	0	0	0	Neg	Neg	26.5	30.4	
P341327		6/M	Mendikorma	2,076	0	0	0	Neg	Neg	Neg	Neg	
P340147	5/M	Fokolahun	48	0	0	0	30.94	26.93	Neg	Neg		

**T. trichiura* infection was confirmed by qPCR in only 2 patients, but 25 had *Capillaria* eggs in their stool. Al, *Ascaris lumbricoides*; epg, eggs per gram of stool; Hk, hookworm; Na, *Necator americanus*; Neg, negative; Sm, *Schistosoma mansoni*; Tt, *T. trichiura*.

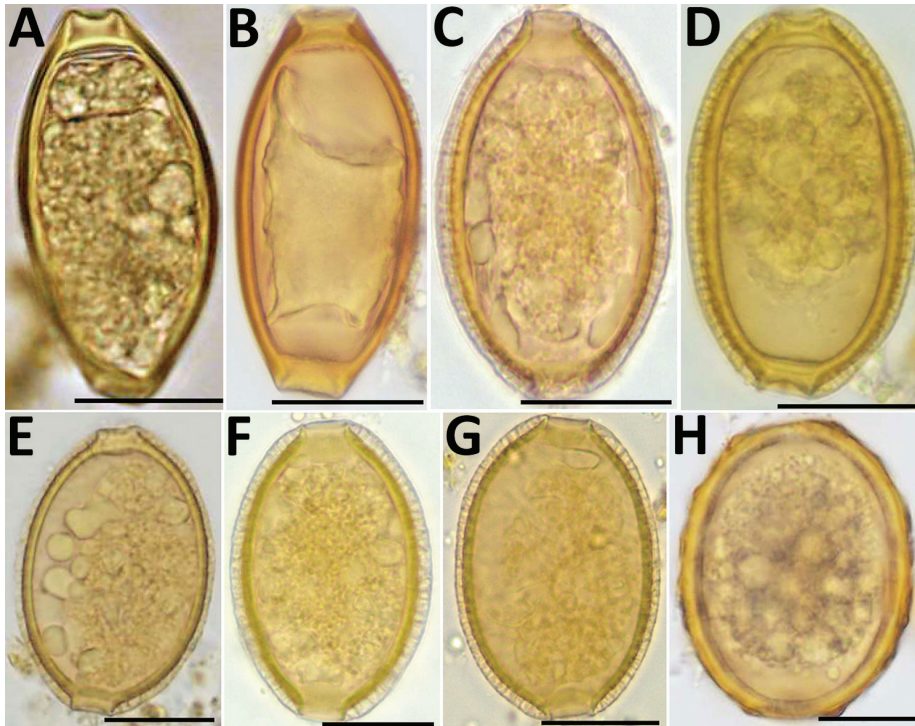


Figure. Helminth eggs found in stool samples from persons in Lofa County, Liberia. A, B) Eggs of *Trichuris trichiura* in samples positive for *T. trichiura* by Kato-Katz smear and by qPCR. C–F) Eggs of *Capillaria* spp. in samples positive for *T. trichiura* by Kato-Katz smear but negative for *T. trichiura* by qPCR. G) Egg of *Capillaria* spp. in sample positive for *Ascaris lumbricoides* by Kato-Katz smear but negative for *A. lumbricoides* by qPCR. H) Egg of *A. lumbricoides* in sample positive for *A. lumbricoides* by Kato-Katz smear and qPCR. Scale bars indicate 20 μ m. qPCR, quantitative PCR.

do not infect humans. Pseudoinfections with *C. hepatica* occur; eggs found in stool are present because they were consumed in infected animal liver. However, actual infections with *C. hepatica* do not lead to the passing of eggs in stool (9). Other species such as *C. philippinensis* cause true infections (and autoinfection) with eggs found in stool; the infection is linked to consumption of raw fish. Human capillariasis has not been reported from Liberia, and only isolated case reports have been published from sub-Saharan Africa (7–9). We performed DNA sequencing to better characterize the *Capillaria* species found in Foya. Using the primers Kt875351.1 (5'-CCCTAGTTGCGACTTTAAACGA-3') and *Capillaria* 18S1R (5'-TCCACCAACTAAGAACGGCC-3'), we were able to amplify and sequence a 288-bp portion of the 18S rDNA from *T. trichiura* qPCR-negative samples that contained only eggs morphologically identified as *Capillaria* spp. (GenBank accession no. MG859285). The DNA fragment was 100% identical to orthologs of *C. hepatica* (accession no. MF287972.1), *Aonchotheca putorii* (*C. putorii*) (accession no. LC052356.2), and *Pearsonema plica* (*C. plica*) (accession no. MF621034.1), *Capillaria* worm species that have varying life cycles and host species but that are only 95% identical to the ortholog of *T. trichiura*.

The life cycle and the medical importance of the *Capillaria* species found in humans in northwestern Liberia remain to be elucidated. In our study some subjects showed high *Capillaria* egg loads that may indicate a true infection rather than pseudoinfection. However, transient high egg

counts have been reported in persons with pseudoinfections (7). Whereas consumption of bush meat in Foya is common, consumption of raw or undercooked fish, which is necessary for transmission of *C. philippinensis*, is rare.

Conclusions

This study shows that *Capillaria* eggs similar to those of *C. hepatica* are not uncommon in stool samples collected in Liberia. These eggs can be misidentified by Kato-Katz smear as *T. trichiura* or as *A. lumbricoides*, which can confound results of STH surveys. The misidentification can also lead to an incorrect assumption that antihelminthic treatment was ineffective. Our results also illustrate the value of qPCR for validating Kato-Katz test results and for explaining unexpected findings.

Acknowledgments

We thank Emanuel B. Gray and Aaron T. Momolu for their expert help during field work, as well as Laura Rinaldi and Giuseppe Cringoli for their advice concerning animal *Capillaria* species.

The study was funded in part by grant GH5341 from the Bill & Melinda Gates Foundation.

About the Author

Ms. Fischer is a medical technician and staff scientist at the Division of Infectious Diseases, Department of Medicine, Washington University School of Medicine, St. Louis, Missouri, USA. For the last 20 years, her research has focused on medical helminthology and tropical medicine.

References

1. World Health Organization. Prevention and control of schistosomiasis and soil-transmitted helminthiasis. WHO Technical Report Series No. 912. Geneva: The Organization; 2002.
2. Speich B, Ali SM, Ame SM, Albonico M, Utzinger J, Keiser J. Quality control in the diagnosis of *Trichuris trichiura* and *Ascaris lumbricoides* using the Kato-Katz technique: experience from three randomised controlled trials. *Parasit Vectors*. 2015;8:82. <http://dx.doi.org/10.1186/s13071-015-0702-z>
3. Mejia R, Vicuña Y, Broncano N, Sandoval C, Vaca M, Chico M, et al. A novel, multi-parallel, real-time polymerase chain reaction approach for eight gastrointestinal parasites provides improved diagnostic capabilities to resource-limited at-risk populations. *Am J Trop Med Hyg*. 2013;88:1041–7. <http://dx.doi.org/10.4269/ajtmh.12-0726>
4. Papaïakovou M, Pilotte N, Grant JR, Traub RJ, Llewellyn S, McCarthy JS, et al. A novel, species-specific, real-time PCR assay for the detection of the emerging zoonotic parasite *Ancylostoma ceylanicum* in human stool. *PLoS Negl Trop Dis*. 2017;11:e0005734. <http://dx.doi.org/10.1371/journal.pntd.0005734>
5. Pilotte N, Papaïakovou M, Grant JR, Bierwert LA, Llewellyn S, McCarthy JS, et al. Improved PCR-based detection of soil transmitted helminth infections using a next-generation sequencing approach to assay design. *PLoS Negl Trop Dis*. 2016;10:e0004578. <http://dx.doi.org/10.1371/journal.pntd.0004578>
6. World Health Organization. Training manual on the diagnosis of intestinal parasites based on the WHO bench aids for diagnosis of intestinal parasites. Geneva: The Organization; 2004. p. 1–48.
7. Cabada MM, Lopez M, White AC Jr. *Capillaria hepatica* pseudoinfection. *Am J Trop Med Hyg*. 2013;89:609. <http://dx.doi.org/10.4269/ajtmh.13-0126>
8. El-Dib NA, El-Badry AA, Ta-Tang TH, Rubio JM. Molecular detection of *Capillaria philippinensis*: An emerging zoonosis in Egypt. *Exp Parasitol*. 2015;154:127–33. <http://dx.doi.org/10.1016/j.exppara.2015.04.011>
9. Fuehrer HP, Igel P, Auer H. *Capillaria hepatica* in man—an overview of hepatic capillariasis and spurious infections. *Parasitol Res*. 2011;109:969–79. <http://dx.doi.org/10.1007/s00436-011-2494-1>
10. Chesnais CB, Awaca-Uvon NP, Bolay FK, Boussinesq M, Fischer PU, Gankpala L, et al. A multi-center field study of two point-of-care tests for circulating *Wuchereria bancrofti* antigenemia in Africa. *PLoS Negl Trop Dis*. 2017;11:e0005703. <http://dx.doi.org/10.1371/journal.pntd.0005703>
11. Easton AV, Oliveira RG, O'Connell EM, Kepha S, Mwandawiro CS, Njenga SM, et al. Multi-parallel qPCR provides increased sensitivity and diagnostic breadth for gastrointestinal parasites of humans: field-based inferences on the impact of mass deworming. *Parasit Vectors*. 2016;9:38. <http://dx.doi.org/10.1186/s13071-016-1314-y>
12. Attia RAH, Tolba MEM, Yones DA, Bakir HY, Eldeek HE, Kamel S. *Capillaria philippinensis* in Upper Egypt: has it become endemic? *Am J Trop Med Hyg*. 2012;86:126–33. <http://dx.doi.org/10.4269/ajtmh.2012.11-0321>
13. Di Cesare A, Castagna G, Meloni S, Otranto D, Traversa D. Mixed trichuroid infestation in a dog from Italy. *Parasit Vectors*. 2012;5:128. <http://dx.doi.org/10.1186/1756-3305-5-128>

Address for correspondence: Peter U. Fischer, Washington University School of Medicine—Infectious Diseases Division, Department of Medicine, 4444 Forest Park Blvd, St. Louis, MO 63108, USA; email: Pufischer@wustl.edu

EID Podcast: Deadly Parasite in Raccoon Eggs



Infection with *Baylisascaris procyonis* roundworms is rare but often fatal and typically affects children.

Baylisascaris procyonis, the common intestinal roundworm of raccoons, has increasingly been recognized as a source of severe, often fatal, neurologic disease in humans, particularly children. Although this devastating disease is rare, lack of effective treatment and the widespread distribution of raccoons in close association with humans make baylisascariasis a disease that seriously affects public health. Raccoons infected with *B. procyonis* roundworms can shed millions of eggs in their feces daily. Given the habit of raccoons to defecate in and around houses, information about optimal methods to inactivate *B. procyonis* eggs are critical for the control of this disease. However, little information is available about survival of eggs and effective disinfection techniques. Additional data provide information on thermal death point and determining the impact of desiccation and freezing on the viability of *B. procyonis* eggs to provide additional information for risk assessments of contamination and guide attempts at environmental decontamination.

Visit our website to listen:

<https://www2c.cdc.gov/podcasts/player.asp?f=8620675>

EMERGING INFECTIOUS DISEASES