

penguins harbor multiple avulaviruses. An important limitation is that the new viruses were not tested serologically against APMV-4 through APMV-13; however, genetic and antigenic differences between the new viruses support the idea that they are new species.

These data suggest that in Antarctica a much greater diversity of avulaviruses exists than previously recognized. Therefore, additional studies to evaluate the presence of these new viruses in other birds in Antarctica are needed to better understand the ecology and transmission of avulaviruses in this pristine environment.

Acknowledgments

We thank the staff of Instituto Antártico Chileno for all their support during the expeditions to Antarctica, the Instituto de Salud Pública de Chile for biologic supplies, and The Chilean Navy and Antarctica XXI for assistance during field trips. We are grateful to Daniela Jiménez and Juan Mena for technical assistance. Sagar Goyal provided cell lines and APMV-1, APMV-2 and APMV-3 reference antisera.

This study is supported by the grants INACH RT46-16, RT12-13, CONICYT-PIA ANILLO ACT 1408, and FONDECYT 3150564, 11130305, 3150617, and 11160852.

Dr. Neira is assistant professor at the Animal Virology Unit, Facultad de Ciencias Veterinarias y Pecuarias, Universidad de Chile in Santiago. His research interests include understanding the diversity, transmission, and ecology of emerging and reemerging viruses in wildlife and livestock animals.

References

- Afonso CL, Amarasinghe GK, Bányai K, Bào Y, Basler CF, Bavari S, et al. Taxonomy of the order *Mononegavirales*: update 2016. *Arch Virol*. 2016;161:2351–60. <http://dx.doi.org/10.1007/s00705-016-2880-1>
- Karamendin K, Kydrymanov A, Seidalina A, Asanova S, Sayatov M, Kasymbekov E, et al. Complete genome sequence of a novel avian paramyxovirus (APMV-13) isolated from a wild bird in Kazakhstan. *Genome Announc*. 2016;4:e00167–16. <http://dx.doi.org/10.1128/genomeA.00167-16>
- Thampaisarn R, Bui VN, Trinh DQ, Nagai M, Mizutani T, Omatsu T, et al. Characterization of avian paramyxovirus serotype 14, a novel serotype, isolated from a duck fecal sample in Japan. *Virus Res*. 2017;228:46–57. <http://dx.doi.org/10.1016/j.virusres.2016.11.018>
- Miller PJ, Afonso CL, Spackman E, Scott MA, Pedersen JC, Senne DA, et al. Evidence for a new avian paramyxovirus serotype 10 detected in rockhopper penguins from the Falkland Islands. *J Virol*. 2010;84:11496–504. <http://dx.doi.org/10.1128/JVI.00822-10>
- Briand F-X, Henry A, Massin P, Jestin V. Complete genome sequence of a novel avian paramyxovirus. *J Virol*. 2012;86:7710. <http://dx.doi.org/10.1128/JVI.00946-12>
- Goraichuk I, Sharma P, Stegny B, Muzyka D, Pantin-Jackwood MJ, Gerilovych A, et al. Complete genome sequence of an avian paramyxovirus representative of putative new serotype 13. *Genome Announc*. 2016;4:e00729–16. <http://dx.doi.org/10.1128/genomeA.00729-16>
- Alexander DJ. Newcastle disease and other avian paramyxoviruses. *Rev Sci Tech*. 2000;19:443–62. <http://dx.doi.org/10.20506/rst.19.2.1231>
- Thomazelli LM, Araujo J, Oliveira DB, Sanfilippo L, Ferreira CS, Brentano L, et al. Newcastle disease virus in penguins from King George Island on the Antarctic region. *Vet Microbiol*. 2010;146:155–60. <http://dx.doi.org/10.1016/j.vetmic.2010.05.006>
- van Boheemen S, Bestebroer TM, Verhagen JH, Osterhaus ADME, Pas SD, Herfst S, et al. A family-wide RT-PCR assay for detection of paramyxoviruses and application to a large-scale surveillance study. *PLoS One*. 2012;7:e34961. <http://dx.doi.org/10.1371/journal.pone.0034961>
- Dill JA, Camus AC, Leary JH, Di Giallonardo F, Holmes EC, Ng TF. Distinct viral lineages from fish and amphibians reveal the 2 complex evolutionary history of hepadnaviruses. *J Virol*. 2016;90:7920–33. <http://dx.doi.org/10.1128/JVI.00832-16>

Address for correspondence: Victor Neira, Animal Virology Unit, Facultad de Ciencias Veterinarias y Pecuarias, Universidad de Chile, 11735 Santa Rosa, Santiago, Chile; email: victorneira@u.uchile.cl; Daniel Gonzalez Acuña, Zoology and Wildlife Laboratory, Facultad de Ciencias Veterinarias, Universidad de Concepción, 595 Vicente Méndez, Chillán, Chile; email: danigonz@udec.cl

***Rickettsia sibirica mongolitimonae* Infection, Turkey, 2016**

Ferit Kuscu, Omer Orkun, Aslihan Ulu, Behice Kurtaran, Suheyra Komur, A. Seza Inal, Damla Erdogan, Yesim Tasova, Hasan S.Z. Aksu

Author affiliations: Cukurova University Faculty of Medicine, Adana, Turkey (F. Kuscu, A. Ulu, B. Kurtaran, S. Komur, A. Seza Inal, D. Erdogan, Y. Tasova, H.S.Z. Aksu); Ankara University Faculty of Veterinary Medicine, Ankara, Turkey (O. Orkun)

DOI: <https://dx.doi.org/10.3201/eid2307.170188>

In 2016, *Rickettsia sibirica mongolitimonae* was diagnosed for a man in Turkey. He had been bitten by a *Hyalomma marginatum* tick, from which PCR detected rickettsial DNA. Sequence analysis of the DNA identified *R. sibirica mongolitimonae*. Immunofluorescence assay of patient serum indicated *R. conorii*, which cross-reacts. PCR is recommended for rickettsiosis diagnoses.

The first case of human infection with *Rickettsia sibirica mongolitimonae* was reported in France in 1996 (1). The infection is called lymphangitis-associated rickettsiosis

because of the lymphadenopathy and lymphangitis that occur with this infection but not with other spotted fever group rickettsioses (2). We describe a case of *R. sibirica mongolitimonae* infection with no lymphadenopathy and lymphangitis.

On May 1, 2016, a 53-year-old man was admitted to an emergency department in Adana, Turkey, for fever, headache, and maculopapular rash. He reported that 1 week earlier he had removed a tick from his umbilicus while farming in Adana, in the Mediterranean region of Turkey. He stored the tick in a glass jar and 2 days later sought care for high fever from his family doctor; administration of cefdinir produced no improvement. Four days later, he was hospitalized for fever (39°C), nausea, and malaise. Physical examination detected maculopapular rash and a black necrotic eschar at the center of an erythematous lesion on the patient's umbilicus (online Technical Appendix Figure, panel A, <https://wwwnc.cdc.gov/EID/article/23/7/17-0188-Techapp1.pdf>). The patient had no sign of lymphadenomegaly or lymphangitis. Initial laboratory examination of serum showed 10.1×10^9 leukocytes/L, 221×10^9 thrombocytes/L, 13 g/dL hemoglobin, and 3.74 mg/dL C-reactive protein (reference range <0.5 mg/dL). A blood sample was sent to the National Microbiology Reference Laboratory in Ankara, Turkey. Doxycycline (100 mg 2×/d) was administered for suspected rickettsial disease. After 48 hours, the patient's fever resolved, and his condition rapidly improved. He was discharged on day 5 of hospitalization, and doxycycline was stopped on day 10 after initiation.

Immunofluorescence assay of serum for typhus group rickettsiae IgM and IgG produced negative results. At the time of hospital admission, *R. conorii* IgM and IgG titers were 1:48 and 1:320, respectively. At a 1-month follow-up visit to the outpatient clinic, the patient's *R. conorii* IgM and IgG titers had increased to 1:384 and 1:640, respectively.

The removed tick, provided by the patient, was stored in 70% ethanol and sent to the Protozoology and Entomology Laboratory of Ankara University Faculty of Veterinary Medicine for identification of the tick species and PCR (online Technical Appendix Figure, panel B). Use of the morphological keys of Apanaskevich and Horak (3) led to tick identification as a *Hyalomma marginatum* female. DNA was extracted from the whole tick as described by Orkun et al. (4). Rickettsial DNA was detected by PCR with primers Rr. 190.70 and Rr. 190.701, which amplify the outer membrane protein A gene (*ompA*) of *Rickettsia* spp. (5). PCR and sequencing were conducted as described by Orkun et al. (4). The obtained nucleotide sequence was compared with sequences in the GenBank database, obtained by nucleotide sequence homology searches performed by BLAST analysis (<http://www.ncbi.nlm.nih.gov/BLAST>). The gene sequence obtained in

this study has been deposited in GenBank (accession no. KY513920).

PCR detected rickettsial DNA in the tick removed from the patient, and after sequence analysis, we determined that the rickettsial DNA belonged to *R. sibirica mongolitimonae*. According to nucleotide BLAST analysis, the obtained isolate is 100% similar to the reference strain *R. sibirica* subsp. *mongolitimonae* HA-91 (GenBank accession no. U43796) and *R. sibirica* subsp. *mongolitimonae* Bpy1 (GenBank accession no. KT345980) obtained from a biopsy sample from a human patient in Spain.

Although the climate and geography of cities like Adana in the Mediterranean region of Turkey are suitable for agents of Mediterranean spotted fever, we are unaware of any confirmed cases of *R. conorii* infection in this region. One reason may be limited access to diagnostic tools for rickettsial diseases. Another may be that doxycycline, the most effective treatment option for all rickettsial diseases (6), is easily administered for suspected cases of rickettsiosis with no differential diagnosis.

In Europe, *R. sibirica mongolitimonae* was detected in *Hyalomma excavatum* ticks in Greece and Cyprus; in *Rhipicephalus pusillus* ticks in France, Portugal, and Spain; and in *Rhipicephalus bursa* ticks in Spain (6). In 2016, *R. sibirica mongolitimonae* was isolated from 2 *H. marginatum* ticks in the central Anatolian region of Turkey (7).

Nearly 35% of patients with *R. sibirica mongolitimonae* infection experience rope-like lymphangitis and other highly specific manifestations (8). The eschar on the patient reported here was located below the umbilicus, and he had no sign of inguinal lymphadenopathy or lymphangitis on the abdominal wall.

The best sample to use for detection of spotted fever group rickettsiae is skin biopsied from the inoculation eschar (9). We did not perform a biopsy because we had the vector tick removed from the eschar. Also helpful for rickettsiosis investigations are serologic analyses by immunofluorescence assay. In our laboratory, only *R. conorii* serologic tests are performed for spotted fever group rickettsiae; for the patient reported here, these test results were positive for *R. conorii*. However, cross-reactions are common among *Rickettsia* spp. in the spotted fever and typhus groups (10), and cross-reactions on serologic tests should be considered. Whenever possible, PCRs should be performed for rickettsiosis diagnoses.

Mr. Kuscü works at the Cukurova University Faculty of Medicine as an infectious diseases and clinical microbiology specialist. His primary research interests are zoonoses and vectorborne diseases such as Crimean-Congo hemorrhagic fever and sandfly fever.

References

1. Raoult D, Brouqui P, Roux V. A new spotted-fever-group rickettsiosis. *Lancet*. 1996;348:412. [http://dx.doi.org/10.1016/S0140-6736\(05\)65037-4](http://dx.doi.org/10.1016/S0140-6736(05)65037-4)
2. Fournier PE, Gouriet F, Brouqui P, Lucht F, Raoult D. Lymphangitis-associated rickettsiosis, a new rickettsiosis caused by *Rickettsia sibirica mongolotimonae*: seven new cases and review of the literature. *Clin Infect Dis*. 2005;40:1435–44. <http://dx.doi.org/10.1086/429625>
3. Apanaskevich DA, Horak IG. The genus *Hyalomma* Koch, 1844: V. Re-evaluation of the taxonomic rank of taxa comprising the *H. (Euhyalomma) marginatum* Koch complex of species (Acari: Ixodidae) with redescription of all parasitic stages and notes on biology. *International Journal of Acarology*. 2008;34:13–42. <http://dx.doi.org/10.1080/01647950808683704>
4. Orkun Ö, Karaer Z, Çakmak A, Nalbantoğlu S. Spotted fever group rickettsiae in ticks in Turkey. *Ticks Tick Borne Dis*. 2014;5:213–8. <http://dx.doi.org/10.1016/j.ttbdis.2012.11.018>
5. Fournier PE, Roux V, Raoult D. Phylogenetic analysis of spotted fever group rickettsiae by study of the outer surface protein rOmpA. *Int J Syst Bacteriol*. 1998;48:839–49. <http://dx.doi.org/10.1099/00207713-48-3-839>
6. Parola P, Paddock CD, Socolovschi C, Labruna MB, Mediannikov O, Kernif T, et al. Update on tick-borne rickettsioses around the world: a geographic approach. *Clin Microbiol Rev*. 2013;26:657–702. <http://dx.doi.org/10.1128/CMR.00032-13>
7. Keskin A, Bursalı A. Detection of *Rickettsia aeschlimannii* and *Rickettsia sibirica mongolotimonae* in *Hyalomma marginatum* (Acari: Ixodidae) ticks from Turkey. *Acarologia*. 2016;56:533–6. <http://dx.doi.org/10.1051/acarologia/20164140>
8. Angelakis E, Richet H, Raoult D. *Rickettsia sibirica mongolotimonae* infection, France, 2010–2014. *Emerg Infect Dis*. 2016;22:880–2. <http://dx.doi.org/10.3201/eid2205.141989>
9. Kuloglu F, Rolain JM, Akata F, Eroglu C, Celik AD, Parola P. Mediterranean spotted fever in the Trakya region of Turkey. *Ticks Tick Borne Dis*. 2012;3:298–304. <http://dx.doi.org/10.1016/j.ttbdis.2012.10.030>
10. Nzaen A, Rolain JM, Hammami A, Jemaa MB, Raoult D. *Rickettsia felis* infection, Tunisia. *Emerg Infect Dis*. 2006;12:138–40. <http://dx.doi.org/10.3201/eid1201.050876>

Address for correspondence: Ferit Kusu, Cukurova University Faculty of Medicine, Department of Infectious Diseases and Clinical Microbiology, 01250, Adana, Turkey; email: feritkusu@gmail.com

Contaminated Stream Water as Source for *Escherichia coli* O157 Illness in Children

William S. Probert, Glen M. Miller, Katya E. Ledin

Author affiliation: Napa-Solano-Yolo-Marin County Public Health Laboratory, Fairfield, California, USA

DOI: <https://dx.doi.org/10.3201/eid2307.170226>

In May 2016, an outbreak of Shiga toxin–producing *Escherichia coli* O157 infections occurred among children who had played in a stream flowing through a park. Analysis of *E. coli* isolates from the patients, stream water, and deer and coyote scat showed that feces from deer were the most likely source of contamination.

In the United States, recreational water is a relatively uncommon source of Shiga toxin–producing *Escherichia coli* (STEC) O157 outbreaks (1). We describe an outbreak of STEC O157 infections among children exposed to a contaminated stream in northern California, USA, and provide laboratory evidence establishing wildlife as the source of water contamination.

In May 2016, four cases of Shiga toxin (Stx) 1– and 2–producing *E. coli* O157 infection were reported to a local health department in northern California; investigation revealed a common source of exposure. The case-patients, ranging in age from 1 to 3 years, had played in a stream adjacent to a children’s playground within a city park. Exposure of the case-patients to the stream occurred on 3 separate days spanning a 2-week period. Two case-patients are known to have ingested water while playing in the stream. Two case-patients were siblings. All case-patients had diarrhea and abdominal cramps; bloody diarrhea was reported for 3. One case-patient was hospitalized with hemolytic uremic syndrome.

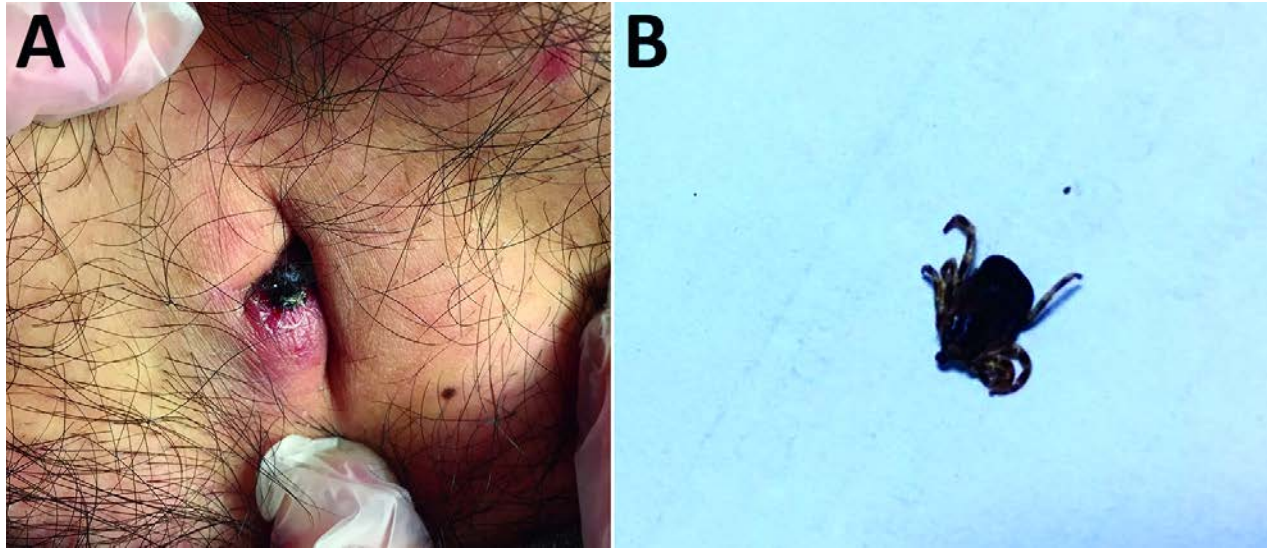
The stream is a second-order waterway located in a northern California community of ≈7,500 residents. At the time of exposures, stream flow was <30 ft³/s. The land upstream is not used for agricultural activities such as livestock production. The community is serviced by a public sewer system; inspection of sewer lines indicated no breach to the system.

Water samples were collected from the exposure site 7 days after the last case-patient was exposed and weekly thereafter for 17 weeks; samples were tested quantitatively for fecal indicator organisms. Throughout the study period, all water samples exceeded recreational water quality limits for *E. coli* and enterococci levels (2). Water samples were also cultured for STEC isolation and PCR detection of *stx*₁ and *stx*₂ (3). Stx1- and Stx2-producing *E. coli* O157 were isolated from stream water each week for the first 4 weeks. Additionally, an Stx2-producing *E. coli* non-O157 strain was isolated from the stream in the first week of sampling. Enrichment broth cultures of water samples were also positive by PCR for *stx*₁ and *stx*₂ for the first 4 weeks of sampling. Thereafter, both *stx*₁ and *stx*₂, or *stx*₂ only, were intermittently detected in enrichment broth cultures for 9 additional weeks.

In the absence of an obvious source (e.g., upstream agricultural operation or sewer leak), wildlife was considered as a possible contributor to water contamination.

Rickettsia sibirica mongolitimonae Infection, Turkey, 2016

Technical Appendix



Technical Appendix Figure. *Rickettsia sibirica mongolitimonae* infection in man, Turkey, 2016. A) Black necrotic eschar on the umbilicus of the patient. B) *Hyalomma marginatum* female tick removed from the patient.