

Informed consent was obtained from the patient's parents for publication of this case report.

References

1. Lisdiyanti P, Kawasaki H, Seki T, Yamada Y, Uchimura T, Komagata K. Systematic study of the genus *Acetobacter* with descriptions of *Acetobacter indonesiensis* sp. nov., *Acetobacter tropicalis* sp. nov., *Acetobacter orleanensis* (Henneberg 1906) comb. nov., *Acetobacter lovaniensis* (Frateur 1950) comb. nov., and *Acetobacter estunensis* (Carr 1958) comb. nov. *J Gen Appl Microbiol*. 2000;46:147–65. <http://dx.doi.org/10.2323/jgam.46.147>
2. Sengun IY, Karabiyikli S. Importance of acetic acid bacteria in food industry. *Food Control*. 2011;22:647–56. <http://dx.doi.org/10.1016/j.foodcont.2010.11.008>
3. Snyder RW, Ruhe J, Kobrin S, Wasserstein A, Doline C, Nachamkin I, et al. *Asaia bogorensis* peritonitis identified by 16S ribosomal RNA sequence analysis in a patient receiving peritoneal dialysis. *Am J Kidney Dis*. 2004;44:e15–7. <http://dx.doi.org/10.1053/j.ajkd.2004.04.042>
4. Greenberg DE, Shoffner AR, Zelazny AM, Fenster ME, Zarembek KA, Stock F, et al. Recurrent *Granulibacter bethesdaensis* infections and chronic granulomatous disease. *Emerg Infect Dis*. 2010;16:1341–8. <http://dx.doi.org/10.3201/eid1609.091800>
5. Alauzet C, Teyssier C, Jumas-Bilak E, Gouby A, Chiron R, Rabaud C, et al. *Glucanobacter* as well as *Asaia* species, newly emerging opportunistic human pathogens among acetic acid bacteria. *J Clin Microbiol*. 2010;48:3935–42. <http://dx.doi.org/10.1128/JCM.00767-10>
6. Tuuminen T, Heinämäki T, Kerttula T. First report of bacteremia by *Asaia bogorensis*, in a patient with a history of intravenous-drug abuse. *J Clin Microbiol*. 2006;44:3048–50. <http://dx.doi.org/10.1128/JCM.00521-06>
7. Abdel-Haq N, Savaşan S, Davis M, Asmar BI, Painter T, Salimnia H. *Asaia lannaensis* bloodstream infection in a child with cancer and bone marrow transplantation. *J Med Microbiol*. 2009;58:974–6. <http://dx.doi.org/10.1099/jmm.0.008722-0>
8. Juretschko S, Beavers-May TK, Stovall SH. Nosocomial infection with *Asaia lannensis* in two paediatric patients with idiopathic dilated cardiomyopathy. *J Med Microbiol*. 2010;59:848–52. <http://dx.doi.org/10.1099/jmm.0.019067-0>
9. Gouby A, Teyssier C, Vecina F, Marchandin H, Granolleras C, Zorogniotti I, et al. *Acetobacter cibirongensis* bacteremia in human. *Emerg Infect Dis*. 2007;13:784–5. <http://dx.doi.org/10.3201/eid1305.060532>
10. Bittar F, Reynaud-Gaubert M, Thomas P, Boniface S, Raoult D, Rolain JM. *Acetobacter indonesiensis* pneumonia after lung transplant. *Emerg Infect Dis*. 2008;14:997–8. <http://dx.doi.org/10.3201/eid1406.071236>

Address for correspondence: Rebekka Kohlmann, Department of Medical Microbiology, Ruhr-Universität Bochum, Universitätsstraße 150, 44801 Bochum, Germany; email: rebekka.kohlmann@rub.de

Autochthonous Chikungunya Fever in Traveler Returning to Japan from Cuba

Motoyuki Tsuboi, Satoshi Kutsuna, Yasuyuki Kato, Eri Nakayama, Ken-ichi Shibasaki, Shigeru Tajima, Tomohiko Takasaki, Yuichi Katanami, Kei Yamamoto, Nozomi Takeshita, Kayoko Hayakawa, Shuzo Kanagawa, Norio Ohmagari

Author affiliations: National Center for Global Health and Medicine, Tokyo, Japan (M. Tsuboi, S. Kutsuna, Y. Kato, Y. Katanami, K. Yamamoto, N. Takeshita, K. Hayakawa, S. Kanagawa, N. Ohmagari); National Institute of Infectious Diseases, Tokyo (E. Nakayama, K.-i. Shibasaki, S. Tajima, T. Takasaki)

DOI: <http://dx.doi.org/10.3201/eid2209.160603>

To the Editor: Chikungunya fever is a febrile illness caused by mosquito-transmitted chikungunya virus (CHIKV; genus *Alphavirus*, family *Togaviridae*). Clinical signs and symptoms typically begin with high-grade fever after an incubation period of 2–4 days (1). Other common symptoms include polyarthralgia, which is usually symmetric and involves multiple and distal joints, and skin involvement manifesting as a macular or maculopapular rash (2). Peripheral lymphadenopathy (most often cervical) and conjunctivitis might also occur (3).

Since late 2013, several outbreaks of illness caused by CHIKV have occurred in the Americas, including South America, the Caribbean, and the United States, which are outside this virus's former distribution area (3). Although autochthonous transmission of chikungunya fever has been reported in most Caribbean islands, only imported cases have been previously reported in Cuba (4). As increased numbers of US tourists visit Cuba after improved diplomatic relations in July 2015, reports of chikungunya fever cases in Cuba are of interest for travelers and health-care providers. We describe a case of autochthonous chikungunya fever in a man who had traveled from Japan to Cuba.

In late February 2016, a previously healthy 27-year-old man visited a travel clinic in the National Center for Global Health and Medicine (Tokyo, Japan) with fever and rash. In mid-February, he had traveled to Havana and Santiago de Cuba in Cuba by way of Toronto, Ontario, Canada, for 11 days of sightseeing. He used no insect repellent during the trip and was unaware of any mosquito bites. When he sought care, he reported a high-grade fever (39°C) for 24 hours and several symptoms since the day of his return: retro-orbital pain, malaise, congested conjunctivas, and a

rash on his anterior chest. Over the previous few days, his knee and ankle joints also had mild arthralgia.

On physical examination, the patient's body temperature was 38.7°C, and he had congested bulbar conjunctivas, cervical lymphadenopathy, and maculopapular rashes on his face, trunk, and extremities (online Technical Appendix Figure, panels A, B, <http://wwwnc.cdc.gov/EID/article/22/9/16-0603-Techapp1.pdf>). Laboratory tests revealed lymphopenia (701 cells/μL) and mild elevation of C-reactive protein (0.87 mg/dL). Real-time reverse transcription PCR detected CHIKV RNA in his serum sample. Phylogenetic analysis was performed on the basis of nucleotide sequences of the E1 gene from the sample by using the maximum likelihood method with 1,000 bootstrap replicates and MEGA 6.0 software (5). This sequence (GenBank accession no. LC146714) was 99.9% (1,319 of 1,320 sequences) was identical to that of a CHIKV strain isolated from the Dominican Republic in 2014 (GenBank accession no. KR559498) (Figure; online Technical Appendix Table). The positive-to-negative ratio of CHIKV-specific IgM was negative in a serum sample collected on day 4 after fever onset but was positive in a sample taken 7 days later (positive-to-negative ratios 5.6 and 21.9, respectively; ratios were considered positive if >11). Because the patient's serum samples contained no dengue or Zika virus, infections from these viruses were excluded, and chikungunya fever was diagnosed.

One day after the patient's first visit to the clinic, rashes on his extremities became worse and slightly itchy. Pain also developed in his wrists and metacarpophalangeal joints of his hand, followed by cervical pain and slight rigidity on the hand's distal and proximal interphalangeal

joints. The patient was initially treated with acetaminophen (600 mg 3×/d 2 d); after diagnosis of chikungunya fever, he was treated with loxoprofen and rebamipide (60 mg and 100 mg, respectively, 3×/d 7 d). The congested bulbar conjunctivas and rash on his trunk improved; soon thereafter, all symptoms resolved.

CHIKV was first isolated in 1953 in Tanzania during an epidemic outbreak in East Africa (6). Mosquitoes, predominantly *Aedes aegypti* and *Ae. albopictus*, transmit the virus (2). *Aedes* spp. are also the common vector of dengue and Zika viruses, and localized dengue outbreaks occurred in Santiago de Cuba in 1997 and in Havana in 2000–2001 because of the persistence of *Aedes* mosquito infestation in Cuba (7,8). Furthermore, autochthonous Zika virus infection in Cuba was first reported in March 2016 (9).

Differentiation between chikungunya fever, dengue fever, and Zika virus infection is difficult because of similar signs and symptoms and common endemic areas. We suspected chikungunya fever in this patient because of high-grade fever and maculopapular rash, although he also had prominent conjunctivitis, which is uncommon in CHIKV-infected patients but frequent in persons infected with Zika virus (3,10). Phylogenetic analysis of the virus isolated from this patient revealed a high sequence homology with recent strains discovered in Caribbean and Central American countries in 2014. Homology between the isolate from this patient and a 2014 Asian lineage isolate from the Dominican Republic was 99.92% at the nucleotide level.

This case highlights the potential threat of a chikungunya fever outbreak in Cuba. Physicians should consider chikungunya fever in the differential diagnosis for febrile

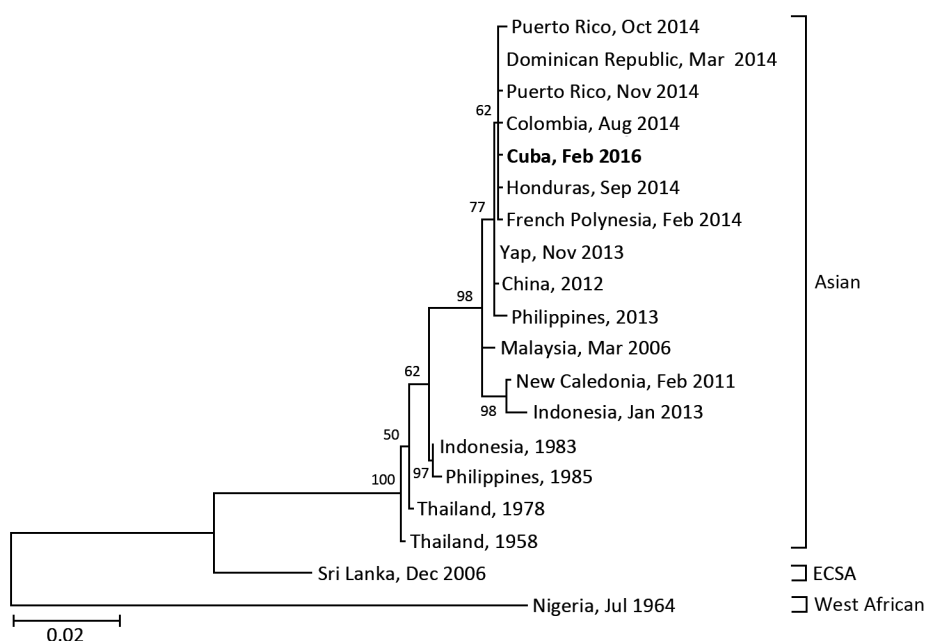


Figure. Phylogenetic analysis of the chikungunya virus sequence obtained from a patient returning to Japan (in bold) from Cuba in February 2016, compared with reference sequences. Virus lineages are shown at right. Scale bar represents substitutions per nucleotide position. ECSA, Eastern/Central/South African lineage.

travelers returning from Cuba with a rash, similarly to patients returning from other countries in which dengue fever, chikungunya fever, and Zika virus infection are endemic. Preventive measures, including advice to travelers on proper use of insect repellents, are critical for preventing CHIKV infection.

Acknowledgments

The authors thank the clinical staff at the Disease Control and Prevention Center, Tokyo, Japan, for their help in completing this study.

A grant from the National Center for Global Health and Medicine (27-6001) supported this work.

References

1. Burt FJ, Rolph MS, Rulli NE, Mahalingam S, Heise MT. Chikungunya: a re-emerging virus. *Lancet*. 2012;379:662–71. [http://dx.doi.org/10.1016/S0140-6736\(11\)60281-X](http://dx.doi.org/10.1016/S0140-6736(11)60281-X)
2. Taubitz W, Cramer JP, Kapaun A, Pfeiffer M, Drosten C, Dobler G, et al. Chikungunya fever in travelers: clinical presentation and course. *Clin Infect Dis*. 2007;45:e1–4. <http://dx.doi.org/10.1086/518701>
3. Weaver SC, Lecuit M. Chikungunya virus and the global spread of a mosquito-borne disease. *N Engl J Med*. 2015;372:1231–9. <http://dx.doi.org/10.1056/NEJMra1406035>
4. Pan American Health Organization. Countries/territories with autochthonous transmission or imported cases of Chikungunya in the Americas, EW 49, 2013–EW 10, 2016 [cited 2016 Apr 7]. http://www.paho.org/hq/images/stories/AD/HSD/IR/Viral_Diseases/Chikungunya/CHIKV-Data-Caribbean-2016-EW-10.jpg
5. Tamura K, Stecher G, Peterson D, Filipski A, Kumar S. MEGA6: molecular evolutionary genetics analysis version 6.0. *Mol Biol Evol*. 2013;30:2725–9. <http://dx.doi.org/10.1093/molbev/mst197>
6. Ross RW. The Newala epidemic. III. The virus: isolation, pathogenic properties and relationship to the epidemic. *J Hyg (Lond)*. 1956;54:177–91. <http://dx.doi.org/10.1017/S0022172400044442>
7. Valdés L, Guzmán MG, Kouri G, Delgado J, Carbonell I, Cabrera MV, et al. Epidemiology of dengue and hemorrhagic dengue in Santiago, Cuba 1997 [in Spanish]. *Rev Panam Salud Publica*. 1999;6:16–25. <http://dx.doi.org/10.1590/S1020-49891999000600003>
8. Peláez O, Guzmán MG, Kouri G, Pérez R, San Martín JL, Vázquez S, et al. Dengue 3 epidemic, Havana, 2001. *Emerg Infect Dis*. 2004;10:719–22. <http://dx.doi.org/10.3201/eid1004.030271>
9. Pan American Health Organization. Zika virus (ZIKV)—incidence and trends. Regional Zika epidemiological update (Americas). 2016 Apr 8 [cited 2016 Apr 9]. http://www.paho.org/hq/index.php?option=com_content&view=article&id=11599&Itemid=41691&lang=en
10. Duffy MR, Chen TH, Hancock WT, Powers AM, Kool JL, Lanciotti RS, et al. Zika virus outbreak on Yap Island, Federated States of Micronesia. *N Engl J Med*. 2009;360:2536–43. <http://dx.doi.org/10.1056/NEJMoa0805715>

Address for correspondence: Satoshi Kutsuna, Disease Control and Prevention Center, National Center for Global Health and Medicine, 1-21-1, Toyama, Shinjuku, Tokyo 162-8655, Japan; email: sonare.since1192@gmail.com.

Inactivation and Environmental Stability of Zika Virus

Janis A. Müller, Mirja Harms, Axel Schubert, Stephanie Jansen, Detlef Michel, Thomas Mertens, Jonas Schmidt-Chanasit, Jan Münch

Author affiliations: Ulm University Medical Centre, Ulm, Germany (J.A. Müller, M. Harms, A. Schubert, D. Michel, T. Mertens, J. Münch); Bernhard Nocht Institute for Tropical Medicine, World Health Organization Collaborating Centre for Arbovirus and Hemorrhagic Fever Reference and Research, Hamburg, Germany (S. Jansen, J. Schmidt-Chanasit); German Centre for Infection Research partner sites, Hamburg-Luebeck-Borstel, Germany (S. Jansen, J. Schmidt-Chanasit)

DOI: <http://dx.doi.org/10.3201/eid2209.160664>

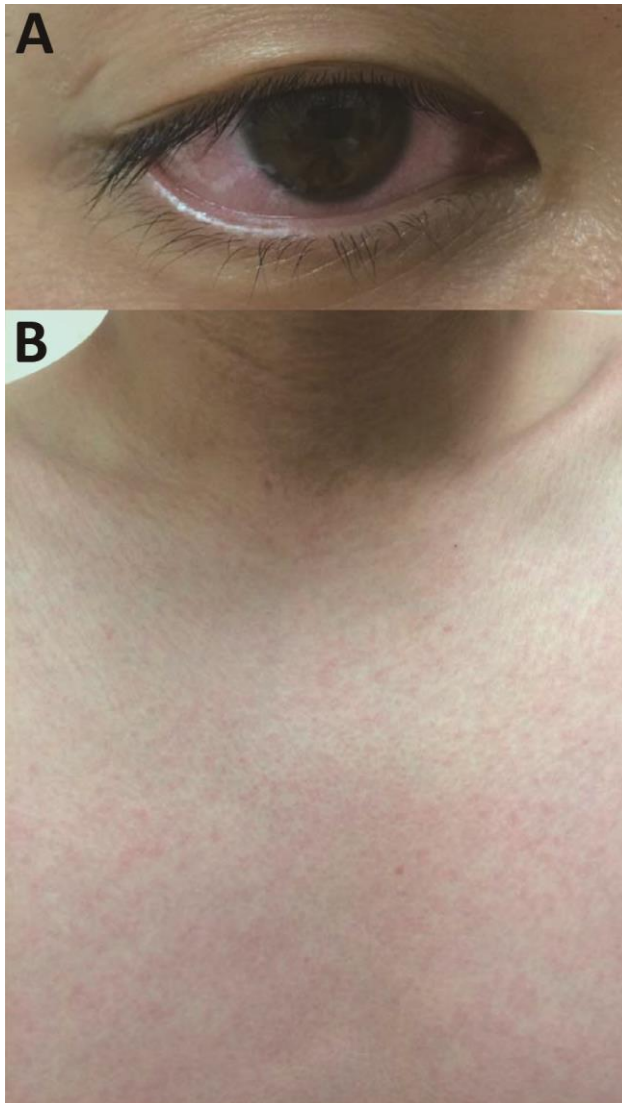To the Editor: Zika virus is an emerging virus that has spread to most countries in Latin America and the Caribbean (1,2). It is transmitted by mosquitoes and through sexual intercourse (3). Most persons infected with Zika virus are asymptomatic or experience mild symptoms (4). However, in a pregnant woman, infection may cause severe pregnancy and birth complications, most notably microcephaly in children infected in utero (5–7). Zika virus infection might also be associated with an increased incidence of Guillain-Barré syndrome (8). Thus, the virus represents a threat to healthcare workers who manage infected patients or diagnostic samples and researchers who work with infectious virus in laboratories.

Working with Zika virus, a Biosafety Level 2 (BSL-2) pathogen in the European Union, except for the United Kingdom (where it is BSL-3), requires specific safety precautions (9). No inactivation data specific for Zika virus are available (9); consequently, disinfection guidelines are based on protocols to inactivate other flaviviruses. To gain experimental evidence regarding inactivation and disinfection for Zika virus, we determined its susceptibility to various disinfectants and inactivation methods.

To test susceptibilities, we determined the 50% tissue cell infectious dose per milliliter (TCID₅₀/mL) (10) of the Zika virus MR766 strain (1) before and after the virus was exposed to disinfectants or other inactivation procedures (online Technical Appendix, <http://wwwnc.cdc.gov/EID/article/22/9/16-0664-Techapp1.pdf>). We then determined the effect of alcohol-based disinfectants on viral infectivity. Using Zika virus stock containing 2.5% fetal calf serum (FCS) mixed 3:10 (vol/vol) with indicated alcohols, we incubated the mixture for 1 minute and then used it for infection (Figure, panel A). All alcohols entirely inactivated

Autochthonous Chikungunya Fever in Traveler from Japan to Cuba

Technical Appendix



Technical Appendix Figure. Congested bulbar conjunctivas and maculopapular rash on patient's trunk. A) Congestion of bulbar conjunctivas resolved after a few days. B) Maculopapular rash with pruritus spread from the trunk to the extremities.

Technical Appendix Table. Chikungunya viral strains used for phylogenetic analysis*

Lineage	Accession no.	Strain name	Country	Date
Asian	KR559470	WHCHK1	Puerto Rico	Nov 2014
	KR559473	WHCHK4	French Polynesia	Feb 2015
	KR559483	WHCHK14	Puerto Rico	Oct 2014
	KR559488	WHCHK19	Honduras	Sep 2014
	KR559491	WHCHK22	Colombia	Aug-2014
	KR559498	WHCHK29	Dominican Republic	Mar 2014
	HE806461	NC/2011-568	New Caledonia	Feb 2011
	KM673291	DH130003	Indonesia: Bali	Jan 2013
	FN295483	MY/06/37348	Malaysia: Perak	Mar 2006
	KC488650	CHIKV-JC2012	China	2012
	KJ689453	Yap 13-2148	Micronesia: Yap State	Nov 2013
	AB860301	CHIKV-13-112A	Philippines	2013
	HM045790	PhH15483	Philippines	Jul 1985
	HM045791	JKT23574	Indonesia	1983
	HM045810	TH35	Thailand	1958
	HM045808	3412-78	Thailand	1978
	ECSA	AB455494	SL10571	Sri Lanka
West African	HM045786	IbH35	Nigeria	Jul 1964

*ECSA, East/Central/South African.