

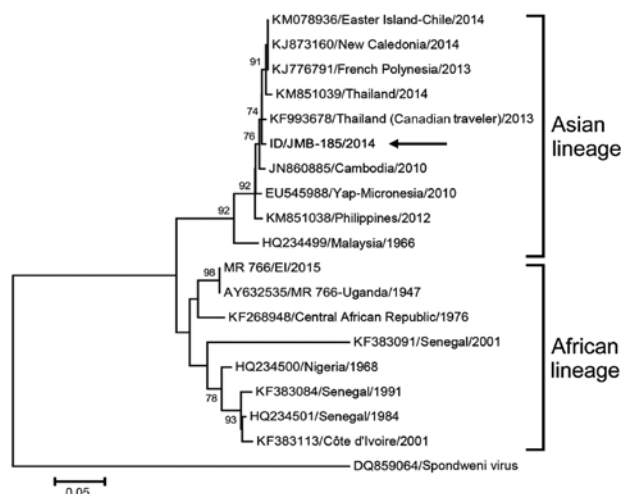Figure. Phylogenetic tree comparing Zika virus isolate from a patient in Indonesia (ID/JMB-185/2014; arrow) to reference strains from GenBank (accession numbers indicated). The tree was constructed from nucleic acid sequences of 530 bp from the nonstructural protein 5 region by using the minimum evolution algorithm in MEGA 6 (<http://www.megasoftware.net>). Numbers to the left of the nodes are bootstrap percentages (2,000 replications). Bootstrap values <70 are not shown. The tree was rooted with the Spondweni virus isolated in South Africa as the outgroup. Scale bar indicates nucleotide substitutions per site.

further tested with Zika virus-specific real-time quantitative RT-PCR (2) by using the QuantiTect Probe RT-PCR Kit (QIAGEN, Valencia, CA, USA) with amplification in the iCycler iQ5 (Bio-Rad, Hercules, CA, USA), following the manufacturer's instructions. Viral titers of JMB-185, as determined by real-time quantitative RT-PCR, were 4.25×10^3 PFU, 5.07×10^7 PFU, and 7.33×10^6 PFU for the clinical sample, first passage, and second passage, respectively.

The isolation and characterization of Zika virus from a resident with no travel history confirm that the virus is circulating in Indonesia and that, by mimicking mild dengue infection, this infection is likely contributing to the large number of undiagnosed cases of acute febrile illness. Although reported human cases of Zika virus infection have been rare in Southeast Asia (1), confusion with dengue and difficulty in obtaining a laboratory diagnosis are likely causing its incidence to be underestimated. Surveillance must be implemented to evaluate and monitor the distribution of Zika virus and the potential public health problems it may cause in Indonesia.

Acknowledgments

We thank the patient, physicians, and the management of Siloam Hospitals Jambi for their support during the study.

This study was supported by the Ministry of Research, Technology and Higher Education of the Republic of Indonesia, the US Centers for Disease Control and Prevention, and the US Agency for International Development.

References

- Dick GWA, Kitchen SF, Haddock AJ. Zika virus. I. Isolations and serological specificity. *Trans R Soc Trop Med Hyg.* 1952;46:509–20. [http://dx.doi.org/10.1016/0035-9203\(52\)90042-4](http://dx.doi.org/10.1016/0035-9203(52)90042-4)
- Lanciotti RS, Kosoy OL, Laven JJ, Velez JO, Lambert AJ, Johnson AJ, et al. Genetic and serologic properties of Zika virus associated with an epidemic, Yap State, Micronesia, 2007. *Emerg Infect Dis.* 2008;14:1232–9. <http://dx.doi.org/10.3201/eid1408.080287>
- Musso D, Nilles EJ, Cao-Lorreau VM. Rapid spread of emerging Zika virus in the Pacific area. *Clin Microbiol Infect.* 2014;20:O595–6. <http://dx.doi.org/10.1111/1469-0691.12707>
- Zanluca C, de Melo VCA, Mosimann ALP, Dos Santos GIV, Dos Santos CND, Luz K. First report of autochthonous transmission of Zika virus in Brazil. *Mem Inst Oswaldo Cruz.* 2015;110:569–72. <http://dx.doi.org/10.1590/0074-02760150192>
- Olson JG, Ksiazek TG, Suhandiman, Triwibowo. Zika virus, a cause of fever in Central Java, Indonesia. *Trans R Soc Trop Med Hyg.* 1981;75:389–93. [http://dx.doi.org/10.1016/0035-9203\(81\)90100-0](http://dx.doi.org/10.1016/0035-9203(81)90100-0)
- Buathong R, Hermann L, Thaisomboonsuk B, Rutvisuttinunt W, Klungthong C, Chinnawirotpisan P, et al. Detection of Zika virus infection in Thailand, 2012–2014. *Am J Trop Med Hyg.* 2015;93:380–3. <http://dx.doi.org/10.4269/ajtmh.15-0022>
- Alera MT, Hermann L, Tac-An IA, Klungthong C, Rutvisuttinunt W, Manasatienkij W, et al. Zika virus infection, Philippines, 2012. *Emerg Infect Dis.* 2015;21:722–4. <http://dx.doi.org/10.3201/eid2104.141707>
- Heang V, Yasuda CY, Sovann L, Haddock AD, Travassos da Rosa AP, Tesh RB, et al. Zika virus infection, Cambodia, 2010. *Emerg Infect Dis.* 2012;18:349–51. <http://dx.doi.org/10.3201/eid1802.111224>
- Haddock AD, Schuh AJ, Yasuda CY, Kasper MR, Heang V, Huy R, et al. Genetic characterization of Zika virus strains: geographic expansion of the Asian lineage. *PLoS Negl Trop Dis.* 2012;6:e1477. <http://dx.doi.org/10.1371/journal.pntd.0001477>
- Fonseca K, Meatherall B, Zarra D, Drebot M, MacDonald J, Pabbaraju K, et al. First case of Zika virus infection in a returning Canadian traveler. *Am J Trop Med Hyg.* 2014;91:1035–8. <http://dx.doi.org/10.4269/ajtmh.14-0151>

Address for correspondence: R. Tedjo Sasmono, Eijkman Institute for Molecular Biology, Jl. Diponegoro 69, Jakarta 10430, Indonesia; email: sasmono@eijkman.go.id

Fatal Sickle Cell Disease and Zika Virus Infection in Girl from Colombia

Laura Arzuza-Ortega, Arnulfo Polo, Giamina Pérez-Tatis, Humberto López-García, Edgar Parra, Lissethe C. Pardo-Herrera, Angélica M. Rico-Turca, Wilmer Villamil-Gómez, Alfonso J. Rodríguez-Morales

Author affiliations: Entidades Promotoras de Salud Barrios Unido Mutual, Quibdó, Colombia (L. Arzuza-Ortega); Empresa Social del Estado Hospital de Malambo, Malambo, Colombia (A. Polo); Hospital Metropolitano, Barranquilla, Colombia (G. Pérez-Tatis,

H. López-García); Instituto Nacional de Salud, Bogotá, Colombia (E. Parra, L.C. Pardo-Herrera, A.M. Rico-Turca); Hospital Universitario de Sincelajo, Sincelajo, Colombia, (W. Villamil-Gómez); Universidad del Atlántico, Barranquilla (W. Villamil-Gómez); Universidad de Cartagena, Cartagena, Colombia (W. Villamil-Gómez); Universidad Tecnológica de Pereira, Pereira, Colombia (A.J. Rodriguez-Morales)

DOI: <http://dx.doi.org/10.3201/eid2205.151934>

To the Editor: Zika virus, a mosquito-borne flavivirus, causes a usually self-limiting febrile and exanthematic arthralgia syndrome that resembles dengue and chikungunya (1). This arboviral disease has emerged in tropical areas of Latin America, particularly in Brazil and Colombia (2), as a public health threat in 2015 and has spread into areas to which dengue virus (DENV) and chikungunya virus (CHIKV) are endemic (1–4).

Cases of severe and fatal Zika virus infection have not been described (5), and the spectrum of clinical disease remains uncertain in the setting of rapidly evolving epidemics of this arbovirus in Latin America (1). We report a person with sickle cell disease who acquired a Zika virus infection and died.

The patient was a 15-year-old girl who in October 2015 came to the outpatient clinic of the Hospital of Malambo (a primary-level public hospital) in Malambo (Atlántico Department) in northern Colombia. In this region, during September 22, 2015–January 2, 2016, a total of 468

suspected cases of Zika virus infection and 4 reverse transcription PCR (RT-PCR)–confirmed cases have been reported. This patient had a high fever (temperature >40°C), arthralgias, retro-ocular pain, abdominal pain, myalgias, and jaundice for the previous 4 days. She had sickle cell disease for 5 years (hemoglobin genotype SC identified by DNA analysis), but no previous hospitalizations or episodes of vaso-occlusive crises. She had never had dengue, chikungunya, or acute chest syndrome.

At admission to the hospital, the patient had a pulse rate of 112 beats/min, a respiratory rate of 24 breaths/min, a blood pressure of 110/70 mm Hg, and a temperature of 39.0°C. She had abdominal pain, no petechiae, and no lymphadenopathy. The patient was given acetaminophen. Results of a neurologic assessment were unremarkable. Clinical laboratory findings are shown in the Table.

Given these manifestations, she was given a diagnosis of a DENV infection and referred to Barranquilla Hospital Metropolitano (Barranquilla, Colombia) where she was admitted 1 day later. Physical examination showed a pulse rate of 122 beats/min, a respiratory rate of 34/min (peripheral capillary oxygen saturation 93%), a blood pressure of 112/58 mm, and a temperature of 37.5°C. She had generalized jaundice, respiratory distress, severe abdominal pain, hepatomegaly, and splenomegaly, but no lymphadenopathy. The patient was conscious (stuporous) and had a Glasgow Coma Scale score of 13. Cardiovascular assessment showed

Table. Clinical laboratory results for 15-year-old girl with sickle cell disease who died of Zika virus infection, Colombia*

Laboratory test	Baseline value	Value at hospitalization (Malambo)	Value 24 h later (ICU, Barranquilla)
Leukocyte count, × 10 ⁹ cells/L	10.00	8.23	ND
Hemoglobin level, g/dL	7.00	8.10	4.20
Hematocrit, %	28.00	25.00	13.00
MCV, fL/erythrocyte	73.00	73.00	ND
Reticulocytes, %	1.00	1.00	ND
Total bilirubin, mg/dL	ND	2.97	ND
Direct bilirubin, mg/dL	ND	1.67	ND
Platelet count/mL	ND	54,000.00	76,000.00
PT, s	ND	ND	33.3 (control 13.10)
aPTT, s	ND	ND	45.0 (control 29.80)
ALT, mg/dL	ND	ND	2,245.00
AST, mg/dL	ND	ND	3,215.00
LDH, IU/L	ND	ND	441.00
Alkaline hemoglobin electrophoresis, %			
HbS	ND	ND	62.50
HbC–E	ND	ND	37.50
HbF	ND	ND	0.00
Malaria thick and thin blood smears†	Not done	Not done	–
HIV-1 and HIV-2 ELISA†	Not done	Not done	–
MAT for <i>Leptospira</i> spp.†	Not done	Not done	–
RT-PCR for DENV†	Not done	Not done	–
RT-PCR for CHIKV†	Not done	Not done	–
RT-PCR for YFV†	Not done	Not done	–
RT-PCR for ZIKV†	Not done	Not done	+

*ICU, intensive care unit; ND, not determined; MCV, mean corpuscular volume; PT, prothrombin time; aPTT, activated partial thromboplastin time; ALT, alanine aminotransferase; AST, aspartate aminotransferase; LDH, lactate dehydrogenase; Hb, hemoglobin; –, negative; MAT; microscopic agglutination test; RT-PCR, reverse transcription PCR; DENV, dengue virus; CHIKV, chikungunya virus; YFV, yellow fever virus; ZIKV, Zika virus; +, positive.

†Blood samples were obtained 5 days after illness onset. These tests were performed at the National Reference Laboratory of the National Institute of Health, Bogotá, Colombia.

tachycardia and a holosystolic murmur (grade II) but no other findings.

The patient was then transferred to the pediatric intensive care unit, where she was intubated and mechanical ventilation was initiated. Her condition was considered life threatening; the patient had severe acute respiratory distress syndrome and progressive hypoxemia despite ventilator treatment, and laboratory findings worsened (Table).

The patient was given transfusions of blood products for treatment of anemia and thrombocytopenia. Chest radiograph and ultrasound showed an extensive right-side hemothorax. The result of a Zika virus–specific real-time RT-PCR was positive (Table). Her clinical condition deteriorated. Despite intensive treatment, the patient did not recover and died 37 hours later. An autopsy showed hepatic panacinar necrosis, erythrophagocytosis of Kupffer cells, and severe decrease of splenic lymphoid tissue (functional asplenia) with multiple drepanocytes and splenic sequestration, but no signs of yellow fever or malaria (online Technical Appendix Figure, <http://wwwnc.cdc.gov/EID/article/22/5/15-1934-Techapp1.pdf>).

Although sickle cell disorders are not common in Colombia, their frequency is higher along the Caribbean coast (including Atlántico Department) and 2 times that of the rest of Colombia (6). Although chronic diseases, such as sickle cell disorders, are considered to be a risk factor for development of severe dengue and chikungunya (7,8), no cases have been reported in association with Zika. Reports of patients co-infected with DENV and CHIKV are rare, few details are available, and mostly restricted to few fatal cases of dengue (9). In patients with dengue, deaths might be higher among those who have a hemoglobin SC genotype, as recently reported (10). Onset of vaso-occlusion in persons with sickle cell disorders is often triggered by inflammation, as has been reported in DENV infections and which probably occurred in our patient (8). This complication and severe splenic sequestration, detected by autopsy, probably caused her death.

In summary, this case indicates that patients with sickle cell disorders and suspected arboviral infections should be closely monitored. Given current epidemics of Zika virus infection in Colombia (746 RT-PCR–confirmed cases and 11,712 suspected cases during September 22, 2015–January 2, 2016), atypical and severe manifestations and concurrent conditions in patients should be assessed to prevent additional deaths (2).

References

- Rodriguez-Morales AJ. Zika: the new arbovirus threat for Latin America. *J Infect Dev Ctries*. 2015;9:684–5. <http://dx.doi.org/10.3855/jidc.7230>
- Pan American Health Organization. Neurological syndrome, congenital malformations, and Zika virus infection. Implications for public health in the Americas—epidemiological alert 2015

[cited 2016 Jan 1]. http://www.paho.org/hq/index.php?option=com_docman&task=doc_download&Itemid=&gid=32405&lang=en

- Alfaro-Tolosa P, Clouet-Huerta DE, Rodriguez-Morales AJ. Chikungunya, the emerging migratory rheumatism. *Lancet Infect Dis*. 2015;15:510–2. [http://dx.doi.org/10.1016/S1473-3099\(15\)70160-X](http://dx.doi.org/10.1016/S1473-3099(15)70160-X)
- Campos GS, Bandeira AC, Sardi SI. Zika Virus Outbreak, Bahia, Brazil. *Emerg Infect Dis*. 2015;21:1885–6. <http://dx.doi.org/10.3201/eid2110.150847>
- Kwong JC, Druce JD, Leder K. Zika virus infection acquired during brief travel to Indonesia. *Am J Trop Med Hyg*. 2013;89:516–7. <http://dx.doi.org/10.4269/ajtmh.13-0029>
- Fong C, Lizarralde-Iragorri MA, Rojas-Gallardo D, Barreto G. Frequency and origin of haplotypes associated with the beta-globin gene cluster in individuals with trait and sickle cell anemia in the Atlantic and Pacific coastal regions of Colombia. *Genet Mol Biol*. 2013;36:494–7. <http://dx.doi.org/10.1590/S1415-47572013000400005>
- Economopoulou A, Dominguez M, Helynck B, Sissoko D, Wichmann O, Quenel P, et al. Atypical chikungunya virus infections: clinical manifestations, mortality and risk factors for severe disease during the 2005–2006 outbreak on Reunion. *Epidemiol Infect*. 2009;137:534–41. <http://dx.doi.org/10.1017/S0950268808001167>
- Moesker FM, Muskiet FD, Koeijers JJ, Fraaij PL, Gerstenbluth I, van Gorp EC, et al. Fatal dengue in patients with sickle cell disease or sickle cell anemia in Curacao: two case reports. *PLoS Negl Trop Dis*. 2013;7:e2203. <http://dx.doi.org/10.1371/journal.pntd.0002203>
- Bravo JR, Guzman MG, Kouri GP. Why dengue haemorrhagic fever in Cuba? 1. Individual risk factors for dengue haemorrhagic fever/dengue shock syndrome (DHF/DSS). *Trans R Soc Trop Med Hyg*. 1987;81:816–20. [http://dx.doi.org/10.1016/0035-9203\(87\)90041-1](http://dx.doi.org/10.1016/0035-9203(87)90041-1)
- Rankine-Mullings A, Reid ME, Moo Sang M, Richards-Dawson MA, Knight-Madden JM. A retrospective analysis of the significance of haemoglobin SS and SC in disease outcome in patients with sickle cell disease and dengue fever. *EBioMedicine*. 2015;2:935–9. <http://dx.doi.org/10.1016/j.ebiom.2015.07.002>

Address for correspondence: Alfonso J. Rodriguez-Morales, Public Health and Infection Research Group, Faculty of Health Sciences, Universidad Tecnológica de Pereira, Pereira, Risaralda, Colombia; email: arodriguezm@utp.edu.co

Detection of Autochthonous Zika Virus Transmission in Sincelejo, Colombia

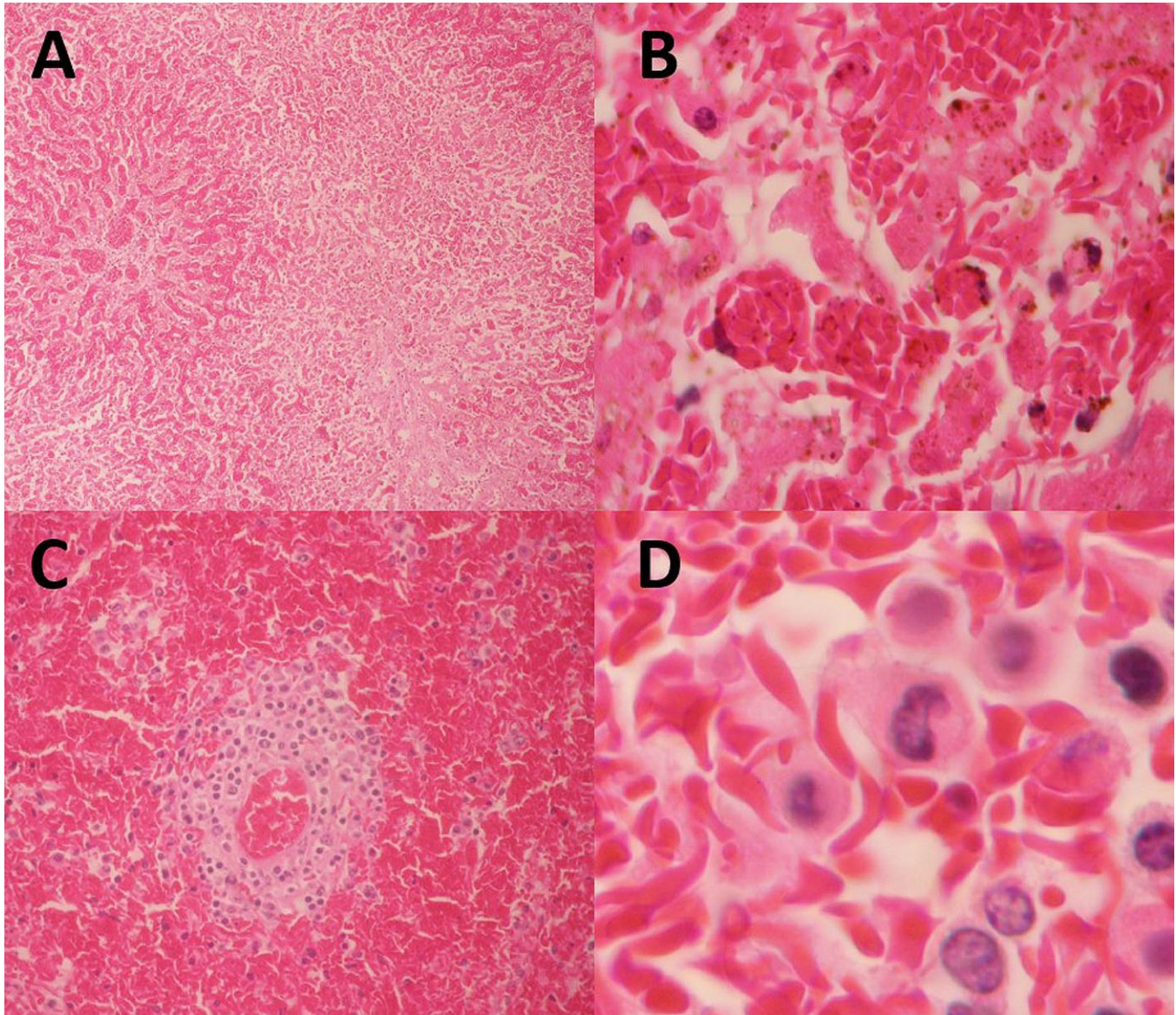
Erwin Camacho, Margaret Paternina-Gomez, Pedro J. Blanco, Jorge E. Osorio, Matthew T. Aliota

Author affiliations: University of Wisconsin–Madison, Madison, Wisconsin, USA (E. Camacho, J.E. Osorio, M.T. Aliota); Universidad de Sucre, Sincelejo, Colombia (M. Paternina-Gomez, P.J. Blanco)

DOI: <http://dx.doi.org/10.3201/eid2205.160023>

Fatal Zika Virus Infection in Patient with Sickle Cell Disease, Colombia

Technical Appendix



Technical Appendix Figure. Autopsy findings for liver and spleen of a 15-year-old girl with sickle cell disease who died of Zika virus infection, Colombia. A) Liver showing panacinar necrosis. B) Liver showing erythrophagocytosis of Kupffer cells. C) Spleen showing severe decrease of white pulp (functional asplenia). D) Spleen showing multiple splenic drepanocytes (splenic sequestration). (Hematoxylin and eosin stained) (Original magnification, $\times 10$ in A, $\times 40$ in B and C, $\times 60$ in D.)