

goats remain in pastures might have favored environmental contamination by interaction with wildlife. Furthermore, an additional case of *M. microti* infection in a cat reported in 2011 in the same region also had the SB0118 spoligotype (7), which demonstrated that this bacillus is actively circulating in animals from this area.

M. microti was previously isolated on the basis of a skin test–positive result for cattle in the United Kingdom (8), which demonstrated the risk for infection in livestock. These findings raise concern on reliability of diagnostic tests used for bovine tuberculosis surveillance. *M. microti*, which is phylogenetically similar to *M. bovis* or *M. caprae* and widely disseminated in the environment, could be responsible for misleading diagnostic results, as demonstrated in this study.

Highly specific tests are needed to accurately identify *M. bovis* (or *M. caprae*) infection at antemortem examination through use of specific antigens, such as ESAT 6 and CFPI0, which are absent in *M. microti* and are currently used in the interferon- γ test in France (9). In addition, at postmortem diagnosis, use of specific molecular tools capable of rapidly distinguishing members of the MTBC should be considered. Histopathologic analysis lacks specificity, and obtaining results for bacterial culture takes too much time for these particularly slow-growing and fastidious mycobacteria.

M. microti has already been reported to cause tuberculosis in immunocompromised and immunocompetent patients in France (10). Thus, potential risk for infection of humans by consumption of raw goat milk cheese cannot be ruled out.

Acknowledgments

We thank Dorothée Watrelot-Virieux, the regional laboratory of Savoie, the local veterinary services, and Fabrice Chevalier for providing epidemiologic information; and Victoria Boschioli for useful comments on the article.

References

- Chiari M, Ferrari N, Giardiello D, Avisani D, Pacciarini ML, Alborali L, et al. Spatiotemporal and ecological patterns of *Mycobacterium microti* infection in wild boar (*Sus scrofa*). *Transbound Emerg Dis*. 2015 Jan 12. [Epub ahead of print]. <http://dx.doi.org/10.1111/tbed.12313>
- Niemann S, Richter E, Daluge-Tamm H, Schlesinger H, Graupner D, Königstein B, et al. Two cases of *Mycobacterium microti* derived tuberculosis in HIV-negative immunocompetent patients. *Emerg Infect Dis*. 2000;6:539–42. <http://dx.doi.org/10.3201/eid0605.000516>
- Courcoul A, Moyen JL, Brugere L, Faye S, Henault S, Gares H, et al. Estimation of sensitivity and specificity of bacteriology, histopathology and PCR for the confirmatory diagnosis of bovine tuberculosis using latent class analysis. *PLoS ONE*. 2014;9:e90334. <http://dx.doi.org/10.1371/journal.pone.0090334>
- Huard RC, Lazzarini LC, Butler WR, van Soolingen D, Ho JL. PCR-based method to differentiate the subspecies of the *Mycobacterium tuberculosis* complex on the basis of genomic deletions. *J Clin Microbiol*. 2003;41:1637–50. <http://dx.doi.org/10.1128/JCM.41.4.1637-1650.2003>
- Cowan LS, Diem L, Brake MC, Crawford JT. Transfer of a *Mycobacterium tuberculosis* genotyping method, spoligotyping, from a reverse line-blot hybridization, membrane-based assay to the Luminex multianalyte profiling system. *J Clin Microbiol*. 2004;42:474–7. <http://dx.doi.org/10.1128/JCM.42.1.474-477.2004>
- Rivière J, Réveillaud E, Boschioli ML, Hars J, Richomme C, Faure E, et al. Sylvatub: results of a one year of surveillance of tuberculosis in wildlife in France [in French]. *Bulletin Épidémiologique Santé Animale et Alimentation*. 2013;57:10–5.
- Michelet L, de Cruz K, Zanella G, Aaziz R, Bulach T, Karoui C, et al. Infection with *Mycobacterium microti* in animals in France. *J Clin Microbiol*. 2015;53:981–5. <http://dx.doi.org/10.1128/JCM.02713-14>
- Jahans K, Palmer S, Inwald J, Brown J, Abayakoon S. Isolation of *Mycobacterium microti* from a male Charolais-Hereford cross. *Vet Rec*. 2004;155:373–4.
- Faye S, Moyen JL, Gares H, Benet JJ, Garin-Bastuji B, Boschioli ML. Determination of decisional cut-off values for the optimal diagnosis of bovine tuberculosis with a modified IFN- γ assay (Bovigam $\text{\textcircled{O}}$) in a low prevalence area in France. *Vet Microbiol*. 2011;151:60–7. <http://dx.doi.org/10.1016/j.vetmic.2011.02.026>
- Panteix G, Gutierrez MC, Boschioli ML, Rouviere M, Plaidy A, Pressac D, et al. Pulmonary tuberculosis due to *Mycobacterium microti*: a study of six recent cases in France. *J Med Microbiol*. 2010;59:984–9. <http://dx.doi.org/10.1099/jmm.0.019372-0>

Address for correspondence: Maria L. Boschioli, Agence Nationale de Sécurité Sanitaire de l'Alimentation, de l'Environnement et du Travail, 14 Rue Pierre et Marie Curie, Maison-Alfort 94700, France; email: maria-laura.boschioli@anses.fr

***Mycobacterium orygis*–Associated Tuberculosis in Free-Ranging Rhinoceros, Nepal, 2015**

Jeewan Thapa,¹ Sarad Paudel,¹ Amir Sadaula, Yogendra Shah, Bhagwan Maharjan, Gretchen E. Kaufman, Deborah McCauley, Kamal P. Gairhe, Toshio Tsubota, Yasuhiko Suzuki, Chie Nakajima

Author affiliations: Hokkaido University, Sapporo, Japan (J. Thapa, S. Paudel, Y. Shah, T. Tsubota, Y. Suzuki, C. Nakajima); National Trust for Nature Conservation, Biodiversity Conservation Center, Chitwan, Nepal (A. Sadaula); German Nepal Tuberculosis Project, Kathmandu, Nepal (B. Maharjan); Veterinary Initiative for Endangered Wildlife, Bozeman, Montana, USA (G.E. Kaufman, D. McCauley); Chitwan National Park Department of National Parks and Wildlife Conservation, Chitwan (K.P. Gairhe)

DOI: <http://dx.doi.org/10.3201/eid2203.151929>

¹These first authors contributed equally to this article.

To the Editor: *Mycobacterium orygis*, previously described as oryx bacilli, has recently been categorized as a member of *M. tuberculosis* complex and has been reported to cause tuberculosis (TB) in a variety of animals and in humans. Most reported isolates were of South Asian origin (1). In a previous study (2), we isolated and molecularly characterized *M. orygis* isolates from wild animals living in a captive facility in Kathmandu, Nepal.

The greater one-horned rhinoceros (*Rhinoceros unicornis*), or Indian rhinoceros, is the largest species of rhinoceros. It is listed in Appendix I of the Convention on International Trade in Endangered Species (<https://cites.org/eng/app/appendices.php>), designated as vulnerable by the International Union for Conservation of Nature Red List (<http://www.iucnredlist.org/search>), and designated as a protected species by the Government of Nepal (3). Because of successful conservation efforts, the current wild population of greater one-horned rhinoceros in Nepal and India has increased from 600 in 1975 to 3,555 in mid-2015 (4). As of 2015, the population of these rhinoceros in Nepal was 645, including 605 animals living in Chitwan National Park (CNP) (5).

On February 16, 2015, CNP officials observed a sick female rhinoceros in the buffer zone of the western sector of the park near Amaltari. The rhinoceros was dull, depressed, and not feeding. The following day, the animal was found dead in the same area (online Technical Appendix Figure 1, <http://wwwnc.cdc.gov/EID/article/22/3/15-1929-Techapp1.pdf>). Superficial maggot-infested wounds were on both sides of the vulva, indicating that the rhinoceros was not able to naturally remove the maggots and suggesting that the animal was sick for some time. During the necropsy, several granulomatous lesions were observed in the lungs and considered to be compatible with TB infection. The lesions were extensively distributed and well encapsulated and contained caseous necrotic material (online

Technical Appendix Figure 2). No other pathologic changes were observed in any of the organs examined, leading to the conclusion that the rhinoceros died from TB.

A lung tissue sample positive for TB by acid-fast staining was cultured on Lowenstein-Jensen media. We performed spoligotyping and mycobacterial interspersed repetitive units–variable-number tandem-repeat (MIRU-VNTR) procedure on the isolate as previously described (6,7). Spoligotyping analysis, performed as previously described (2), showed that the isolate had a spoligo–international type 587 pattern, indicating it was *M. orygis*. We also performed multilocus sequence typing on various genes (2), and confirmed that the isolate was *M. orygis*. We then constructed a dendrogram by comparing the MIRU-VNTR result from rhinoceros isolate with published *M. orygis* MIRU-VNTR types (Figure) (1,2,8). The rhinoceros *M. orygis* isolate fell in a unique position in the dendrogram; we identified a difference in only 1 locus (MIRU 424) when we compared the isolate with the largest cluster of reported *M. orygis* isolates, including those previously reported from Nepal.

In our earlier study (2), we isolated *M. orygis* from chital deer (*Axis axis*) and blue bull (*Boselaphus tragocamelus*) from a captive wild-animal facility and postulated that the origin of the infection might be from infected animals in CNP, where the deer and blue bull originated. This new finding of a different strain type of *M. orygis* in a free-ranging rhinoceros in CNP provides evidence for our hypothesis. Other reports of *M. orygis* in captive wild animals in Nepal (2), cattle and a rhesus monkey in Bangladesh (1), humans in South Asia (1), and an immigrant from India in New Zealand (9) further support this bacterium's potential widespread distribution in South Asia and attests to the One Health significance of this organism.

In a demographic study of rhinoceros in Nepal (10), the animals were found to be living in a narrow area of

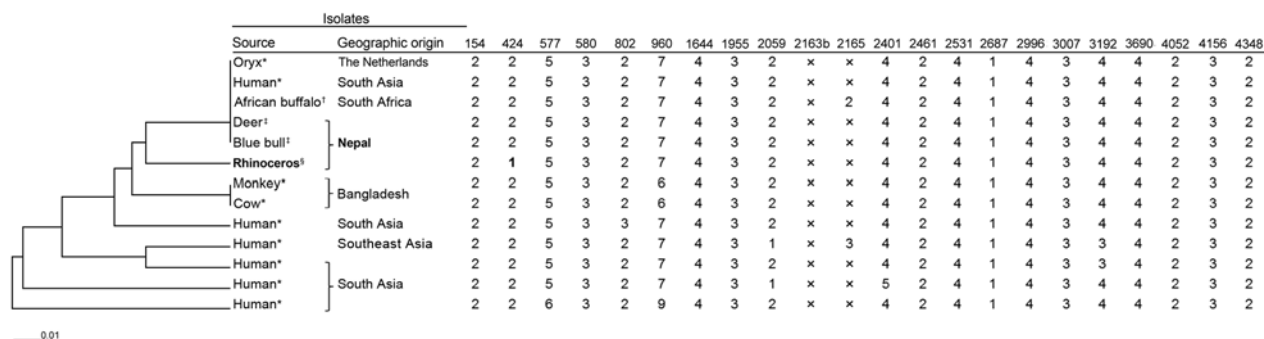


Figure. Phylogeny of *Mycobacterium orygis* isolates as determined on the basis of mycobacterial interspersed repetitive units–variable-number tandem-repeat (MIRU-VNTR) results of 22 loci. The unweighted pair group method with arithmetic mean dendrogram was drawn by using MIRU-VNTRplus software (<http://www.miru-vntrplus.org>). The order of MIRU-VNTR is as follows, left to right: 154, 424, 577, 580, 802, 960, 1644, 1955, 2059, 2163b, 2165, 2401, 2461, 2531, 2687, 2996, 3007, 3192, 3690, 4052, 4156 and 4348. *Isolates from (1), †isolate from (8), ‡isolates from (2), §isolate from this study. Bold MIRU-VNTR copy number of locus 424 in rhinoceros isolate indicates a single locus difference in MIRU-VNTR type from the largest cluster. X, unamplifiable. Scale bar indicates genetic distance.

riverine grassland in CNP. A chronic and devastating disease like TB in this vulnerable and isolated population, which is already threatened from habitat destruction and poaching, is a matter of great conservation concern for the animal's long-term survivability. Also, CNP is listed by the United Nations Educational, Scientific and Cultural Organization as a World Heritage site because of its rich biodiversity and as an important habitat for endangered animals, including Bengal tigers (*Panthera tigris*) and Asian elephants (*Elephas maximus*). Thus, *M. orygis*-associated TB in rhinoceros in CNP may also indicate a threat to other animals, including some that are endangered. There is a strong possibility of unknown maintenance hosts of *M. orygis* in and around the national park. Our findings support the need for further investigation to understand the ecology and epidemiology of *M. orygis* and provide justification for active surveillance of this bacterium in animals in the national park and in livestock and humans in the buffer-zone areas. Furthermore, the increasing evidence for widespread distribution of *M. orygis* in South Asia provides a new picture of TB and may lead to a new understanding of *M. tuberculosis* complex.

Acknowledgments

We acknowledge Chitra Bahadur Khadka and Kiran Rijal for helping with sample collection; Babu Ram Lamichhane for helping with map drawing; and Department of National Parks and Wildlife Conservation, Chitwan National Park and National Trust for Nature Conservation for providing assistance in the study.

This study was supported in part by the Japan Initiative for Global Research Network on Infectious Diseases from the Ministry of Education, Culture, Sports, Science, and Technology, Japan (MEXT); JSPS KAKENHI (grant 15K0872405); a grant from MEXT for the Hokkaido University Program for Leading Graduate Schools—Fostering Global Leaders in Veterinary Science toward the Contribution to One Health; and a grant for the Establishment of International Collaboration Centers for Zoonosis Control, Hokkaido University, from MEXT.

References

- van Ingen J, Rahim Z, Mulder A, Boeree MJ, Simeone R, Brosch R, et al. Characterization of *Mycobacterium orygis* as *M. tuberculosis* complex subspecies. *Emerg Infect Dis*. 2012; 18:653–5. <http://dx.doi.org/10.3201/eid1804.110888>
- Thapa J, Nakajima C, Maharjan B, Poudel A, Suzuki Y. Molecular characterization of *Mycobacterium orygis* isolates from wild animals of Nepal. *Jpn J Vet Res*. 2015;63:151–8.
- Government of Nepal, Ministry of Forests and Soil Conservation, Department of National Parks and Wildlife Conservation. Protected species. Mammals [cited 2015 Oct 30]. http://www.dnpwc.gov.np/protected_species/species/mammals
- World Wildlife Fund. Greater one-horned rhino [cited 2015 Oct 30]. http://www.panda.org/what_we_do/endangered_species/rhinoceros/asian_rhinos/indian_rhinoceros/
- National Trust for Nature Conservation. National rhino count 2015: 645 individual rhinos in Nepal [cited 2015 Oct 30]. <http://www.ntnc.org.np/news/national-rhino-count-2015-645-individual-rhinos-nepal>
- Kamerbeek J, Schouls L, Kolk L, van Agterveld M, van Soolingen D, Kuijper S, et al. Simultaneous detection and strain differentiation of *Mycobacterium tuberculosis* for diagnosis and epidemiology. *J Clin Microbiol*. 1997;35:907–14.
- Supply P, Allix C, Lesjean S, Cardoso-Oelemann M, Rusch-Gerdes S, Willery E, et al. Proposal for standardization of optimized mycobacterial interspersed repetitive unit–variable-number tandem repeat typing of *Mycobacterium tuberculosis*. *J Clin Microbiol*. 2006;44:4498–510. <http://dx.doi.org/10.1128/JCM.01392-06>
- Gey van Pittius NC, Perrett KD, Michel AL, Keet DF, Hlokwet T, Streicher EM, et al. Infection of African buffalo (*Syncerus caffer*) by oryx bacillus, a rare member of the antelope clade of the *Mycobacterium tuberculosis* complex. *J Wildl Dis*. 2012;48: 849–57. <http://dx.doi.org/10.7589/2010-07-178>
- Dawson KL, Bell A, Kawakami RP, Coley K, Yates G, Collins DM. Transmission of *Mycobacterium orygis* (*M. tuberculosis* complex species) from a tuberculosis patient to a dairy cow in New Zealand. *J Clin Microbiol*. 2012;50:3136–8. <http://dx.doi.org/10.1128/JCM.01652-12>
- Subedi N, Jnawali SR, Dhakal M, Pradhan NMB, Lamichhane BR, Malla S, et al. Population status, structure and distribution of the greater one-horned rhinoceros *Rhinoceros unicornis* in Nepal. *Oryx*. 2013;47:352–60. <http://dx.doi.org/10.1017/S0030605313000562>

Address for correspondence: Chie Nakajima, Division of Bioresources, Hokkaido University Research Center for Zoonosis Control, Kita 20 Nishi 10, Kita-ku, Sapporo 001-0020, Japan; email: cnakajim@czc.hokudai.ac.jp

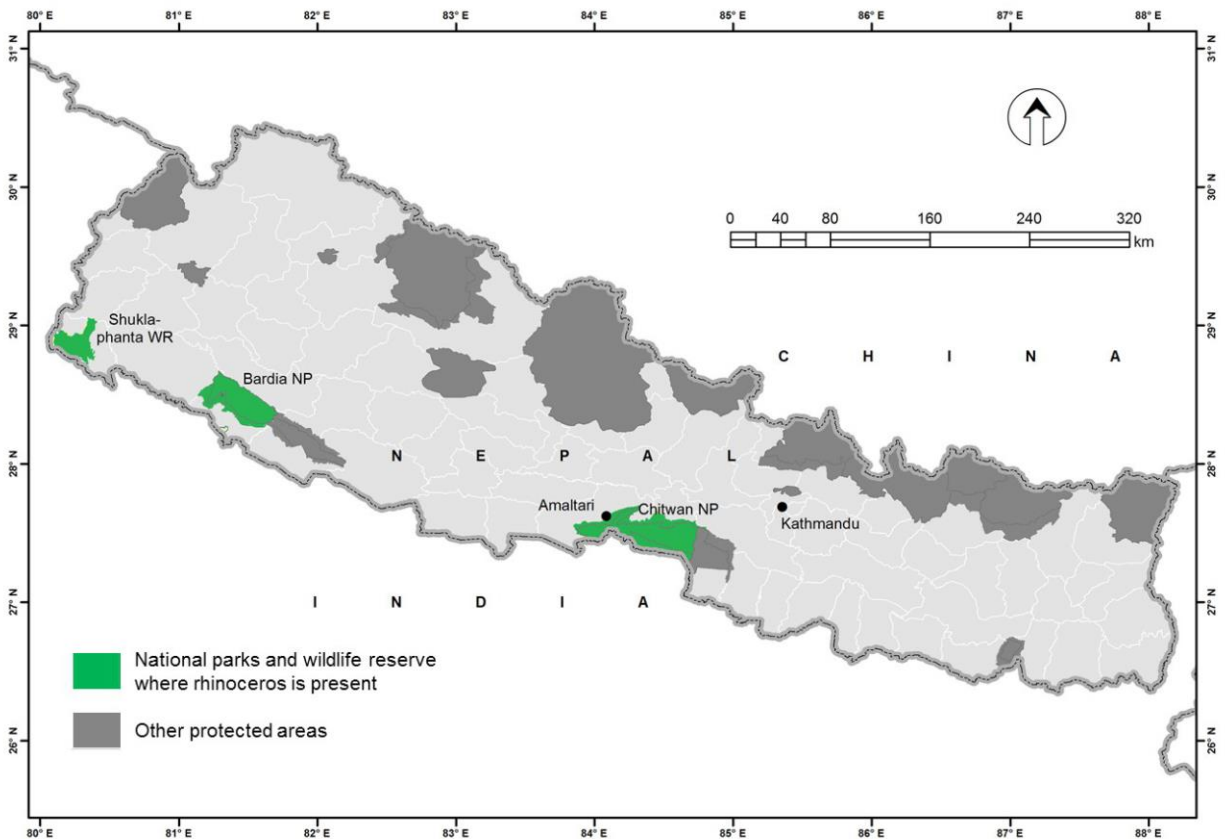
Another Dimension

Emerging Infectious Diseases accepts thoughtful essays, short stories, or poems on philosophical issues related to science, medical practice, and human health. Topics may include science and the human condition, the unanticipated side of epidemic investigations, or how people perceive

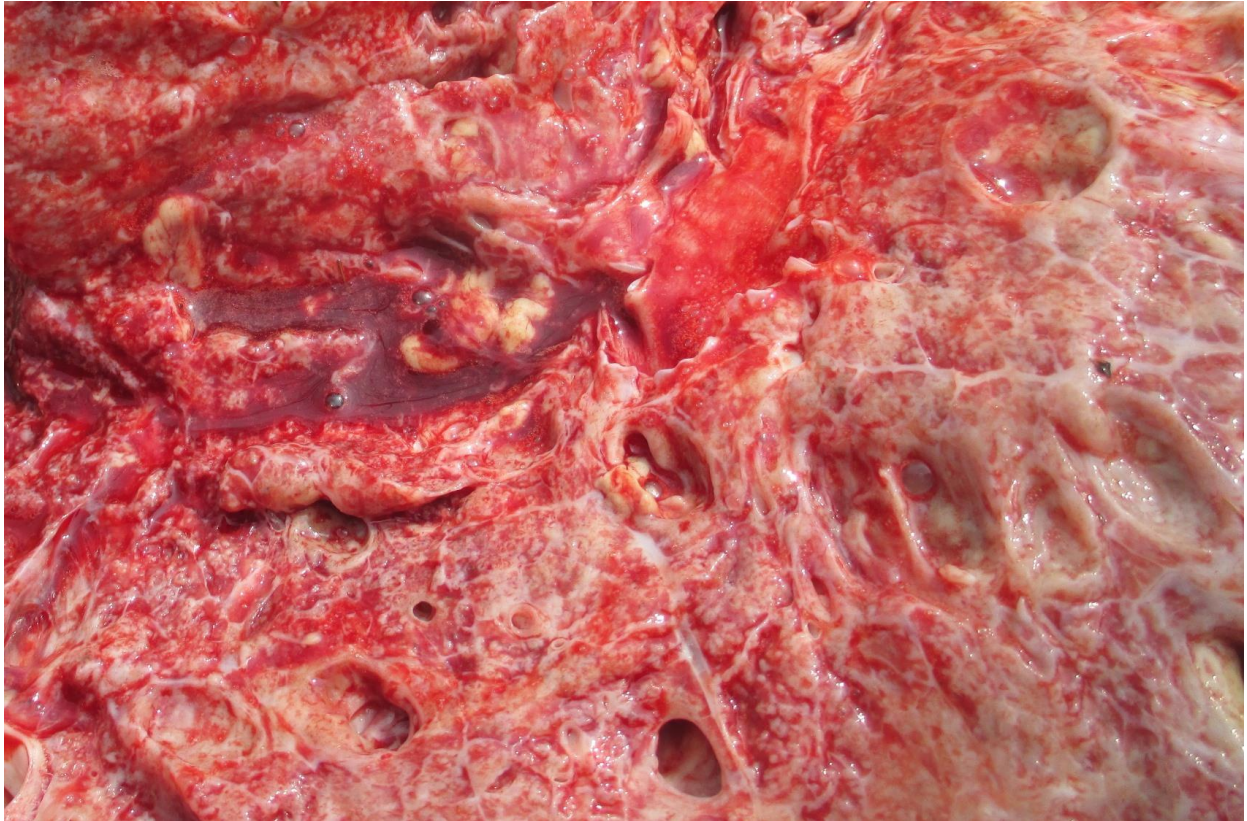and cope with infection and illness. This section is intended to evoke compassion for human suffering and to expand the science reader's literary scope. Manuscripts are selected for publication as much for their content (the experiences they describe) as for their literary merit.

Tuberculosis Caused by *Mycobacterium orygis* in Free-Ranging Rhinoceros, Nepal, 2015

Technical Appendix



Technical Appendix Figure 1. Location of Amaltari in Chitwan National Park from where rhinoceros was found dead. Kathmandu is place of captive facility from where *Mycobacterium orygis* was reported from wild animals.



Technical Appendix Figure 2. Granulomatous tuberculosis lesion with caseous mass in lungs.