

and clinical findings consistent with the disease. The delay in diagnosis led to a life-threatening condition for the patient. Physicians in areas where scrub typhus is nonendemic should have a high index of suspicion for rickettsial infections in patients with recent travel histories to areas where the disease is endemic and consider treatment with tetracyclines whenever rickettsial infection is suspected. Furthermore, the potential for aerosol transmission of *O. tsutsugamushi* from patients with scrub typhus-associated ARDS to health care workers should be evaluated.

References

1. Kurup A, Issac A, Loh JP, Lee TB, Chua R, Bist P, et al. Scrub typhus with sepsis and acute respiratory distress syndrome. *J Clin Microbiol.* 2013;51:2787–90. <http://dx.doi.org/10.1128/JCM.00463-13>
2. Wang CC, Liu SF, Liu JW, Chung YH, Su MC, Lin MC. Acute respiratory distress syndrome in scrub typhus. *Am J Trop Med Hyg.* 2007;76:1148–52.
3. Tsay RW, Chang FY. Acute respiratory distress syndrome in scrub typhus. *QJM.* 2002;95:126–8. <http://dx.doi.org/10.1093/qjmed/95.2.126>
4. Jiang J, Chan TC, Temenak JJ, Dasch GA, Ching WM, Richards AL. Development of a quantitative real-time polymerase chain reaction assay specific for *Orientia tsutsugamushi*. *Am J Trop Med Hyg.* 2004;70:351–6.
5. Angelakis E, Munasinghe A, Yaddhige I, Liyanapathirana V, Thevanesam V, Bregliano A, et al. Detection of rickettsioses and Q fever in Sri Lanka. *Am J Trop Med Hyg.* 2012;86:711–2. <http://dx.doi.org/10.4269/ajtmh.2012.11-0424>
6. Tantibhedhyangkul W, Angelakis E, Tongyoo N, Newton PN, Moore CE, Phetsouvanh R, et al. Intrinsic fluoroquinolone resistance in *Orientia tsutsugamushi*. *Int J Antimicrob Agents.* 2010;35:338–41. <http://dx.doi.org/10.1016/j.ijantimicag.2009.11.019>
7. Fournier PE, Siritantikorn S, Rolain JM, Suputtamongkol Y, Hoontrakul S, Charoenwat S, et al. Detection of new genotypes of *Orientia tsutsugamushi* infecting humans in Thailand. *Clin Microbiol Infect.* 2008;14:168–73. <http://dx.doi.org/10.1111/j.1469-0691.2007.01889.x>
8. Moron CG, Popov VL, Feng HM, Wear D, Walker DH. Identification of the target cells of *Orientia tsutsugamushi* in human cases of scrub typhus. *Mod Pathol.* 2001;14:752–9. <http://dx.doi.org/10.1038/modpathol.3880385>
9. Tseng BY, Yang HH, Liou JH, Chen LK, Hsu YH. Immunohistochemical study of scrub typhus: a report of two cases. *Kaohsiung J Med Sci.* 2008;24:92–8. [http://dx.doi.org/10.1016/S1607-551X\(08\)70103-7](http://dx.doi.org/10.1016/S1607-551X(08)70103-7)
10. Jensenius M, Davis X, von Sonnenburg F, Schwartz E, Keystone JS, Leder K, et al. Multicenter GeoSentinel analysis of rickettsial diseases in international travelers, 1996–2008. *Emerg Infect Dis.* 2009;15:1791–8. <http://dx.doi.org/10.3201/eid1511.090677>

Address for correspondence: Didier Raoult, Faculté de Médecine, Université de la Méditerranée, URMITE, UMR CNRS 6236, IRD 198, Centre National de Référence, 27 Blvd Jean Moulin Marseille 13005, France; email: didier.raoult@gmail.com

All material published in *Emerging Infectious Diseases* is in the public domain and may be used and reprinted without special permission; proper citation, however, is required.

Clustered Cases of *Oestrus ovis* Ophthalmomyiasis after 3-Week Festival, Marseille, France, 2013

Lucas Bonzon, Isabelle Toga, Martine Piarroux, Renaud Piarroux

Author affiliations: Parasitology Hôpital de la Timone, Marseilles, France (L. Bonzon, I. Toga, R. Piarroux); Aix-Marseille University, Marseilles (M. Piarroux, R. Piarroux, L. Bonzon)

DOI: <http://dx.doi.org/10.3201/eid2102.140974>

To the Editor: Ophthalmomyiasis is a zoonosis generally caused by *Oestrus ovis*, a fly that lays eggs on the eye of its host. The hatched larvae cause irritation, and left untreated, the infestation can lead to blindness (1). The disease is rare and is mainly reported as sporadic cases in pastoral areas where the population is in close contact with common reproductive hosts of the fly, such as sheep and goats in the Middle East (2), Southeast Asia (3,4), and the Mediterranean Basin (5,6). Only limited ophthalmomyiasis outbreaks have been reported around the Mediterranean Sea (7). A century ago, the Provence region of southern France was a pastoral area, where twice a year, large herds of sheep migrated between the pastures in the mountains north of the region and the grassland plains in the southwest. These migrations were termed *transhumance*. In 2013, Marseille metropolis, the largest urban area in Provence, was chosen as the yearly “European Capital of Culture.” In this context, from May 17 to June 9, a large-scale *transhumance* event took place, which featured the gathering of huge flocks of sheep (Figure) that had passed through many towns in the vicinity of Marseille. *La transhumance* culminated in a parade through downtown Marseille, where 600 horseback riders converged with flocks of 3,000 sheep and goats, and >300,000 spectators gathered.

From the last week of June through the third week of July, 4 cases of ophthalmomyiasis were reported in the area surrounding Marseille (Figure). Only 1 case had occurred in the region during the previous 5 years. The first case-patient was a 45-year-old female teacher, who lived and worked in Allauch, located in the immediate suburbs, 21 km (≈13 mi) east of Marseille. On June 25, while on the school playground, she described feeling a fly hit her right eye. In the evening, itching and irritation of the eye prompted her to seek referral to an ophthalmologic emergency center. Examination concluded the presence of small mobile larvae inside the eye, which were identified as *O. ovis* (online Technical Appendix, <http://wwwnc.cdc.gov/EID/article/21/2/14-0974-Techapp1.pdf>).

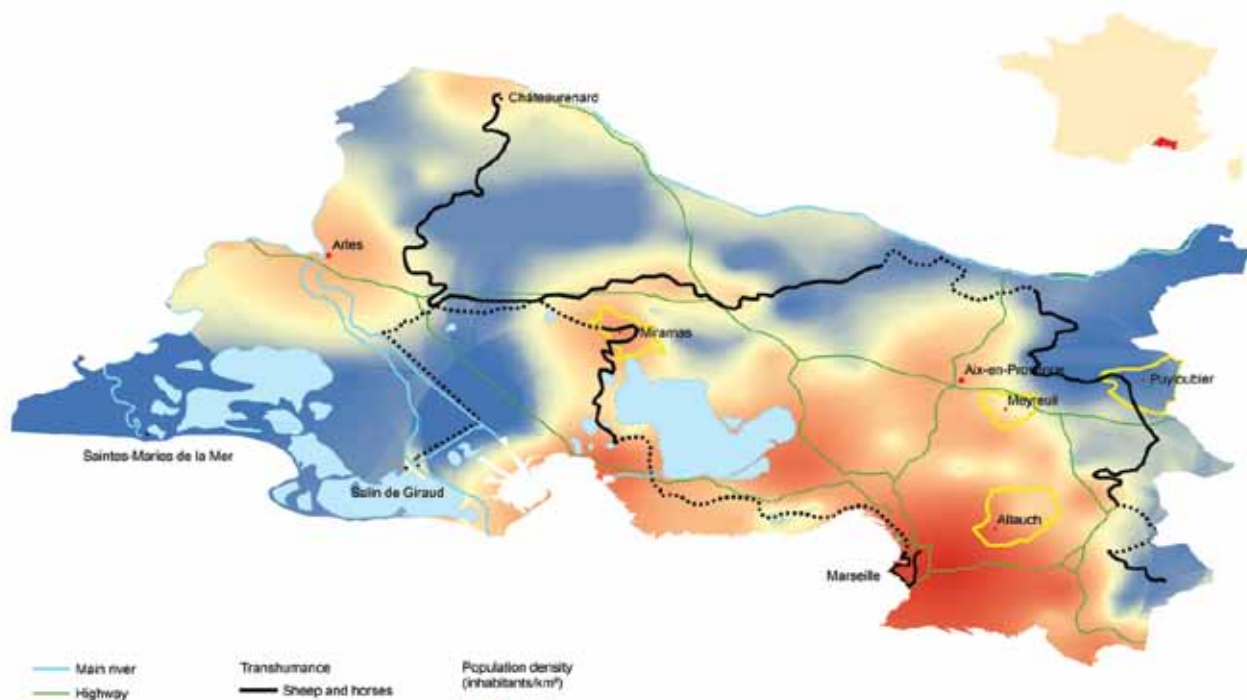


Figure. Map of *la Transhumance* routes and locations of *Oestrus ovis* ophthalmomyiasis case-patients in areas surrounding Marseilles, France, 2013. Inset shows location of the area in France. A color version of this figure is available online (<http://wwwnc.cdc.gov/EID/article/21/2/14-0974-F1.htm>).

The second case-patient was a retired female farmer, 67 years of age, living near Puylobier, 49 km (\approx 30 miles) north of Marseille, who reported being stung on the eye by an insect during the morning of July 6. In the afternoon, the eye became painfully inflamed. On the next day, an ophthalmologist performed an excision and extracted *O. ovis* larvae from the eye.

The third case-patient was a 43-year-old female nurse's aide residing in Meyreuil, which is \approx 30 km (\approx 18 mi) north of Marseille. On July 13, while she was on her terrace, she described ocular trauma by a fly. The next day, she sensed a foreign body in her eye, and she consulted an ophthalmologist. A simple excision led to the identification of an *O. ovis* larva.

The final case-patient was a 28-year-old male mason. On July 22, while working in Miramas, approximately 63 km (\approx 39 miles) he experienced trauma to his left eye. As the pain persisted, he consulted an ophthalmology facility that same evening. On examination, the presence of an *O. ovis* larva was confirmed, and an ablation was performed. All patients recovered without consequences.

O. ovis, also called sheep nasal botfly, is a fly of the class Insecta, order Diptera and family *Oestridae*. It is a cosmopolitan parasite that infects the nasal sinuses of sheep and goats. During the summer and early autumn, the adult female flies are active, laying and retaining eggs until

they hatch. The fly then ejects many first-instar larvae onto the nostril of the host. The *O. ovis* larvae grow in the mucus of the nasal sinus until mature; they are then released from the nostrils when the infected host sneezes (8). The larvae pupate in the soil for 4–8 weeks, form a chrysalis, in which they morph into adults, and then emerge. Occasionally, *O. ovis* can infest humans, which become an intermediate accidental host (7). The 4 cases of ophthalmomyiasis described in this report occurred in a restricted area during a 4-week period, which corresponds exactly to the time and location of *la Transhumance*, taking into account the 4- to 8-week time lag required for the maturation of larvae into adults. Three of these cases were directly referred to our laboratory, the regional referent parasitology laboratory. The fourth case was reported by an ophthalmology emergency unit. Note that ophthalmomyiasis is rare in Marseille; during the 5 years before *la Transhumance* of 2013, only a single case had been diagnosed in the area.

Overall, this report reminds us that bringing a large group of livestock into contact with a dense urban population may enhance the risk for transmission of zoonoses. The transmitted zoonosis in this case was oestrosis, a benign condition that can sometimes progress to blindness if untreated. However, other much more severe air-transmitted zoonotic diseases associated with sheep and goats, such as Q fever, could have been transmitted (9). Without questioning

the organization of such an event, which the community considers to be important from a cultural and economic point of view, public health authorities should consider and anticipate as much as possible the potential sanitary consequences of such a gathering and prepare medical staff for the potential occurrence of unfamiliar diseases.

References

1. Hunt EW Jr. Unusual case of ophthalmomyiasis interna posterior. *Am J Ophthalmol*. 1970;70:978–980.
2. Dunbar J, Cooper B, Hodgetts T, Yskandar H, van Thiel P, Whelan S, et al. An outbreak of human external ophthalmomyiasis due to *Oestrus ovis* in southern Afghanistan. *Clin Infect Dis*. 2008;46:e124–6. <http://dx.doi.org/10.1086/588046>
3. Sucilathangam G, Meenakshisundaram A, Hariramasubramanian S, Anandhi D, Palaniappan N, Anna T. External ophthalmomyiasis which was caused by sheep botfly (*Oestrus ovis*) larva: a report of 10 cases. *J Clin Diagn Res*. 2013;7:539–42. <http://dx.doi.org/10.7860/JCDR/2013/4749.2817>
4. Khurana S, Biswal M, Bhatti HS, Pandav SS, Gupta A, Chatterjee SS, et al. Ophthalmomyiasis: three cases from North India. *Indian J Med Microbiol*. 2010;28:257–61. <http://dx.doi.org/10.4103/0255-0857.66490>
5. Dono M, Bertoni MR, Poggi R, Teneggi E, Maddalo F, Via F, et al. Three cases of ophthalmomyiasis externa by sheep botfly *Oestrus ovis* in Italy. *New Microbiol*. 2005;28:365–8.
6. Çalışkan S, Ugurbas SC, Sağıdik M. Ophthalmomyiasis externa: three cases caused by *Oestrus ovis* larvae in Turkey. *Trop Doct*. 2014;44:230–2. <http://dx.doi.org/10.1177/0049475514531129>
7. Theodorides J. Considérations historiques sur les ophthalmomyiasis. *Bull Soc Fr Parasitol*. 1996;14:237–45 [cited 11 Dec 2014]. <http://cat.inist.fr/?aModele=afficheN&cpsidt=2596189>
8. Lloyd JE, Brewer MJ. Sheep bot fly, biology and management. Laramie (WY): Cooperative Extension Service, Dept. of Plant, Soil and Insect Sciences, College of Agriculture, University of Wyoming; 1992. p. 4 [cited 2014 Jun 2]. <http://www.wyomingextension.org/agpubs/pubs/B966.pdf>
9. Boden K, Brasche S, Straube E, Bischof W. Specific risk factors for contracting Q fever: lessons from the outbreak Jena. *Int J Hyg Environ Health*. 2014;217:110–5. <http://dx.doi.org/10.1016/j.ijheh.2013.04.004>

Address for correspondence: Renaud Piarroux, Laboratoire de Parasitologie, Centre Hospitalier Universitaire de La Timone, 264 rue Saint Pierre, 13385 Marseille CEDEX 5, France; email: renaud.piarroux@ap-hm.fr

PODCAST

Breathing Valley Fever

Dr. Duc Vugia, chief of the Infectious Diseases Branch in the California Department of Public Health, discusses Valley Fever.

<http://www2c.cdc.gov/podcasts/player.asp?f=8631241>

Meningococcal Disease in US Military Personnel before and after Adoption of Conjugate Vaccine

Michael P. Broderick, Christopher Phillips, Dennis Faix

Author affiliation: Naval Health Research Center, San Diego, California, USA

DOI: <http://dx.doi.org/10.3201/eid2102.141037>

To the Editor: Meningococcal disease in US military personnel is controlled by vaccines, the first of which was developed by the US Army (1–5). In 1985, the quadrivalent polysaccharide vaccine (MPSV-4) was implemented as the military standard. It was replaced during 2006–2008 by the quadrivalent conjugate vaccine (MCV-4). Every person entering US military service is required to receive this vaccine.

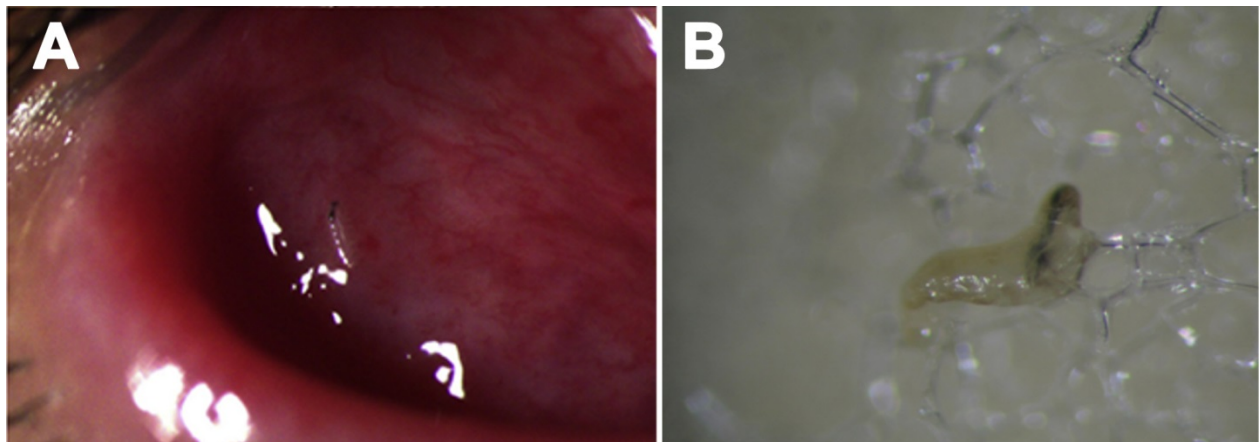
Meningococcal disease incidence in active-duty US military personnel, historically far above that in the general population (6), has decreased >90% since the early 1970s, when the first vaccine was introduced (7). Over the last 5 years, incidences in the military and US general populations have become equivalent (8). Here we update previously published data (8) from the Naval Health Research Center’s Laboratory-based Meningococcal Disease Surveillance Program of US military personnel. Data-gathering methods and laboratory analyses of samples from personnel suspected of having meningococcal disease have been previously described (8). Incidences were compared by using the New York State Department of Public Health Assessment Indicator based on the methods of Breslow and Day (9).

During 2006–2013 in US military personnel, only 1 of the 28 meningococcal disease cases for which serogroup data are available was not serogroups C or B (8 cases each) or Y (11 cases). During that period, incidence in US military personnel of 0.271 cases per 100,000 person-years did not differ significantly ($p>0.05$) from that of 0.238 in the 2006–2012 age-matched US general population (persons 17–64 years of age) (Centers for Disease Control and Prevention [CDC], unpub. data). During 2010–2013, meningococcal disease incidence in military personnel was 0.174 cases per 100,000 person-years, compared with 0.194 in the age-matched 2010–2012 US population. Among military personnel, only 1 case each occurred in 2011 (serogroup Y) and 2012 (serogroup B), and 3 occurred in 2013 (1 each of serogroups B, C, and Y).

To measure the relative success of the 2 vaccines, we compared incidence among military personnel who

Clustered Cases of *Oestrus ovis* Ophthalmomyiasis after Three-Week Festival, Marseille, France, 2013

Technical Appendix



Technical Appendix Figure. *Oestrus ovis* larva on the eye of case-patient 1 and after collection. A) *Fornix conjunctiva* of case-patient 1 showing chemosis (conjunctival edema) and larva of *Oestrus ovis*. B) Larva collected from *Fornix conjunctiva* on swab.