

Endemicity of *Opisthorchis viverrini* Liver Flukes, Vietnam, 2011–2012

To the Editor: Fishborne zoonotic trematodes are highly prevalent in many Asian communities (1,2). Although presence of the liver fluke *Clonorchis sinensis* is well documented in Vietnam (3), evidence of the presence of the more common liver fluke of Southeast Asia, *Opisthorchis viverrini*, is only circumstantial. Surveys of human fecal samples have frequently reported *O. viverrini* fluke eggs in humans in southern and central Vietnam (4); however, identifications based on fecal eggs are notoriously unreliable for differentiating species of liver and intestinal flukes (5). The few reports of surgical recovery of adult *O. viverrini* flukes from humans do not eliminate the possibility of infection having been acquired during travel in neighboring fluke-endemic countries.

Metacercariae from fish in the Mekong Delta have been tentatively identified as *Opisthorchis* spp., but this identity has not been confirmed (6). Specific identification is necessary for an understanding of the liver fluke diversity in Vietnam, especially because *O. lobatus* flukes, a related species that infects ducks, have been reported from nearby Laos (7).

To clarify the status of fishborne liver flukes in Vietnam, during 2011–2012, we conducted a survey for liver fluke metacercariae in fish from Phu Yen Province. We selected this province because the local populations have a strong preference for raw fish and because previous surveys of human fecal samples conducted there indicated high prevalence of fishborne parasites (4). We chose to investigate metacercariae in fish to avoid the uncertainty of identifications based on fecal eggs and because of the availability of recent molecular methods

for species identification of *Opisthorchis* fluke metacercariae (7).

Fish were collected from Tuy Hoa City and from the districts of Hoa Xuan Dong, Tuy An, and Song Hinh; these 3 districts are areas of large aquaculture production of freshwater fish. Fresh fish from ponds, rice fields, rivers, and swamps were purchased at local markets from April 2011 through March 2012. The fish sellers provided information about the source of the fish (e.g., type of water body). Fish were transported live with mechanical aeration to the Research Institute for Aquaculture No. 3 in Nha Trang, where they were examined for metacercariae by use of whole individual fish pepsin digestion (8).

Recovered metacercariae were examined microscopically, and those identified morphologically as *Opisthorchis* spp. flukes (9) were isolated. A subset of these metacercariae were fixed in 70% alcohol and examined by PCR and sequence analysis of the CO1 gene (7) at the Department of Helminthology, Mahidol University, Bangkok. For the purpose of obtaining adult worms, 3 hamsters were inoculated with the *Opisthorchis* metacercariae (15, 30, or 45 metacercariae/hamster). The adult worms were recovered from the infected hamsters 25–30 days after infection and were fixed and stained for morphologic determination of species (10).

A total of 4 fish species were infected with *O. viverrini* metacercariae (online Technical Appendix Table 1, wwwnc.cdc.gov/EID/article/20/1/13-0168-Techapp1.pdf). Metacercariae prevalence was highest (28.1%) among crucian carp (*Carasius auratus*). Specific identification was confirmed by morphologic appearance of adult worms recovered from hamsters (Figure) and PCR and sequence analysis of the partial metacercarial CO1 gene, amplified by CO1-OV-Hap-F&R primers (7). Infected fish originated predominantly from so-called wild water (i.e., swamps, rice fields, rivers). The prevalence of *O. viverrini* metacercariae in crucian carp varied seasonally (online Technical Appendix Table 2).

Crucian carp are cultured in some countries but not in Vietnam. However, the high prevalence and mean intensity of *O. viverrini* metacercariae (28.3 metacercariae/fish) is of public health concern because wild species such as crucian carp are often eaten raw, marinated, or lightly cooked. In contrast, infected barb (*Puntius brevis*) and rasbora (*Rasbora* spp.) fish (online Technical Appendix Table 1) are not eaten raw. However, barb fish are invasive in farm fish ponds and can persist as a self-recruiting species; the presence of barb is an indication that pond management is insufficient to prevent invasive species of fish. Furthermore, barb fish are often

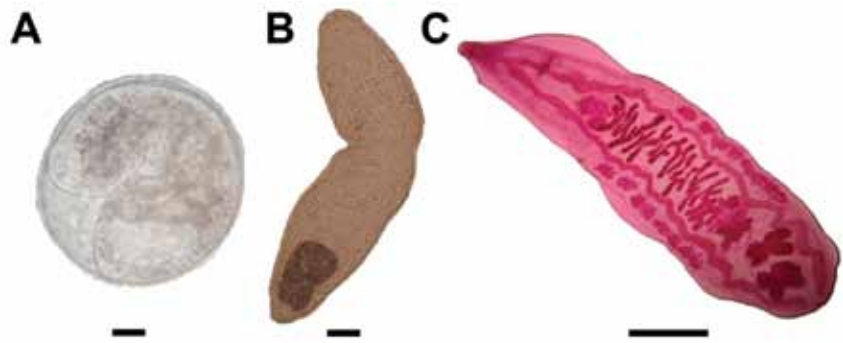


Figure. Morphologic appearance of different stages of *Opisthorchis viverrini* flukes. A) Encysted metacercariae. Scale bar indicates 30 μ m. B) Metacercariae released from cyst. Scale bar indicates 30 μ m. C) Adult worm from experimentally infected hamster. Scale bar indicates 1 mm.

fed to farm cats, which are major reservoir hosts for fishborne liver and intestinal trematodes. Infections (prevalence 8.3%) in snakehead fish (*Channa* spp.) also represent a food safety risk, because snakehead fish are cultured in Vietnam and are sometimes eaten raw or inadequately cooked. In addition to *O. viverrini* flukes, metacercariae of the zoonotic intestinal flukes *Centrocestus formosanus*, *Haplorchis tai-chui*, and *H. yokogawi* were recovered from snakehead and barb fish (online Technical Appendix Table 1), all of which are common throughout Southeast Asia (1).

The results of this study demonstrate that the human liver fluke *O. viverrini* is endemic to Vietnam and that it is being naturally transmitted to fish species that are often consumed raw or inadequately cooked. For determination of the prevalence, distribution, and epidemiology of *O. viverrini* flukes in fish, humans, and reservoir hosts (e.g., cats and dogs), these results need to be extended,

especially because aquaculture is a growing industry in Vietnam.

Acknowledgments

We thank Henry Madsen for his expert ecologic and malacologic advice, Jesper Clausen for his valuable assistance, PhanThi Van and Anders Dalsgaard for their strong support and advice, and the staff of the Research Institute for Aquaculture No.3 for their support and contributions in the field and laboratory.

This study is part of the research capacity building project “Fishborne Zoonotic Parasites in Vietnam” (www.fibozopa2.rial1.org; project no. 91140), financially supported by the Danish International Development Assistance.

**Vo The Dung, Jitra Waikagul,
Bui Ngoc Thanh,
Dung Thi Vo, Duy Nhat Nguyen,
and K. Darwin Murrell**

Author affiliations: Research Institute for Aquaculture No. 3, NhaTrang, Vietnam (V.T. Dung, D.T. Vo, D.N. Nguyen); Mahidol

University, Bangkok, Thailand (J. Waikagul); Research Institute for Aquaculture No. 1, Bac Ninh, Vietnam (B.N. Thanh); and University of Copenhagen, Copenhagen, Denmark (K.D. Murrell)

DOI: <http://dx.doi.org/10.3201/eid2001.130168>

References

1. Chai JY, Murrell KD, Lymbery AJ. Fish-borne parasitic zoonoses: status and issues. *Int J Parasitol.* 2005;35:1233–54. <http://dx.doi.org/10.1016/j.ijpara.2005.07.013>
2. Sithithaworn P, Andrews RH, Nguyen VD, Wongsaroj T, Sinuon M, Odermatt P, et al. The current status of opisthorchiasis and clonorchiasis in the Mekong Basin. *Parasitol Int.* 2012;61:10–6. <http://dx.doi.org/10.1016/j.parint.2011.08.014>
3. Trung Dung D, Van De N, Waikagul J, Dalsgaard A, Chai JY, Sohn WM, et al. Fishborne zoonotic intestinal trematodes in Vietnam. *Emerg Infect Dis.* 2007;13:1828–33. <http://dx.doi.org/10.3201/eid1312.070554>
4. De NV, Murrell KD, Cong le D, Cam PD, Chau le V, Toan ND, et al. The food-borne trematode zoonoses of Vietnam. *Southeastern Asian J Trop Med Public Health.* 2003;34(Suppl 1):12–34.

etymologia

Opisthorchis

[o"pis-thor'kis]

From the Greek *opisthen* (behind) and *orchis* (testicle), *Opisthorchis* is a genus of trematode flatworms whose testes are located in the posterior end of the body. Rivolta is generally credited with discovering the first opisthorchid, which he named *Distoma felineus*, in a cat in Italy in 1884. However, the fluke may have been mentioned by Rudolphi in 1819, and in 1831,

Sources

1. Bowman DD, Hendrix CM, Lindsay DS, Barr SC. Opisthorchidae. In: *Feline clinical parasitology*. Ames (IA): Iowa State University Press; 2002. p. 150–62.
2. *Dorland's Illustrated Medical Dictionary*. 32nd ed. Philadelphia: Elsevier Saunders; 2012.
3. Fantham HB, Stephens JWW, Theobald FV. The animal parasites of man. New York: William Wood and Company; 1920. p. 252.
4. Schuster RK. Opisthorchiidosis—a review. *Infect Disord Drug Targets.* 2010;10:402–15. <http://dx.doi.org/10.2174/187152610793180902>

Address for correspondence: Ronnie Henry, Centers for Disease Control and Prevention, 1600 Clifton Rd NE, Mailstop E03, Atlanta, GA 30333, USA; email: boq3@cdc.gov

DOI: <http://dx.doi.org/10.3201/eid2001.ET2001>

5. Ditrich O, Giboda M, Sterba J. Species determination of eggs of opisthorchiid and heterophyid flukes using scanning electron microscopy. *Angew Parasitol.* 1990;31:3–9.
6. Thu ND, Dalsgaard A, Loan IT, Murrell KD. Survey for zoonotic liver and intestinal trematode metacercariae in cultured and wild fish in An Giang Province, Vietnam. *Korean J Parasitol.* 2007;45:45–54. <http://dx.doi.org/10.3347/kjp.2007.45.1.45>
7. Thaenkham U, Nuamngong S, Vonghachack Y, Yoonuan T, Sangunkiat S, Dekumyoy P, et al. Discovery of *Opisthorchis lobatus* (Trematoda: Opisthorchiidae): new recorded species of small liver flukes in the greater Mekong sub-region. *J Parasitol.* 2011;97:1152–8. <http://dx.doi.org/10.1645/GE-2764.1>
8. Vo DT, Murrell D, Dalsgaard A, Bristow G, Nguyen DH, Bui TN, et al. Prevalence of zoonotic metacercariae in two species of grouper, *Epinephelus coioides* and *Epinephelus bleekeri*, and flathead mullet, *Mugil cephalus*, in Viet Nam. *Korean J Parasitol.* 2008;46:77–82. <http://dx.doi.org/10.3347/kjp.2008.46.2.77>
9. Scholz T, Ditrich O, Giboda M. Differential diagnosis of opisthorchiid and heterophyid metacercariae (Trematoda) infecting fish of cyprinid fish from Nam Ngum Dam. *Southeast Asian J Trop Med Public Health.* 1991;22:171–3.
10. Scholz T. Family Opisthorchiidae Looss, 1899. In: Bray RA, Gibson DI, Jones A, editors. *Keys to the trematoda*, volume 3. London: CAB International and Natural History Museum; 2008. p. 9–49.

Address for correspondence: K. Darwin Murrell, Department of Preventive Medicine and Biometrics, Uniformed Services University of the Health Sciences, 4301 Jones Bridge Rd, Bethesda, MD 20814, USA; email: kdmurrell@comcast.net

Foodborne Trematodiasis and *Opisthorchis felineus* Acquired in Italy

To the Editor: Opisthorchiasis comprises diverse clinical manifestations caused by infections with *Opisthorchis felineus* or *O. viverrini* liver flukes, which are transmitted by eating infected raw or undercooked fish and other aquatic products. In regions outside Western Europe where human opisthorchiasis is endemic, the disease is mainly described as being chronic and asymptomatic. Recent studies indicate cases of *O. felineus* infection in the Mediterranean region, particularly Italy (1–4). Patients with acute infection have signs/symptoms ranging from fever to hepatitis-like signs/symptoms (e.g., pain in upper right abdominal quadrant, weakness, fatigue, loss of appetite, diarrhea, weight loss); sign/symptom onset occurs \approx 2–3 weeks after infection, depending on the number of ingested flukes (2–4).

Acute opisthorchiasis is a feature of *O. felineus* infection that is not often reported for other trematode infections. Opisthorchiasis is characterized by hepatosplenomegaly, abdominal tenderness, eosinophilia, chills, and fever (2); left untreated, it can lead to obstructive jaundice, cholangitis, cholecystitis, and intra-abdominal masses (1,2,4).

Transmission of *O. viverrini* mainly occurs in Southeast Asia, but *O. felineus* transmission expands further westward to parts of Western and Central Eurasia (1,2,4). Recent outbreaks of *O. felineus* infection have been described in Italy (5–7). In 2010, two travelers from the Netherlands who ate raw tench near Lake Bolsena in Tuscany, Italy, were infected (8). We describe 3 additional cases of *O. felineus* infection in Dutch travelers who ate raw fish near Lake Bolsena.

In August 2011, a 54-year-old woman in the Netherlands with no relevant medical history sought medical care for fever, chills, and myalgia lasting 2 weeks. Symptoms began after the patient returned from a vacation in Tuscany. Physical examination showed no abnormalities; her temperature was 37.4°C. Laboratory examinations showed eosinophilic leukocytosis, an elevated C-reactive protein level, and elevated liver enzyme levels (Table).

Opisthorchiasis was suspected because of the patient's travel history and report of eating carpaccio (Italian dish made with raw fish/meat) near Lake Bolsena (8). A fecal sample examined by microscopy was negative for eggs, cysts, and helminths. A serum sample was tested at Leiden University Medical Center by using an in-house immunofluorescence assay and ELISA with *Fasciola* spp. antigens, which are likely to show cross-reactivity with other liver flukes (9). The immunofluorescence assay result was positive, but the ELISA result was negative.

To confirm the diagnosis of opisthorchiasis, we obtained another fecal sample 1 month later, and low numbers of *Opisthorchis* eggs were seen by microscopy. The sample was sent to Leiden University Medical Center, where in-house real-time PCR was performed using primers (Of350F 5'-CTC CGT TGT TGG TCC TTT GTC-3' and Of418R 5'-AAA CAG ATT TGC ATC GAA TGC A-3') and a detection probe (Opis372 FAM-5'-TGC CAA CAC TGG AGC CTC AAC CAA-3'-BHQ1) designed from the *O. felineus* internal transcribed spacer 2 sequence (GenBank accession no. DQ513407). This PCR amplifies and detects a 69-bp fragment within the *O. felineus* internal transcribed spacer 2 sequence. Simultaneous isolation, amplification, and detection of a standard amount of phocid herpesvirus were used for internal control of inhibition (10). The *O. felineus* real-time PCR was positive (cycle threshold 24.7).

**EMERGING
INFECTIOUS DISEASES**

Free Online RSS Feed

in PubMed Central

Ahead of print

CME Peer-Review

podcasts

GovDelivery



Endemicity of *Opisthorchis viverrini* Liver Flukes, Vietnam, 2011–2012

Technical Appendix

Technical Appendix Table 1. Prevalence and intensity of *Opisthorchis viverrini* fluke metacercariae in fish collected in several districts of Phu Yen province, Vietnam

Fish species	Collection site district/commune	Prevalence, % (No. infected/total no. examined)	Infection intensity (metacercariae/fish)	Type of water body	Other zoonotic metacercaria infections*
Crucian carp (<i>Carasius auratus</i>)	Tuy An /An My	28.1 (72/256)	28.2 ±29.5	Swamp	None seen
Snakehead (<i>Channa</i> spp.)	Dong Hoa / Hoa Xuan Dong	8.3 (1/12)	1.0**	Rice field	<i>Centrocestus formosanus</i>
Rasbora (<i>Rasbora</i> spp.)	Dong Hoa / Hoa Xuan Dong	4.3 (1/23)	2.0	Rice field	None seen
Barb (<i>Puntius brevis</i>)	Dong Hoa / Hoa Xuan Dong	50.0 (1/2)	1.0±1.4	Pond	<i>Haplorchis taichui</i> and <i>H. yokogawai</i>
	Tuy An/Chi Thanh	60.0 (3/5)	2.7 ± 0.6	River	<i>C. formosanus</i> , <i>H. taichui</i> and <i>H. yokogawai</i>
	Tuy An/An My	100.0† (1/1)	2.0	Swamp	<i>H. taichui</i> and <i>H. yokogawai</i>

*No determination of prevalence or intensity was made.

†Based on 1 infected fish.

Technical Appendix Table 2. Prevalence of *Opisthorchis viverrini* fluke metacercariae in crucian carp collected monthly in An My commune, Tuy An district, Vietnam

Date	No. fish examined/no. fish infected	% Fish infected
2011		
Apr	83/0	0
May	17/5	29.4
Jun	21/3	14.3
Nov	41/6	14.6
2012		
Jan	38/2	5.3
Mar	56/56	100