

Powassan Meningoencephalitis, New York City, USA

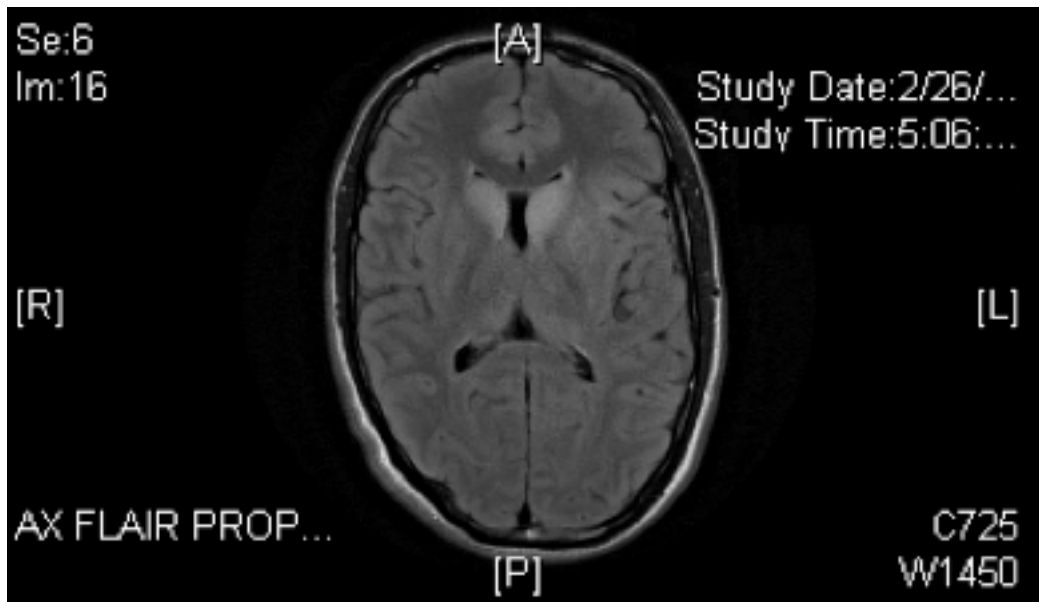
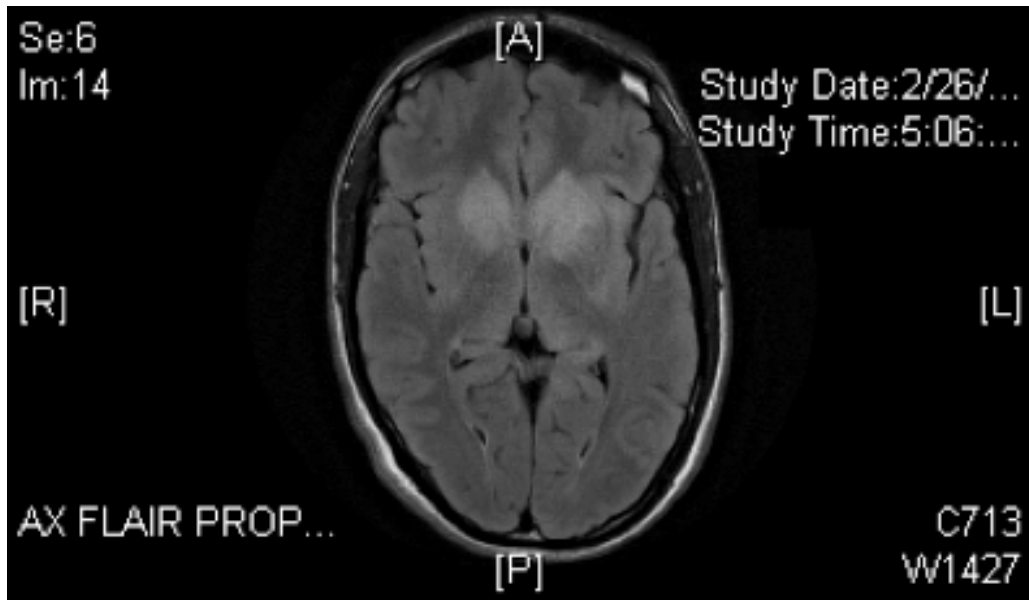
Technical Appendix

Technical Appendix Table. Results of laboratory diagnostic tests on CSF and serum for 2 patients with Powassan virus infection, New York City, New York, USA"

| Test | Patient 1 | Patient 2 |
|-----------------------------------|-----------|-----------|
| CSF PCR | - | - |
| Adenovirus | - | ND |
| Enterovirus | - | - |
| Ehrlichia | - | - |
| Epstein-Barr virus | - | - |
| Herpes simplex virus 1 and 2 | - | - |
| Human herpesvirus-6 | - | - |
| Varicella-zoster virus | - | - |
| CSF culture | - | - |
| Bacteria | - | - |
| Fungi | - | - |
| <i>Mycobacterium tuberculosis</i> | - | - |
| CSF cryptococcus antigen | ND | - |
| Serum antibody test | - | - |
| <i>Anaplasma phagocytophilum</i> | - | ND |
| HIV | - | - |
| <i>Babesia</i> IgG, IgM | ND | - |
| Cytomegalovirus IgG | - | - |
| <i>Ehrlichia chaffeensis</i> IgG | - | - |

*CSF, cerebrospinal fluid; -, negative; ND, not done; + positive.

Technical Appendix Figure 1. Patient 1: Magnetic resonance imaging FLAIR/T2 showing (A) bilateral basal ganglia and (B) caudate hyperintensities. FLAIR, fluid attenuated inversion recovery.



Technical Appendix Figure 2. Patient 2: Magnetic resonance imaging FLAIR/T2 showing bilateral temporal hyperintensities. FLAIR, fluid attenuated inversion recovery.

