

2012 probably represent only the so-called tip of the iceberg. Nevertheless, PCR analysis to detect Schmallenberg virus in samples from animals with clinical signs is a valuable method for identifying first cases in areas where Schmallenberg virus infections have not previously been found.

Acknowledgment

We gratefully acknowledge the farmers, diagnosticians in the regional laboratories, and veterinary officials who provided data on reemerging Schmallenberg virus cases.

Franz J. Conraths, Doris Kämer, Kathrin Teske, Bernd Hoffmann, Thomas C. Mettenleiter, and Martin Beer

Author affiliations: Friedrich-Loeffler-Institut, Greifswald-Insel-Riems, Germany

DOI: <http://dx.doi.org/10.3201/eid1903.121324>

References

- Hoffmann B, Scheuch M, Höper D, Jungblut R, Holsteg M, Schirmeier H, et al. Novel orthobunyavirus in cattle, Europe, 2011. *Emerg Infect Dis.* 2012;18:469–72 <http://dx.doi.org/10.3201/eid1803.111905>.
- Garigliany MM, Bayrou C, Kleijnen D, Cassart D, Desmecht D. Schmallenberg virus in domestic cattle, Belgium, 2012. *Emerg Infect Dis.* 2012;18:1512–4 <http://dx.doi.org/10.3201/eid1809.120716>.
- Muskens J, Smolenaars AJ, van der Poel WH, Mars MH, van Wuijckhuise L, Holzhauer M, et al. [Diarrhea and loss of production on Dutch dairy farms caused by the Schmallenberg virus]. [in Dutch] *Tijdschr Diergeneeskd.* 2012;137:112–5.
- Elbers AR, Loeffen WL, Quak S, de Boer-Luijtz E, van der Spek AN, Bouwstra R, et al. Seroprevalence of Schmallenberg virus antibodies among dairy cattle, the Netherlands, winter 2011–2012. *Emerg Infect Dis.* 2012;18:1065–71 <http://dx.doi.org/10.3201/eid1807.120323>.
- European Food Safety Authority. “Schmallenberg” virus: analysis of the epidemiological data and impact assessment. *EFSA Journal.* 2012;10: 2768. doi:10.2903/j.efsa.2012.2768. www.efsa.europa.eu/efsajournal.
- World Organisation for Animal Health. OIE technical factsheet, May 2012 [cited 2013 Jan 3]. 1. Schmallenberg virus. www.oie.int/.../A_Schmallenberg_virus.pdf
- Ducomble T, Wilking H, Stark K, Takla A, Askar M, Schaade L, et al. Lack of evidence for Schmallenberg virus infection in highly exposed persons, Germany, 2012. *Emerg Infect Dis.* 2012;18:1333–5 <http://dx.doi.org/10.3201/eid1808.120533>.
- Rasmussen LD, Kristensen B, Kirkeby C, Rasmussen TB, Belsham GJ, Bødker R, et al. Culicoids as vectors of Schmallenberg virus. *Emerg Infect Dis.* 2012;18:1204–6 <http://dx.doi.org/10.3201/eid1807.120385>.
- Bilk S, Schulze C, Fischer M, Beer M, Hlinak A, Hoffmann B. Organ distribution of Schmallenberg virus RNA in malformed newborns. *Vet Microbiol.* 2012;159:236–8. <http://dx.doi.org/10.1016/j.vetmic.2012.03.035>

Address for correspondence: Franz J. Conraths, Friedrich-Loeffler-Institut, Federal Research Institute for Animal Health—Institute of Epidemiology, Seestrass 55, Wusterhausen 16868, Germany; email: Franz.Conraths@fli.bund.de

Peritoneal Tuberculosis in a Pregnant Woman from Haiti, United States

To the Editor: A 29-year-old woman at 23 weeks’ gestation during her first pregnancy came to our hospital’s obstetrics clinic after 6 days of vaginal bleeding and abdominal pain. She had not experienced fever, sweats, weight loss, contractions, or other symptoms. She was otherwise healthy; she was taking no medications, but was taking iron and multi-vitamin supplements. She had legally immigrated to the United States from Haiti 8 months previously and had no known tuberculosis contacts. Physical examination disclosed brown vaginal discharge and a closed cervix. Obstetric ultrasound was normal, and vaginal swab samples were negative for *Neisseria gonorrhoea* and *Chlamydia trachomatis*.

Over the ensuing 2 weeks, her vaginal bleeding and abdominal pain worsened. She was admitted to the hospital. Physical examination revealed vaginal bleeding, but her condition was otherwise unchanged. Routine laboratory studies were normal. Repeat obstetric ultrasound showed a viable fetus, ascites, and a 15 × 15 × 3–cm rind of echogenic material anterior to the uterus. This abnormality was in the upper abdomen, an area not imaged on her previous ultrasound. Abdominal magnetic resonance imaging revealed moderate ascites and a 21 × 14 × 3–cm omental mass of intermediate intensity on T1 and T2 sequences; there was no lymphadenopathy (Figure). A tiny left pleural effusion was seen on chest radiograph. Routine HIV and tuberculin skin test results had been negative 4 months previously, and pre-immigration examination results and chest radiograph had been normal.

Fine-needle aspiration of the omental mass was nondiagnostic. The patient’s vaginal bleeding and abdominal pain persisted, and her cervix dilated. She had an oral temperature of 38.9° Celsius. Exploratory laparotomy demonstrated a friable omental mass with implants on the small bowel; a partial omentectomy was performed at 26 weeks’ gestation. During this procedure, the patient gave birth to a male infant.

Multiple granulomata, some containing acid-fast bacilli, were identified upon histologic examination of the omentum (Technical Appendix Figure, wwwnc.cdc.gov/EID/article/19/3/12-1109-Techapp1.pdf). Transcription-mediated amplification of the specimen was positive for *Mycobacterium tuberculosis* rRNA; cultures later grew *M. tuberculosis* susceptible to all first-line antituberculosis medications. Sputum smears and cultures were not performed. The patient’s treatment began with isoniazid, rifampin, ethambutol, and pyrazinamide; her fevers and abdominal pain

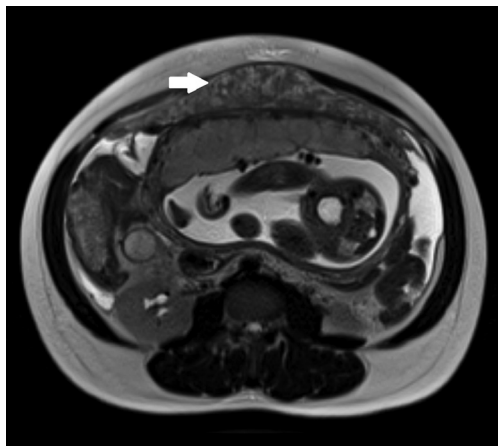


Figure. T2-weighted magnetic resonance imaging sequence of the abdomen of a pregnant woman from Haiti. An omental mass of intermediate intensity (white arrow) is shown anterior to the uterus.

resolved. Her son was admitted to the neonatal intensive care unit and was placed on antimycobacterial therapy. He also recovered and was discharged after 135 days.

This case highlights several issues related to tuberculosis epidemiology and diagnosis. Although pulmonary disease is the most common manifestation of tuberculosis overall, extrapulmonary tuberculosis accounts for a significant and increasing proportion of cases in the United States (1). Pregnancy is associated with greater likelihood of extrapulmonary disease; extrapulmonary infection accounts for 13% of all cases worldwide (2) but 50% of cases in pregnancy, according to a recent study (3).

The frequency of peritoneal tuberculosis in pregnancy is unknown; few cases have been reported in the literature (4–7), although we know of 3 additional cases from Haiti (online Technical Appendix Table). However, cases are likely underdiagnosed or diagnosed late in the course of illness. Underdiagnosis and delayed diagnosis may be caused by the nonspecific nature of symptoms, commonly abdominal pain and ascites, which can be attributed to pregnancy itself or obstetrical complications. These erroneous explanations for symptoms are reflected in this patient, whose symptoms were initially attributed to abortion and who was not diagnosed with

tuberculosis until >3 weeks after seeking medical assistance. Such delays in diagnosis are typical of peritoneal tuberculosis and are associated with increased death rates (8). In many cases, clinical features cannot distinguish peritoneal tuberculosis from malignancy, necessitating more extensive evaluation (7).

Failure to diagnose peritoneal tuberculosis, in pregnancy or otherwise, might also stem from the insensitivity of noninvasive diagnostic testing. Paracentesis with acid-fast staining detects only a minority of cases (8). The sensitivity of mycobacterial cultures of ascites fluid varies, and culture results are often not available for weeks (8). Ascites fluid adenosine deaminase has shown promise as a reliable, minimally invasive diagnostic test in resource-poor countries, but was insensitive in a United States study (9). In addition, although tuberculin skin testing and interferon gamma release assay performance are not affected by pregnancy (10), neither can distinguish active from latent infection. Without diagnostic clinical features or sensitive noninvasive tests, the diagnosis of peritoneal tuberculosis might only be confirmed through laparoscopy or laparotomy, as in our case. Such invasive testing methods and facilities, equipment, and personnel might not be readily available in resource-poor settings.

This case also illustrates the ongoing threat of tuberculosis in countries of all income levels. It is not clear where our patient contracted tuberculosis; she was most likely exposed in Haiti, but transmission within her Haitian community in the United States, or from another source, is also possible. Regardless, as in her case, a majority of tuberculosis cases within the United States occur in foreign-born persons. Given the ease and frequency of travel, lapses in tuberculosis control in any locale are likely to have effects more broadly. Wherever they work, clinicians must maintain vigilance for tuberculosis in all of its protean forms.

Acknowledgements

The authors thank Walter Pieciak and Andrew Onderdonk for providing the molecular diagnostic testing used for this patient.

**Kevin L. Ard, Brian T. Chan,
Danny A. Milner, Jr.,
Paul E. Farmer, and
Serena P. Koenig**

Affiliations: Brigham and Women's Hospital, Boston, Massachusetts, USA (K.L. Ard, B.T. Chan, D.A. Milner Jr, P.E. Farmer, S.P. Koenig); and Massachusetts General Hospital, Boston (K.L. Ard, B.T. Chan)

DOI: <http://dx.doi.org/10.3201/eid1903.121109>

References

- Albalak R, O'Brien RJ, Kammerer JS, O'Brien SM, Marks SM, Castro KG, et al. Trends in tuberculosis/human immunodeficiency virus comorbidity, United States, 1993–2004. *Arch Intern Med.* 2007;167:2443–52. <http://dx.doi.org/10.1001/archinte.167.22.2443>
- World Health Organization. Global Tuberculosis Control: WHO Report 2011. 2011 [cited 2012 Dec 5]. http://www.who.int/tb/publications/global_report/2011/gtbr11_full.pdf.
- Knight M, Kurinczuk JJ, Nelson-Piercy C, Spark P, Brocklehurst P. Tuberculosis in pregnancy in the UK. *BJOG.* 2009;116:584–8. <http://dx.doi.org/10.1111/j.1471-0528.2008.02097.x>

4. Coden J. Tuberculous peritonitis in pregnancy. *BMJ*. 1972;3:153. <http://dx.doi.org/10.1136/bmj.3.5819.153>
5. Brooks JH, Stirrat GM. Tuberculous peritonitis in pregnancy. Case report. *Br J Obstet Gynaecol*. 1986;93:1009–10. <http://dx.doi.org/10.1111/j.1471-0528.1986.tb08027.x>
6. Lee GS, Kim SJ, Park IY, Shin JC, Kim SP. Tuberculous peritonitis in pregnancy. *J Obstet Gynaecol Res*. 2005;31:436–8. <http://dx.doi.org/10.1111/j.1447-0756.2005.00316.x>
7. Sakorafas GH, Ntatzikos A, Konstantiadou I, Karamitopoulou E, Kavatha D, Peros G. Peritoneal tuberculosis in pregnancy mimicking advanced ovarian cancer: a plea to avoid hasty, radical and irreversible surgical decisions. *Int J Infect Dis*. 2009;13:e270–2. <http://dx.doi.org/10.1016/j.ijid.2008.11.003>
8. Chow KM, Chow VC, Hung LC, Wong SM, Szeto CC. Tuberculous peritonitis-associated mortality is high among patients waiting for the results of mycobacterial cultures of ascitic fluid samples. *Clin Infect Dis*. 2002;35:409–13. <http://dx.doi.org/10.1086/341898>
9. Hillebrand DJ, Runyon BA, Yasmineh WG, Rynders GP. Ascitic fluid adenosine deaminase insensitivity in detecting tuberculous peritonitis in the United States. *Hepatology*. 1996;24:1408–12. <http://dx.doi.org/10.1002/hep.510240617>
10. Lighter-Fisher J, Surette AM. Performance of an interferon-gamma release assay to diagnose latent tuberculosis infection during pregnancy. *Obstet Gynecol*. 2012;119:1088–95. <http://dx.doi.org/10.1097/AOG.0b013e3182546aff>

Address for correspondence: Kevin L. Ard, Brigham and Women's Hospital; 75 Francis St, PBB-A4, Boston, MA 02115, USA; email: kard@partners.org

Microsporidial Keratoconjunctivitis Outbreak among Athletes from Hong Kong Who Visited Singapore, 2012

To the Editor: An international outbreak of microsporidial keratoconjunctivitis related to soil contact in a Singapore sport venue during April was

reported to Hong Kong Department of Health, People's Republic of China, in May 2012. Microsporidia are obligate intracellular, unicellular, eukaryotic, parasitic protists related to fungi (1). Fourteen species of microsporidia have been detected in humans (1). Several species of microsporidia, such as *Vittaforma corneae*, can cause keratoconjunctivitis (1). An increasing incidence of microsporidial keratitis in Singapore that is strongly correlated with exposure to soil was reported during 2004–2007 (2). In a case series of 22 patients during 2006–2008 in Singapore, soil or mud were reported as predominant ocular contaminants that were contacted by athletes during sporting activities, such as playing rugby in muddy fields (3).

The outbreak reported in May 2012 affected 34 (41%) of 82 rugby players from Hong Kong who had participated in a rugby tournament in Singapore during April 21–22, 2012. In addition to the affected athletes from Hong Kong, there were 89, 15, 13, and 9 affected players, respectively, from Singapore, Malaysia, Australia, and United Arab Emirates (4). We conducted a retrospective cohort study among players from Hong Kong to identify potential risk and preventive factors for microsporidial keratoconjunctivitis.

The rugby tournament involved ≈1,600 boys and girls from 16 rugby clubs in Singapore, Hong Kong, Malaysia, Australia, and the United Arab Emirates. We invited 82 boys (8–16 years of age) from 2 Hong Kong rugby clubs that participated in the tournament to participate in telephone interviews during May 18–25, 2012. Using a standardized questionnaire, we collected information describing demographics and potential risk and preventive factors. We defined a case-patient as any player who had eye redness and 1 of the following ocular signs or symptoms since April 21: pain, discharge, swelling, or itchiness.

We interviewed 73 (89%) of the 82 players: 34 (47%) met the case definition. The median age of case-patients was 13 years (range 9–16 years); these figures were not different from those of the cohort (median age 13 years, range 8–16 years).

Onset of the reported 34 cases ranged from April 26 through May 22, peaking on May 7 (Figure). The distribution of onset of cases over time indicates a point-source outbreak and reflects a wide range of incubation periods. Symptom onset occurred a median of 15 days (range 5–31 days) after opening day of the tournament.

Except for 2 players who had histories of asthma, all players reported good past health. Ocular signs and symptoms of the 34 case-patients were redness (100%), pain (53%), itchiness (53%), discharge (47%), and swelling (41%). Corneal scraping samples from 3 players were positive for *V. corneae* by PCR.

Heavy rainfall on playing fields was reported on April 21, when all the players from Hong Kong participated in the games and were exposed to soil and muddy water. Some players washed their eyes after exposure to the dirt in the field. We identified the following as preventive factors for keratoconjunctivitis: individual eye washing by bottled or tap water (relative risk [RR] 0.38, 95% CI 0.23–0.62), bottled water (RR 0.44, 95% CI 0.25–0.76) and tap water (RR 0.50, 95% CI 0.27–0.92). Group eye washing with water from a hose held by a trainer was not preventive. It is possible that individual eye washing by the players was more thorough.

The 47% attack rate among the players from Hong Kong is higher than the overall 10% (160/1,600) attack rate for tournament participants. Rugby players from Hong Kong might have been less aware of the risk of contracting microsporidial keratoconjunctivitis through soil or muddy water exposure than were players from other locations.

Peritoneal Tuberculosis in a Pregnant Woman from Haiti, United States

Technical Appendix

Technical Appendix Table. Cases of peritoneal tuberculosis in pregnancy from published reports and the authors' clinical experience*

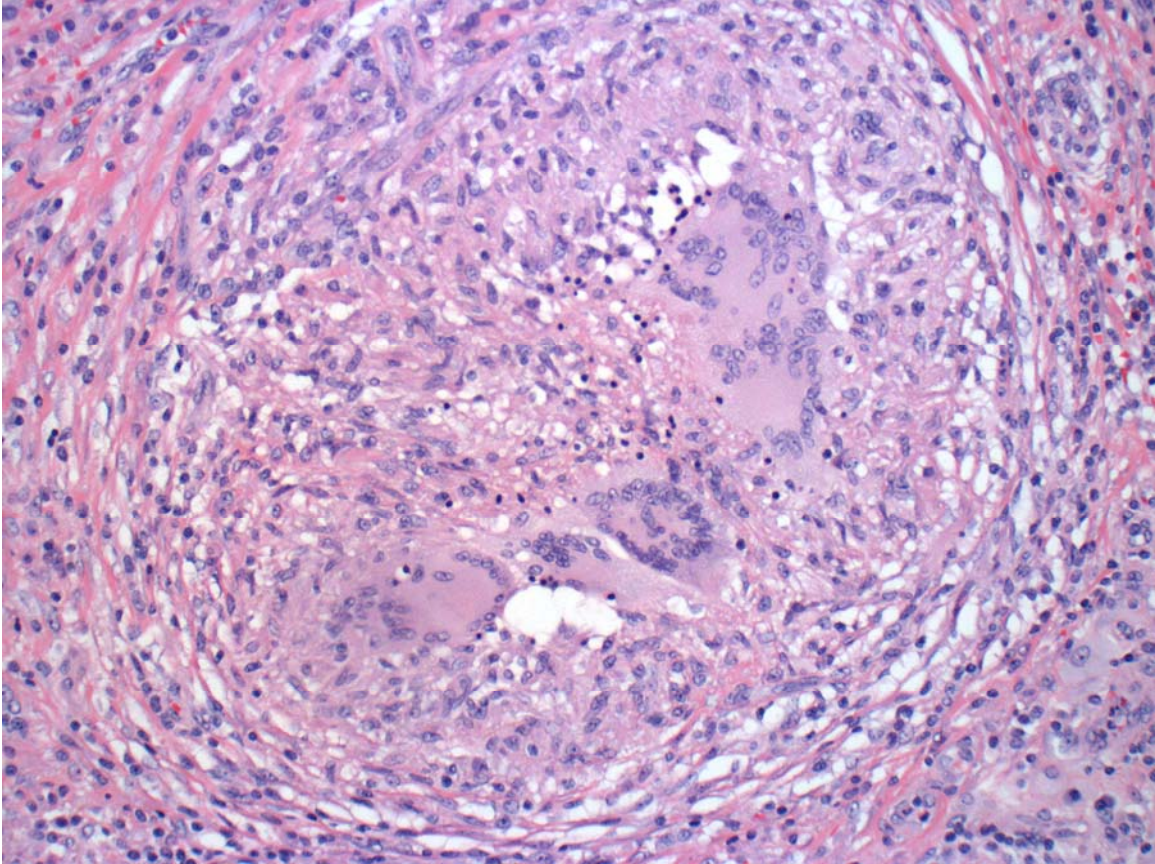
Reference or source	Patient age at presentation, y	Country or region of origin	Symptoms	Duration of illness prior to diagnosis	Diagnostic tests and findings	Pregnancy outcome
Present case	29	Haiti	Vaginal bleeding, abdominal pain, fever	3 wk	MRI of omental mass, granulomata and AFB on omental pathology, positive nucleic acid amplification and omental cultures	Birth at 26 weeks gestation; male infant survived
Case-patient from Haiti #1	20	Haiti	Foul vaginal discharge, abdominal pain, fever	Unknown	Granulomata on placental, uterine, and omental pathology; negative tissue AFB stain	Stillborn child; gestational age unknown; patient had hysterectomy
Case-patient from Haiti #2	26	Haiti	Cough, weight loss, abdominal swelling, fever	Unknown	Clinical diagnosis after response to a therapeutic trial of antitubercular drugs	Birth at 29 weeks gestation; male infant survived
Case-patient from Haiti #3	28	Haiti	Vaginal discharge, abdominal pain, fever	Unknown	Granulomata on placental, uterine, and omental pathology; negative tissue AFB stain	Birth at 28 weeks gestation; female infant died
Coden, 1972 (1)	26	Unknown	Abdominal pain, vomiting, anorexia, fever	6 mo	Positive ascites fluid culture for <i>M. tuberculosis</i> ; therapeutic trial of antitubercular drugs	Term birth; male infant survived
Brooks and Stirrat, 1986 (2)	25	Caribbean	Weight loss, nausea, vomiting, fever	Wk, unknown, <1 mo	Ascites fluid AFB stain and culture negative, omental pathology with AFB	Birth at 33 weeks gestation; male infant survived
Lee, 2005 (3)	23	South Korea	Ascites, fever	Unknown	Ascites fluid adenosine deaminase 70 U/L, serum CA-125 372 IU/mL, negative ascites fluid AFB stain and culture, MRI with omental cake, granulomata and AFB on omental pathology	Birth at 37 weeks gestation; male infant survived

Reference or source	Patient age at presentation, y	Country or region of origin	Symptoms	Duration of illness prior to diagnosis	Diagnostic tests and findings	Pregnancy outcome
Sakorafas, 2009 (4)	28	Ethiopia	Abdominal pain, nausea, vomiting, fever	Mo, unknown	Serum CA-125 163 IU/mL, ascites fluid AFB stain and culture negative, granulomata on peritoneal pathology, peritoneal biopsy cultures positive for <i>M. tuberculosis</i>	Pregnancy without other complications; otherwise, details unknown

* Published reports are limited to those in English. MRI, magnetic resonance imaging; AFB, acid-fast bacilli.

References

1. Coden J. Tuberculous peritonitis in pregnancy. *BMJ*. 1972;3:153. [PubMed](#)
<http://dx.doi.org/10.1136/bmj.3.5819.153>
2. Brooks JH, Stirrat GM. Tuberculous peritonitis in pregnancy. Case report. *Br J Obstet Gynaecol*. 1986;93:1009–10. [PubMed](#) <http://dx.doi.org/10.1111/j.1471-0528.1986.tb08027.x>
3. Lee GS, Kim SJ, Park IY, Shin JC, Kim SP. Tuberculous peritonitis in pregnancy. *J Obstet Gynaecol Res*. 2005;31:436–8. [PubMed](#) <http://dx.doi.org/10.1111/j.1447-0756.2005.00316.x>
4. Sakorafas GH, Ntavatzikos A, Konstantiadou I, Karamitopoulou E, Kavatha D, Peros G. Peritoneal tuberculosis in pregnancy mimicking advanced ovarian cancer: a plea to avoid hasty, radical and irreversible surgical decisions. *Int J Infect Dis*. 2009;13:e270–2. [PubMed](#) <http://dx.doi.org/10.1016/j.ijid.2008.11.003>



Technical Appendix Figure. Hematoxylin and eosin–stained tissue from the patient’s omental biopsy, demonstrating necrotizing granulomata. Acid-fast stains of the specimen showed rare acid-fast bacilli. Original magnification $\times 400$.