

Experimental Infection of Mink with SARS-CoV-2 Omicron Variant and Subsequent Clinical Disease

Jenni Virtanen,¹ Kirsi Aaltonen,¹ Kristel Kegler, Vinaya Venkat, Thanakorn Niamsap, Lauri Kareinen, Rasmus Malmgren, Olga Kivelä, Nina Atanasova, Pamela Österlund, Teemu Smura, Antti Sukura, Tomas Strandin, Lara Dutra, Olli Vapalahti, Heli Nordgren, Ravi Kant, Tarja Sironen

Author affiliations: University of Helsinki, Helsinki, Finland (J. Virtanen, K. Aaltonen, K. Kegler, V. Venkat, T. Niamsap, L. Kareinen, R. Malmgren, O. Kivelä, N. Atanasova, T. Smura, A. Sukura, T. Strandin, L. Dutra, O. Vapalahti, H. Nordgren, R. Kant, T. Sironen); Finnish Meteorological Institute, Helsinki (N. Atanasova); Finnish Institute for Health and Welfare, Helsinki (P. Österlund); Helsinki University Hospital, Helsinki (O. Vapalahti)

DOI: <https://doi.org/10.3201/eid2806.220328>

We report an experimental infection of American mink with SARS-CoV-2 Omicron variant and show that mink remain positive for viral RNA for days, experience clinical signs and histopathologic changes, and transmit the virus to uninfected recipients. Preparedness is crucial to avoid spread among mink and spillover to human populations.

SARS-CoV-2 has been detected in farmed and feral American mink (*Neovison vison*) in multiple countries, and extensive environmental contamination and human-to-mink and mink-to-human transmission has been documented (1–5). These factors have led to strict measures in mink farms and mink-farming countries to prevent the spread of the disease. In late 2021, a new SARS-CoV-2 variant (Omicron), characterized by possibly milder symptoms and more efficient human-to-human transmission, was detected, but its infectivity and spread in American mink is unknown (6,7).

We tested the response of American mink to the Omicron variant by infecting 3 male mink intranasally with 4×10^5 plaque-forming units of the virus (Appendix, <https://wwwnc.cdc.gov/EID/article/28/6/22-0328-App1.pdf>). We conducted follow-up on infected mink for 7 days and performed histopathologic evaluation of upper and lower respiratory tracts on the last day of follow-up. We sampled saliva daily.

All experimentally infected mink showed mild to moderate signs of illness, including lethargy, anorexia, diarrhea, nasal and lacrimal discharge, and sneezing. Consistent with earlier experiments with other variants (8; D. Adney et al., unpub. data, <https://www.biorxiv.org/content/10.1101/2022.01.20.477164v1>), saliva samples tested PCR-positive 1 day postinfection (dpi) and remained that way throughout follow-up (Table; Appendix). Infectious virus was cultured 1–3 dpi. Even though some of the clinical signs could be caused by other factors, such as stress from the change of environment, their consistency with signs seen in studies of other variants, combined with PCR results, demonstrate that the Omicron variant also causes clinical disease in mink.

To study whether mink can transmit the virus, we placed 2 uninfected indirect contact mink in separate cages 10–20 cm from the cages of the infected mink and followed their progress for 10 days. Similar signs to the experimentally infected mink developed in both initially uninfected mink, and they were consistently PCR-positive from day 3 onward (Table), indicating mink-to-mink transmission. Infectious virus was detected in cell culture even before it was detected by PCR. Even though no evidence of mink-to-human transmission of the Omicron variant exists, it seems possible on the basis of our results and the information from studies of other variants.

Gross findings in the nasal cavity and lungs were subtle in both experimentally infected and recipient mink and consisted of hyperemia of respiratory mucosa with small amounts of viscous exudate and non-collapsed, dark-red, and wet pulmonary lobes. All mink showed histopathologic changes in the upper and lower respiratory tracts (Figure). We observed multifocal degeneration and loss of respiratory epithelium with variable mucosal and submucosal neutrophilic infiltration in the nose. The lumen contained sloughed epithelial cells, mucinous material, and degenerated neutrophils (Figure, panels A, C). Viral nucleoprotein was widely distributed beyond intact cells, within sloughed cells, and in mucosal respiratory epithelium (Figure, panels B, D). The olfactory epithelium was inconsistent and mildly affected with only focal viral antigen detection. Unlike in some experimental infections reported in rodents, clear pathology was observed in the lungs (9). In 2 inoculated and both recipient mink, pulmonary lesions (Figure, panels E, G) were associated with viral antigen expression (Figure, panels F, H) and characterized by multifocal to coalescing alveolar damage with degeneration or necrosis of alveolar septa, infrequent hyaline membrane formation, and variable proliferation

¹These authors contributed equally to this article.

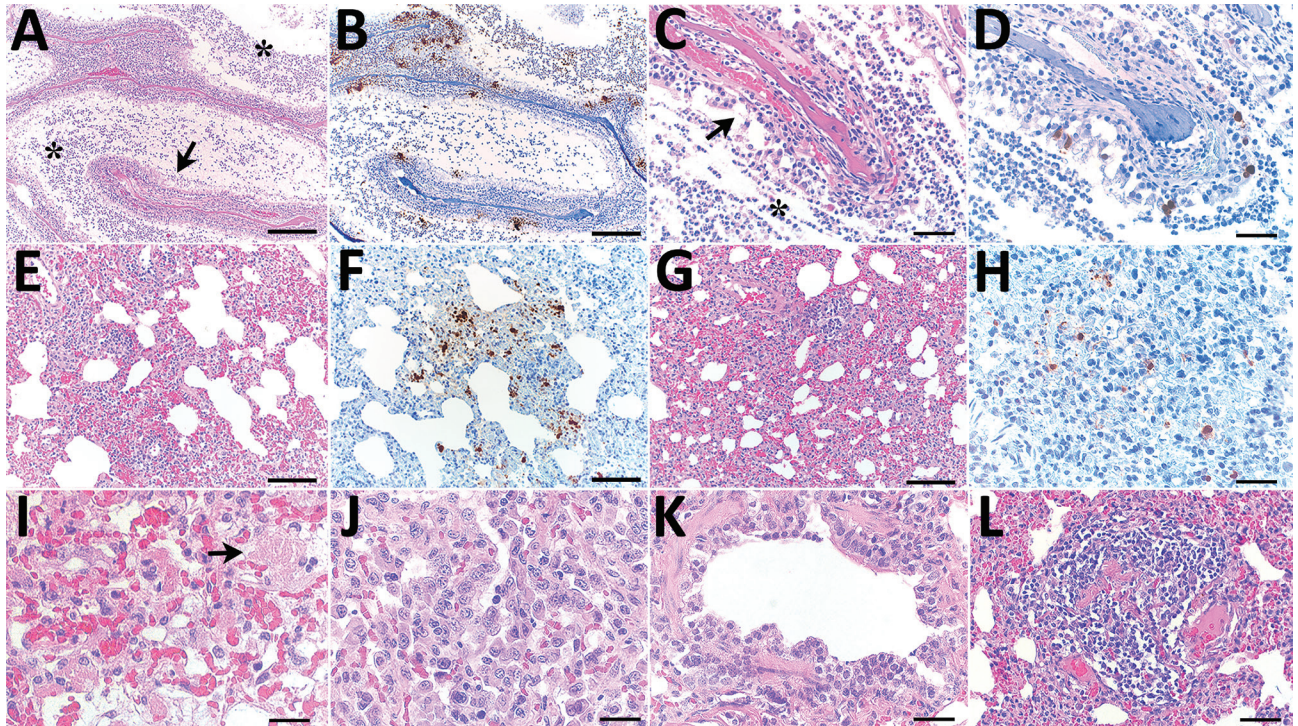


Figure. Histopathologic changes and SARS-CoV-2 expression in the upper and lower respiratory tracts of mink experimentally infected with Omicron variant at 7 days postinfection and recipient mink after 10 days of follow-up. A) Respiratory segment of the nose from an intranasally infected mink showing luminal accumulation of exudate (asterisks) and degeneration of mucosal epithelium (arrow). Scale bar indicates 500 μ m. B) Viral antigen widely detected within nasal lumen and respiratory epithelium. Scale bar indicates 500 μ m. C, D) Respiratory epithelium from a recipient mink depicting marked degeneration and loss (arrow in panel C) and intraluminal accumulation of sloughed cells and neutrophils (asterisk in panel C), and intraepithelial viral expression (panel D). Scale bars indicate 50 μ m. E–H) Lungs from intranasally infected (E, F) and recipient (G, H) mink showing alveolar damage with intralesional presence of viral nucleoprotein. Scale bars indicate 200 μ m in panels E–G and 50 μ m in panel H. I, J) Marked degeneration and necrosis of alveolar septa and focal hyalin membrane (arrow in panel I) and prominent proliferation of type II pneumocytes (panel J) in an intranasally infected mink. Scale bars indicate 25 μ m. K, L) Recipient mink showing bronchiolar epithelial degeneration and hyperplasia (K) and vasculitis (L) with complete destruction of blood vessel wall and mononuclear cell infiltration. Scale bar indicates 50 μ m in panel K and 100 μ m in panel L. Hematoxylin and eosin stain and immunohistochemistry, hematoxylin counterstain.

of type II pneumocytes (Figure, panels I, J). Alveolar spaces contained macrophages, sloughed cells, edema, and hemorrhage. Bronchiolar epithelial degeneration and hyperplasia were variably present (Figure, panel K), and the lumen filled with few sloughed cells and neutrophils. Bronchi were lined by hyperplastic

epithelium with increased numbers of goblet cells. Other consistent findings were vasculitis (Figure, panel L), perivasculitis, and perivascular and peribronchial edema. In 1 inoculated mink, we observed markedly thickened alveolar septa by mononuclear cells, marked proliferation of type II pneumocytes,

Table. Results of PCR and cell culture testing for SARS-CoV-2 Omicron variant in saliva samples from 3 experimentally infected mink and 2 uninfected recipient mink*

Mink ID	1 dpi	2 dpi	3 dpi	4 dpi	5 dpi	6 dpi	7 dpi	8 dpi	9 dpi	10 dpi
Infected mink										
451	+/ND	+/+	+/-	+/-	+/-	+/-	+/-			
453	+/(+)	+/-	+/-	+/-	+/-	+/-	+/ND			
455	+/-	+/-	+/(+)	+/-	+/-	+/-	+/-			
Recipient mink										
452	(+)/+	-/-	+/ND	+/-	+/-	+/+	+/-	+/-	+/-	(+)/-
454	-/+	-/+	(+)/-	+/-	+/-	+/ND	+/ND	+/-	+/-	+/-

*Plus sign alone indicates signal detected with both primers of Luna SARS-CoV-2 reverse transcription quantitative PCR Multiplex Assay Kit (New England BioLabs Inc., <https://www.neb.com>) and cycle threshold value from cell culture media was >5 cycles lower than that of the original saliva sample. Plus symbol in parentheses indicates signal detected only with 1 of 2 primers and cycle threshold value from cell culture media was 1–5 cycles lower than that of the original saliva sample. Minus sign indicates no signal with either of the primers and no cytopathic effect was detected in cell culture or cycle threshold value from the culture media was the same or higher than that of the original sample. dpi, days postinfection; ID, identification; ND, not done.

intra-alveolar macrophages, few syncytial cells, bronchi and bronchiolar epithelial cell hyperplasia, vasculitis, and perivasculitis. We could not detect viral antigen in this mink. Strikingly, all evaluated mink lacked viral antigen in the epithelium of bronchi and bronchioles.

The Omicron variant is different from other variants in its more efficient spread, primarily attributable to immune escape and likely milder symptoms in humans (6,7). These factors make preventing virus introduction into mink farms through asymptomatic humans more difficult, creating a more substantial risk for the formation of virus reservoirs among farmed or feral mink. This study shows that mink can be infected by Omicron and, crucially, efficiently transmit the virus to other mink. Despite the reports of lower virulence of Omicron, mink experience clinical disease and nasal and pulmonary microscopic lesions that closely resemble infection with previously reported variants in mink and humans (8). Clarifying the clinical signs will help detect the virus among mink earlier. Questions remain about the risks that the spread of this easily transmitted variant among mink would create for public health, including transmission to humans and emergence of mink-specific mutations, followed by their spillover to human population.

This article was preprinted at <https://www.biorxiv.org/content/10.1101/2022.02.16.480524v2>.

Acknowledgments

We thank Jari Elemo, Mari Elemo, and other animal caretakers for handling the animals and assessing their health and Esa Pohjalainen, Sanna Mäki, Tiina Sihvonen, Johanna Rintamäki, Hanna Valtonen, Marika Skön, Larissa Laine, and Elina Väisänen for technical assistance. We thank Kati Kuipers, Anne Kujanpää, Laura Vähälä, and the Finnish Centre for Laboratory Animal Pathology (FCLAP) for expert technical help, as well as Johanna Korpela and Jussi Peura from Finnish Fur Breeders Association and Jan Segervall and Maarit Mohaibes from the Kannus Research Farm Luova Ltd. for providing the animals. We also thank E3 Excellence in Pandemic Response and Enterprise Solutions coinnovation project and all its parties.

This study was supported by the Academy of Finland (grant no. 336490, 339510), VEO–European Union’s Horizon 2020 (grant no. 874735), Business Finland E3 (4917/31/2021), Finnish Institute for Health and Welfare, and the Jane and Aatos Erkko Foundation.

About the Author

Ms. Virtanen is a PhD student at the University of Helsinki in the field of clinical microbiology. Her research interests include zoonotic viruses and pathogens in human-animal interface.

References

1. Aguiló-Gisbert J, Padilla-Blanco M, Lizana V, Maiques E, Muñoz-Baquero M, Chillida-Martínez E, et al. First description of SARS-CoV-2 infection in two feral American mink (*Neovison vison*) caught in the wild. *Animals (Basel)*. 2021;11:1422. <https://doi.org/10.3390/ani11051422>
2. Oreshkova N, Molenaar RJ, Vreman S, Harders F, Oude Munnink BB, Hakze-van der Honeg RW, et al. SARS-CoV-2 infection in farmed minks, the Netherlands, April and May 2020 [Erratum in: *Euro Surveill*. 2021; 26:210325c]. *Euro Surveill*. 2020;25. <https://doi.org/10.2807/1560-7917.ES.2020.25.23.2001005>
3. Rabalski L, Kosinski M, Mazur-Panasiuk N, Szweczyk B, Bienkowska-Szweczyk K, Kant R, et al. Zoonotic spill-over of SARS-CoV-2: mink-adapted virus in humans. *Clin Microbiol Infect*. 2021.
4. Rabalski L, Kosinski M, Smura T, Aaltonen K, Kant R, Sironen T, et al. Severe acute respiratory syndrome coronavirus 2 in farmed mink (*Neovison vison*), Poland. *Emerg Infect Dis*. 2021;27:2333–9. <https://doi.org/10.3201/eid2709.210286>
5. Hammer AS, Quaade ML, Rasmussen TB, Fonager J, Rasmussen M, Mundbjerg K, et al. SARS-CoV-2 transmission between mink (*Neovison vison*) and humans, Denmark. *Emerg Infect Dis*. 2021;27:547–51. <https://doi.org/10.3201/eid2702.203794>
6. Viana R, Moyo S, Amoako DG, Tegally H, Scheepers C, Althaus CL, et al. Rapid epidemic expansion of the SARS-CoV-2 Omicron variant in southern Africa. *Nature*. 2022;603:679–86. <https://doi.org/10.1038/s41586-022-04411-y>
7. Wolter N, Jassat W, Walaza S, Welch R, Moultrie H, Groome M, et al. Early assessment of the clinical severity of the SARS-CoV-2 Omicron variant in South Africa: a data linkage study. *Lancet*. 2022;399:437–46. [https://doi.org/10.1016/S0140-6736\(22\)00017-4](https://doi.org/10.1016/S0140-6736(22)00017-4)
8. Song Z, Bao L, Deng W, Liu J, Ren E, Lv Q, et al. Integrated histopathological, lipidomic, and metabolomic profiles reveal mink is a useful animal model to mimic the pathogenicity of severe COVID-19 patients. *Signal Transduct Target Ther*. 2022;7:29. <https://doi.org/10.1038/s41392-022-00891-6>
9. Halfmann PJ, Iida S, Iwatsuki-Horimoto K, Maemura T, Kiso M, Scheaffer SM, et al.; Consortium Mount Sinai Pathogen Surveillance (PSP) study group. SARS-CoV-2 Omicron virus causes attenuated disease in mice and hamsters. *Nature*. 2022;603:687–92. <https://doi.org/10.1038/s41586-022-04441-6>

Address for correspondence: Jenni Virtanen, Department of Veterinary Biosciences, Faculty of Veterinary Medicine, University of Helsinki, Agnes Sjöbergin katu 2, 00790, Helsinki, Finland; email: jenni.me.virtanen@helsinki.fi

Experimental Infection of Mink with SARS-CoV-2 Omicron Variant and Subsequent Clinical Disease

Appendix

Materials and Methods

Virus Stock and Cell Line

Omicron variant (original patient sample: hCoV-19/Finland/THL-202126660/2021, EPI_ISL_8768822 (Gisaid)) of SARS-CoV-2 (10^6 PFU/ml) was acquired from the Finnish Institute of Health and Welfare. We ensured that the viral genome in the stock (OM393712) remained unchanged, including the furin cleavage site that mutates particularly rapidly in cell culture for Omicron, with a protocol described in (1). It has been reported that a few key mutations (e.g., the N501Y mutation) present in α , β , Gamma, and Omicron variants improve the affinity of the SARS-CoV-2 spike S1 protein to mouse ACE-2 and increase infectivity of SARS-CoV-2 in standard BALB/c mice (1).

TMPRSS2-expressing clone of Vero E6 cells (VE6T) (2) were grown in minimal essential eagle's medium (MEM, Sigma-Aldrich) including 10% (cell maintenance) or 2% (infection experiments) fetal bovine serum (FBS, ThermoFisher), 2 mM L-glutamine, 100 IU/mL penicillin, 100 μ g/mL streptomycin, 0.205 μ g/ml of amphotericin B (Fungizone, Thermo Scientific), and Voriconazole (Sigma-Aldrich, according to manufacturer's instructions).

Animals, Infection, and Euthanasia

A total of 5 male American mink (*Neovison vison*) were transported to the University of Helsinki biosafety level-3 (BSL-3) facility at the same time and acclimatized to custommade cages (located 10–20 cm from each other) with nest boxes for 3 days with ad libitum water and food. For the experimental infection, 3 of the mink were anesthetized with 30 μ l of Ketaminol (100 mg/ml, Intervet) and Domitor (1 mg/ml, Orion Pharma) via i.m. administration and 3 were inoculated intranasally with 200 μ L of virus stock into both nostrils and the remaining 2 with

phosphate-buffered saline (PBS). The animals were held in an upright position for a few seconds to allow the liquid to flush downwards in the nasal cavity. Revertor (5 mg/mL, Scanvet) was given (15 μ L) as an α 2-adrenergic antagonist for reversing clinical effects of sedation. Two mink were left uninfected. All mink were monitored daily for signs of illness (changes in posture or behavior, rough coat, apathy, ataxia, runny nose, diarrhea etc.). At the end of the experiment, the mink were anesthetized with Ketaminol and Domitor (40 μ l), sampled for blood, and euthanized in a CO₂ chamber. Experimental procedures were approved by the Animal Experimental Board of Finland (license number ESAVI/33259).

Sample Collection

Saliva samples (oral swabs) were collected before the infection, and every day post infection with foam swabs (Virocult, MWE) into 200 μ l PBS and culture media. Animals were necropsied immediately after euthanasia. Representative fresh samples from all lung lobes were collected and frozen for virological examinations. Lungs were then inflated with 10% neutral buffered formalin and fixed for 48 h. For histopathology, each lung lobe (right cranial, left cranial, right medial, right caudal and left caudal) were trimmed into three consecutive cross sections of \approx 0.5 cm thick starting at the lobe hilum and moving toward the posterior of the lobe along the main branching bronchus. The head was separated from the carcass by disarticulation of the atlanto-occipital joint, the skull was removed exposing the brain and the entire was placed in 10% neutral buffered formalin. After 48 h fixation, the brain was removed and the head sawn longitudinally in the midline using a diamond saw. Slices of 0.3 cm were prepared from the nasal cavity including vestibular, respiratory and olfactory segments, and gently decalcified for 4 days in 14% EDTA solution (Tritrimex [®] III, Nederland).

Histology and Immunohistochemistry

Trimmed lung lobes and decalcified nasal cavity sections were routinely processed, paraffin-wax embedded, cut at 3–5 μ m and stained with hematoxylin–eosin (HE) or subjected to immunohistochemistry (IHC) for the detection of SARS-CoV-2 antigen. Briefly for IHC, slides were deparaffinized and incubated for 20 min at 99°C in 10 mM citrate buffer (pH 6) for heat-induced antigen retrieval. Endogenous peroxidase was performed by immersion in 3% hydrogen peroxide for 10 min. After incubation with 10% bovine serum albumin in phosphate-buffered saline, sections were incubated for 60 minutes at room temperature (RT) with rabbit polyclonal anti- SARS-CoV-2 nucleoprotein antibody diluted 1:3000 in animal-free blocker and diluent

solution (R.T.U. Animal-Free Blocker and Diluent; Vector Laboratories, Burlingame, Ca, USA). Polymer-linked to HRP (BrightVision + Poly-HRP kit; ImmunoLogic, Duiven, Netherlands) was used as secondary antibody incubating in a humid chamber for 30 min at RT. The reaction was visualized with right DAB Substrate kit (ImmunoLogic, Duiven, Netherlands) and slight counterstain with Harris hematoxylin. As negative control, the primary antibody was substituted with rabbit IgG Isotype control (1:1000).

PCR

RNA was extracted from saliva samples collected in PBS with Viral RNA Minikit (Qiagen) according to manufacturer's instructions. PCR tests were performed with Luna SARS-CoV-2 RT-qPCR Multiplex Assay Kit (NEB). Samples that gave signal with both primers were considered positive (+) and samples that only gave signal with one primer weak positive ((+)).

Virus Culture

Saliva samples collected in culture media were subjected to cell culture in 6-well plates by adding the whole sample and 2 ml of culture media to the cells. Cells were grown at 37°C for 9 days or until cytopathic effect (CPE) was detected. If CPE was detected, a 140 µl sample from the culture media was taken and RNA was extracted with QIAamp 96 Virus QIAcube HT kit (Qiagen, off-board lysis) and tested with PCR as described above. Culturing result was considered positive if Ct values from the culture media were clearly lower (more than 5 cycles) than that of the original saliva sample (+). If Ct values were 1–5 cycles lower, culturing results was considered a possible positive ((+)). If Ct values were similar or bigger than those of the original sample, result was considered negative.

References

1. Kant R, Kareinen L, Smura T, Freitag TL, Jha SK, Alitalo K, et al. Common Laboratory Mice Are Susceptible to Infection with the SARS-CoV-2 Beta Variant. *Viruses*. 2021;13:2263. [PubMed](https://doi.org/10.3390/v13112263) <https://doi.org/10.3390/v13112263>
2. Rusanen J, Kareinen L, Szivovics L, Uğurlu H, Levanov L, Jääskeläinen A, et al. A Generic, Scalable, and Rapid Time-Resolved Förster Resonance Energy Transfer-Based Assay for Antigen Detection-SARS-CoV-2 as a Proof of Concept. *MBio*. 2021;12:e00902-21. [PubMed](https://doi.org/10.1128/mBio.00902-21) <https://doi.org/10.1128/mBio.00902-21>

Appendix Table 1. Cycle threshold values from saliva samples in PCR with Luna SARS-CoV-2 RT-qPCR Multiplex Assay Kit (2019-nCoV_N1/2019-nCoV_N2)*

dpi	Infected mink			Recipient mink	
	451	453	455	452	454
1	28.15/28.27	23.27/23.85	25.58/25.66	no ct/36.67	no ct/no ct
2	28.23/28.55	34.63/34.17	29.66/30.16	no ct/no ct	no ct/no ct
3	14.15/13.86	14.9/14.61	15.85/15.71	33.36/33.38	38.68/no ct
4	25.3/26.27	21.19/21.99	25.66/26.72	28.71/30.06	31.13/32.27
5	32.44/33.22	25.87/26.00	23.71/23.83	34.13/34.12	26.46/26.59
6	27.49/28.01	29.79/30.77	32.17/33.97	30.19/30.75	33.57/34.16
7	25.03/26.91	27.07/28.78	27.82/29.80	30.91/33.51	27.25/29.12
8	N/A	N/A	N/A	28.07/28.29	31.81/32.01
9	N/A	N/A	N/A	30.69/32.56	34.7/36.36
10	N/A	N/A	N/A	37.41/no ct	32.79/34.05

*ct, cycle threshold; dpi, days post infection; N/A, not applicable.

Appendix Table 2. Cycle threshold values from culture medias of saliva samples in PCR with Luna SARS-CoV-2 RT-qPCR Multiplex Assay Kit (2019-nCoV_N1/2019-nCoV_N2) at the time cytopathic effect was observed*

dpi	Infected mink			Recipient mink	
	451	453	455	452	454
1	ND	20.40/22.54	No CPE	19.97/20.78	31.28/32.74
2	17.26/18.26	30.09/35.12	No CPE	no ct/no ct	35.75/41.25
3	13.78/14.30	14.78/15.38	13.48/14.08	ND	no ct/no ct
4	No CPE	No CPE	No CPE	No CPE	No CPE
5	no ct/no ct	no ct/no ct	30.05/32.48	no ct/no ct	28.32/30.50
6	31.03/31.99	no ct/no ct	ND	23.04/25.04	34.73/39.09
7	No CPE	ND	No CPE	No CPE	ND
8	N/A	N/A	N/A	33.82/39.09	no ct/no ct
9	N/A	N/A	N/A	No CPE	No CPE
10	N/A	N/A	N/A	no ct/no ct	No CPE

*CPE, cytopathic effect; ct, cycle threshold; ND, not done.