

Fatal 1918 Pneumonia Case Complicated by Erythrocyte Sickling

To the Editor: The year 2010 marks the 100th anniversary of Herick's original case description of what is now known as sickle cell anemia (1). Additional case reports followed in 1911 and 1915; in 1922, Mason described a fourth case and coined the term sickle cell anemia (2). In 1949, Pauling et al. published an important study that identified differences in the electrophoretic mobilities of normal and sickled erythrocytes (3). The inheritance pattern of sickle cell anemia was determined in 1949; in 1957, Ingram identified the single amino acid change in hemoglobin S (4).

Patients with sickle cell anemia are at markedly increased risk for infections with several bacteria, including *Streptococcus pneumoniae*, and emerging viral infections such as pandemic influenza. We report a retrospectively identified case of fatal bacterial pneumonia complicated by abundant erythrocyte sickling in a patient bearing the sickle cell trait. The patient's illness occurred in July 1918, representing one of the first identified symptomatic cases of sickle cell trait.

The patient, a 21-year-old African American male, was a US Army private admitted to the post hospital in Fort Riley (Camp Funston), Kansas, USA, on July 11, 1918, >1 month before the first recognized cases of the fall wave of the influenza pandemic in the United States. The patient had a 2-day history of fever, headache, chest pain, and a dry, hacking, non-productive cough. Medical history consisted only of frequent headaches. Admission temperature was 105.4°F. Physical examination found indistinct breath sounds over the entire right lung. Lobar pneumonia was diagnosed in the patient. On July 15,

his leukocyte count was 7,600 cells/mm³, and physical examination found crepitant rales over the right lung and tubular breathing over the right upper lobe. On July 19, his condition was grave. Probably because most US military camps had experienced epidemics of measles with fatal streptococcal pneumonia during winter 1917–spring 1918, he was given 100 mL anti-streptococcus antiserum intravenously. He died July 20.

Postmortem examination on July 21 indicated marked consolidation of both the right middle and lower lung lobes, which appeared hemorrhagic. Large areas of right upper lobe necrosis were mixed with areas corresponding grossly to lobar pneumonia. The right pleural cavity was obliterated by fibrinous adhesions. Postmortem cultures from the right upper and lower lung lobes were positive for *S. pneumoniae* type II. Pleural cavity and heart blood cultures were negative. Notable findings included an enlarged hemorrhagic and necrotic spleen and numerous small hemorrhages in the medullary regions of the kidneys. Microscopic results were absent from the available postmortem examination record.

Two hematoxylin and eosin-stained lung sections from this patient, examined by using material from the archives of the Armed Forces Institute of Pathology (5) as part of a review of possible 1918 influenza virus pneumonia cases, showed acute pneumonia with extensive necrosis (online Technical Appendix Figure, panel A, www.cdc.gov/EID/content/16/12/2000-Techapp.pdf). Brown and Hopps tissue Gram stain revealed abundant gram-positive cocci (online Technical Appendix Figure, panel B). Histologic examination found abundant sickled erythrocytes in small pulmonary vessels (online Technical Appendix Figure, panels C, D). Results of real-time reverse transcription-PCR for influenza virus matrix 1 gene (5) were negative, as were immunohistochemical

examination results for influenza viral antigen (online Technical Appendix Figure, panel F); control immunohistochemical examination results for cytokeratins were positive (online Technical Appendix Figure, panel E).

DNA was extracted from 1 of the formalin-fixed, paraffin-embedded lung blocks. Partial sequence of the hemoglobin beta gene was performed with PCR primer sets designed to span portions of the open reading frame (primers available upon request). Sequence of multiple clones across the gene showed the patient to be heterozygous for the Glu6Val hemoglobin S mutation (6), with 1 wild type and 1 mutant allele (online Technical Appendix Figure, panels G and H), indicative of sickle cell trait. Sequence analyses for the mutations associated with hemoglobin C (Glu6Lys), hemoglobin D (Glu121Gln), and hemoglobin O (Glu121Lys) showed only wild-type sequence (data not shown).

Although the material had been examined for possible influenza infection, the timing of the illness makes influenza an unlikely cofactor because epidemiologic records show no evidence of influenza or excess deaths from respiratory disease at Fort Riley in July 1918 (7). We found no evidence of influenza A viral RNA by reverse transcription-PCR or viral antigen by immunohistochemical examination.

Sickle cell trait has been occasionally associated with debilitating illness and death. Pulmonary complications associated with sickle cell trait include venous thromboembolic disease, sickle chest syndrome (8), and pulmonary infarction (9), which recently prompted US college officials to screen athletes for sickle cell trait (10). We speculate that the clinical severity and rapid development of acute bacterial pneumonia in the patient reported here led to profound terminal hypoxemia, which led in turn to erythrocyte sickling. The postmortem gross evidence of necrotic areas in the lung and spleen and hemorrhages in

the kidneys is clearly consistent with sickled erythrocytes causing vascular congestion and infarction, thus contributing to the patient's death.

This work was supported by the Intramural Research Program of the National Institutes of Health and the National Institute of Allergy and Infectious Diseases.

**Zong-Mei Sheng,
Daniel S. Chertow,
David M. Morens,
and Jeffery K. Taubenberger**

Author affiliation: National Institutes of Health, Bethesda, Maryland, USA

DOI: 10.3201/eid1612.101376

References

- Herrick JB. Peculiar elongated and sickle-shaped red blood corpuscles in a case of severe anemia. *Arch Intern Med.* 1910;6:517–21.
- Mason VR. Sickle cell anemia. *J Am Med Assoc.* 1922;79:1318–20.
- Pauling L, Itano HA, Singer SJ, Wells IC. Sickle cell anemia: a molecular disease. *Science.* 1949;110:543–8. DOI: 10.1126/science.110.2865.543
- Ingram VM. Gene mutations in human haemoglobin: the chemical difference between normal and sickle cell haemoglobin. *Nature.* 1957;180:326–8. DOI: 10.1038/180326a0
- Taubenberger JK, Reid AH, Krafft AE, Bijwaard KE, Fanning TG. Initial genetic characterization of the 1918 “Spanish” influenza virus. *Science.* 1997;275:1793–6. DOI: 10.1126/science.275.5307.1793
- Chan OT, Westover KD, Dietz L, Zehnder JL, Schrijver I. Comprehensive and efficient HBB mutation analysis for detection of beta-hemoglobinopathies in a pan-ethnic population. *Am J Clin Pathol.* 2010;133:700–7. DOI: 10.1309/AJCP7HQ2KWGHECIO
- Hall MW. Inflammatory diseases of the respiratory tract (bronchitis; influenza; bronchopneumonia; lobar pneumonia). In: Ireland MW, Siler JF, editors. *The Medical Department of the United States Army in the World War.* Washington: US Government Printing Office; 1928. p. 61–169.
- Tsaras G, Owusu-Ansah A, Boateng FO, Amoateng-Adjepong Y. Complications associated with sickle cell trait: a brief narrative review. *Am J Med.* 2009;122:507–12. DOI: 10.1016/j.amjmed.2008.12.020
- Israel RH, Salipante JS. Pulmonary infarction in sickle cell trait. *Am J Med.* 1979;66:867–9. DOI: 10.1016/0002-9343(79)91139-2
- Bonham VL, Dover GJ, Brody LC. Screening student athletes for sickle cell trait—a social and clinical experiment. *N Engl J Med.* 2010;363(11):997–9.

Address for correspondence: Jeffery K. Taubenberger, Laboratory of Infectious Diseases, NIAID, NIH, 33 North Dr, MSC 3203, Bethesda, MD 20892-3203, USA; email: taubenbergerj@niaid.nih.gov

Human Brucellosis, Inner Mongolia, China

To the Editor: Brucellosis is one of the most common zoonotic diseases worldwide (1). The disease is caused by *Brucella* spp. and mainly transmitted from its animal reservoirs to humans by direct contact with infected animals or through the ingestion of raw milk or unpasteurized cheese (2). Human brucellosis has a wide spectrum of clinical manifestations, which can vary from subclinical infection with seroconversion to a full-blown clinical picture of fever; osteoarticular involvement; sweating; constitutional symptoms; and hepatic, cardiac, central nervous system, or ocular involvement (2–4). Although controlled in many industrialized countries, the disease remains endemic to many parts of the world, including Spain, Latin America, the Middle East, parts of Africa, and Asia (5). In the People's Republic of China, human brucellosis was highly endemic from the mid-1950s well into the 1970s, but then incidence decreased until the mid-1990s. However, incidence has increased sharply in China since 1995 (6), and the Inner Mongolia Autonomous Region is the most severe endemic focus; most

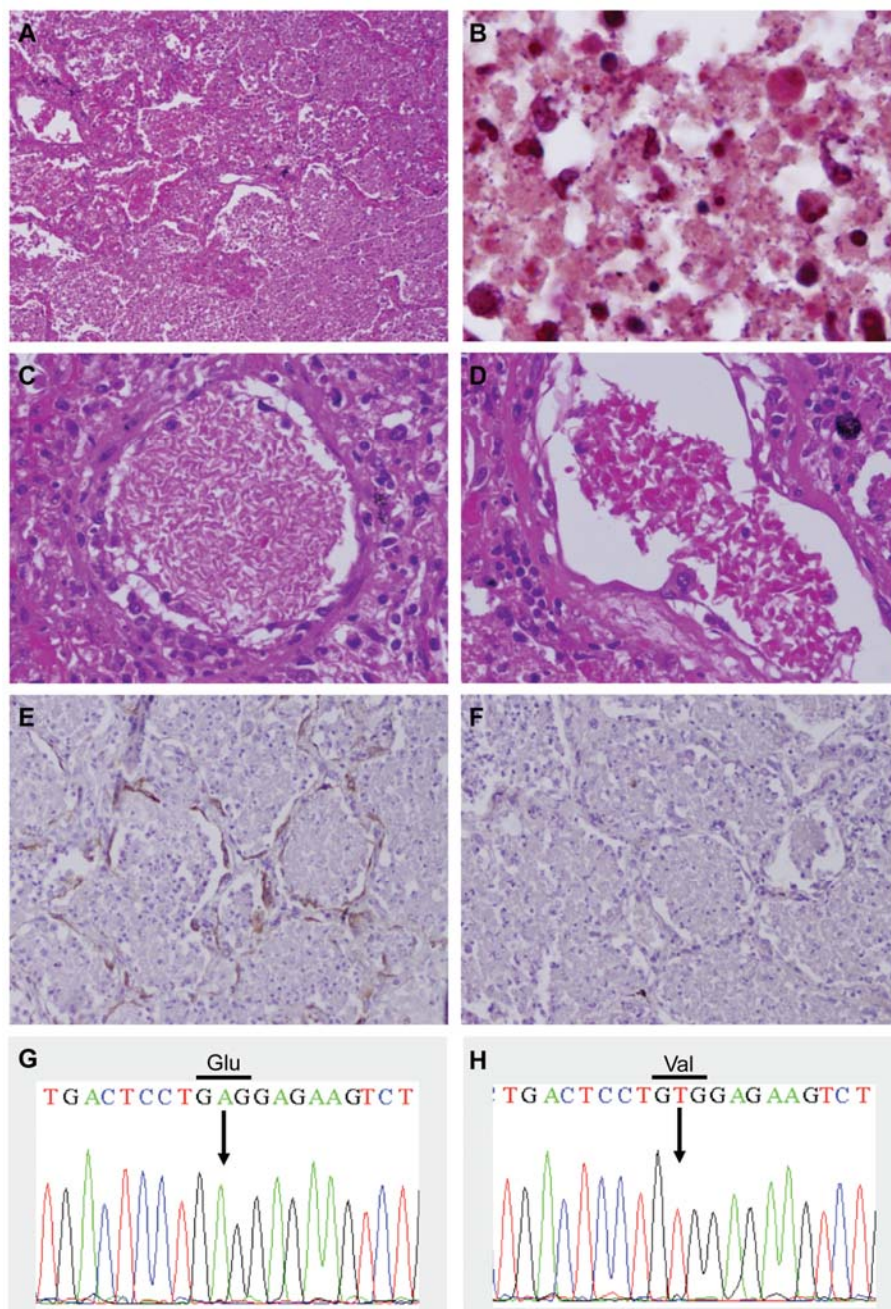
reports of the disease occurred during 1999–2008. National and local public health authorities are concerned about the increasing incidence of the disease in this province. Here we report the epidemic characteristics that existed in this region during 1999–2008.

Human brucellosis is a reportable disease in China; suspected or confirmed cases must be reported to local and provincial Centers for Disease Control and Prevention (CDC) and then to Chinese CDC (CCDC) through the National Notifiable Disease Surveillance System. To meet case definitions, disease in persons must be accompanied by clinical signs and must be confirmed by serologic tests or isolation in accordance with the case definition of the World Health Organization (1,7).

We obtained the National Notifiable Disease Surveillance System data that were confirmed by the Chinese CDC from Inner Mongolia CDC. A total of 43,623 cases were reported during 1999–2008, of which 70.7% occurred in male patients; the difference in incidence between sexes was significant by χ^2 test ($\chi^2 = 581.9$, $p < 0.00001$). A total of 28,237 (64.7%) reported cases occurred in persons 30–59 years of age, male (70.2%) and female (29.8%). However, 658 patients (396 boys) were <10 years of age, and 497 patients (333 men) were >70 years of age. The number of cases peaked in 2008, with 7,645 and 3,460 cases in male and female patients, respectively. The epidemic peaked in March–August, with 74.8% reported cases during the study period. The number of reported cases in 2008 was 25.6× the number reported in 1999. The highest proportion of cases (55.9%) occurred among persons engaged in agricultural activities (planting, animal husbandry) in rural areas; the next highest proportion was in shepherds (29.2%), who depend only on their herds to satisfy their nutritional needs. The number of cases sharply increased from 37 and 16 in 2001 to 315 and 308

Fatal 1918 Pneumonia Case Complicated by Erythrocyte Sickling

Technical Appendix



Technical Appendix Figure. Histopathologic changes associated with a 1918 type II pneumococcal pneumonia case and DNA sequence of a portion of the hemoglobin beta gene. A) Hematoxylin and eosin (H&E)-stained lung showing severe acute bacterial pneumonia with tissue necrosis (original magnification $\times 40$). B) Brown and Hopps tissue Gram stained- lung showing abundant gram-positive cocci consistent with pneumococci (original magnification $\times 1,000$). C) Photomicrograph of H&E-stained section showing abundant erythrocyte sickling in a venule (original magnification $\times 200$). D) Photomicrograph of H&E-stained section showing abundant erythrocyte sickling in a venule (original magnification $\times 400$). E) Immunohistochemical stain for cytokeratins in a section of lung. Cytokeratin is red-brown on a hematoxylin-stained background (original magnification $\times 100$). F) Section of lung (original magnification $\times 100$) with immunohistochemical stain for influenza. G) DNA sequence of cloned DNA from a PCR product showing the sequence GAG at position 7 of the hemoglobin beta gene. H) DNA sequence of another PCR product clone showing the hemoglobin S mutation GTG at position 7 of the hemoglobin beta gene.