

# Epizootic Hemorrhagic Disease in Cattle, Western Turkey

Ethem Mutlu Temizel, Kadir Yesilbag, Carrie Batten, Sezgin Senturk, Narender S. Maan, Peter Paul Clement Mertens, and Hasan Batmaz

In 2007, an outbreak of epizootic hemorrhagic disease (EHD) occurred in Turkey. On the basis of clinical investigation, 41 cattle were suspected to have EHD. Reverse transcription-PCR and sequence analyses indicated that the virus belonged to EHD virus serotype 6, thus confirming EHD virus infection of cattle in Turkey.

Epizootic hemorrhagic disease virus (EHDV) is a member of the genus *Orbivirus*, family *Reoviridae*, and is closely related to bluetongue virus (BTV). EHD often causes death in white-tailed deer and, less frequently, a bluetongue-like illness in cattle (1–3).

*Culicoides* spp. act as vectors, transmitting EHDV between susceptible ruminant hosts (2). The clinical signs of EHD in cattle are fever, anorexia, dysphagia, ulcerative and necrotic lesions of the oral mucosa (Figure 1), hyperemia and edema of the conjunctival mucosae (Figure 2), sore muzzle, hyperemia of the teats and udder, hemorrhage, dehydration, and lameness (3). EHDV has been isolated from cattle throughout the world, including Africa, North America, Australia, Japan, and recently Israel (4–10). Recent outbreaks of EHDV in Israel during 2006 were attributed to EHDV-7 (6); outbreaks in Morocco and Algeria were similar to EHDV-6/EHDV-318. An initial suspicion of EHD, based on observation of clinical signs, can be confirmed by virus isolation and characterization, nucleic acid identification, or serologic testing. ELISA is a specific and sensitive method for detecting EHDV-specific antigens or antibodies and confirming the disease (2–5,8,11,12).

## The Study

In July 2007, a 7-week outbreak of disease in cattle began in Mugla, Turkey. The disease was regarded as unusual or atypical for the region, and cases were reported to the Uludag University Faculty of Veterinary Medicine.

Author affiliations: Uludag University Faculty of Veterinary Medicine, Gorukle, Turkey (E.M. Temizel, K. Yesilbag, S. Senturk, H. Batmaz); and Institute for Animal Health, Woking, UK, (C. Batten, N.S. Maan, P.P.C. Mertens)

DOI: 10.3201/eid1502.080572

Similar reports were also received from Izmir, Canakkale, and Istanbul through the end of August 2007. The cattle had stomatitis, swelling of eyelids, respiratory distress, nasal and ocular discharge, redness and scaling of muzzle and lips, lameness, and udder erythema, and some were recumbent (Table 1). Body temperatures were elevated (39.7°C–41.1°C), except for 1 animal, whose temperature was 37.5°C, below the reference range for cattle (37.8°C–39.2°C). However, heart rates (mean  $72 \pm 3$  beats/min) and respiratory rates (mean  $24 \pm 4$  breaths/min) were within reference ranges of 60–80 beats/min and 10–30 breaths/min, respectively, for cattle with suspected disease. Cattle with EHD had tachycardia and tachypnea (Table 2). Causes of mucosal disease, stomatitis, and fever, including bovine viral diarrhea, foot and mouth disease, and infectious bovine rhinotracheitis, were considered, but the rate of spread and some of the clinical signs ruled out these diseases. However, the clinical signs of the disease were consistent with either EHD or BTV infection (6,8–10). These diseases were therefore considered as requiring further laboratory-based diagnostic assays.

A total of 41 blood samples were obtained from the affected cattle (35 Holsteins and 6 Brown Swiss, 2–5 years of age). Samples were obtained in tubes with and without EDTA. Complete blood analysis showed that 5 of the cattle with EHD had low leukocyte counts (online Appendix Table, available from [www.cdc.gov/EID/content/15/2/317-appT.htm](http://www.cdc.gov/EID/content/15/2/317-appT.htm)). After use for hematologic analysis, samples were stored at  $-30^{\circ}\text{C}$  until virologic and serologic tests could be performed. Samples from the 41 animals were tested by ELISA for bovine viral diarrhea virus antigens; results were negative. To isolate virus, we spread unclotted blood samples onto baby hamster kidney-21 (BHK) cells.

Because EHDV had never been observed in Turkey, no diagnostic procedures were available. We therefore submitted selected samples (11 whole blood samples, 4 serum

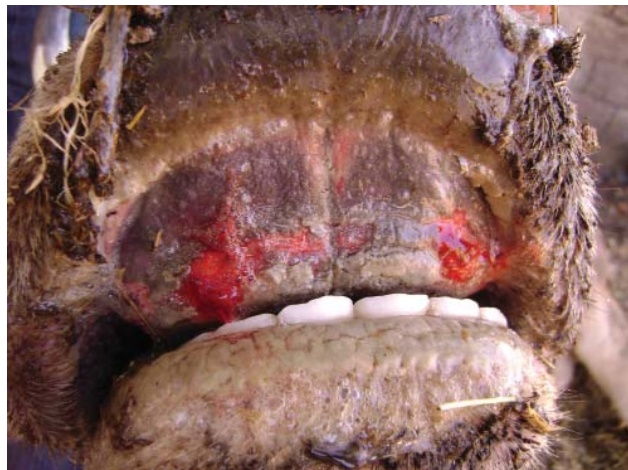

Figure 1. Erosive lesion on pulvinus dentalis of cow seropositive for epizootic hemorrhagic disease virus, Turkey, 2007.

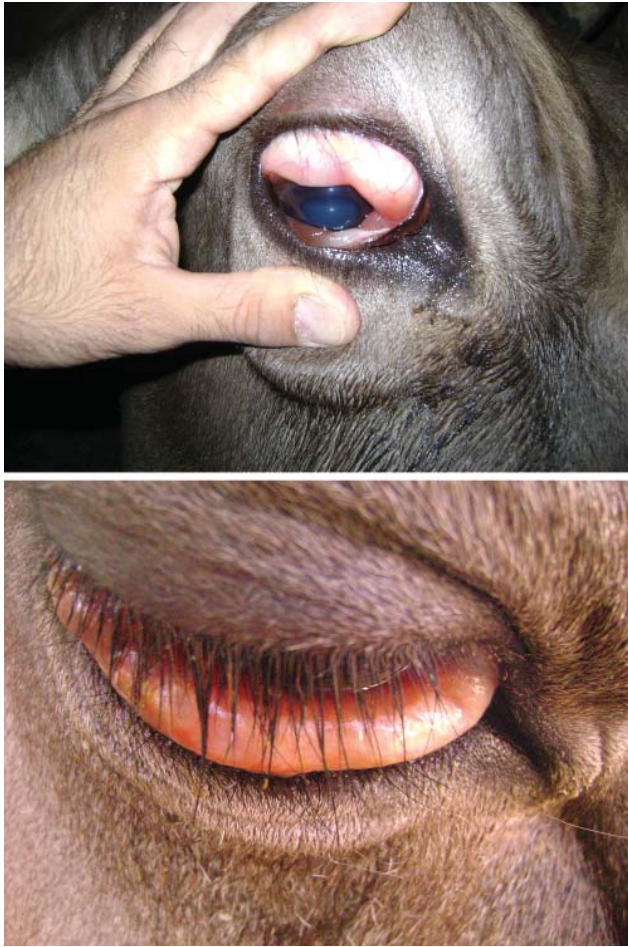


Figure 2. Swollen conjunctiva of cow seropositive for epizootic hemorrhagic disease virus, Turkey, 2007.

samples, and 15 supernatant samples from the BHK cells) to the World Organisation for Animal Health reference laboratory for BTV (Institute for Animal Health, Pirbright, UK) for virologic and serologic analysis. All samples were tested for BTV by real-time RT-PCR and for EHDV by conventional RT-PCR (13–15). All results were negative for BTV. However, a conventional RT-PCR assay targeting genome segment 7 of EHDV (15) indicated that one of the cell culture supernatants, from an early case from

Mugla, was positive for EHDV; this cow died 3 hours after clinical examination and sample collection. The remaining cell culture supernatants were negative for EHDV. It is unusual to isolate EHDV by direct inoculation of BHK cells; initial passage through eggs or the *Culicoides variipennis* larvae cell line (KC cells) is usually required (15). The 4 serum samples were also tested for EHDV-specific antibodies by ELISA (12); only 1 sample was found to contain antibodies to EHDV.

Conventional RT-PCR of RNA extracted from the 11 original blood samples gave inconclusive results. Agarose gel electrophoresis indicated no product of the expected size. However, virus was isolated from 6 of the blood samples by using KC cells (dsRNA virus reference collection at the Institute for Animal Health, reference collection nos. TUR2007/01–06). These 6 samples and the 1 original positive cell culture were further tested by serotype-specific RT-PCRs that targeted segment 2 for identification of EHDV serotype. This analysis identified all viruses as EHDV-6, sharing 95.7% nucleotide sequence identity (segment 2, 110–670 bp) with the EHDV reference strain 318.

### Conclusions

Of the selected samples submitted for BTV and EHDV testing, the positive identification of EHDV RNA supports initial clinical identification of an EHD outbreak in Turkey. The negative results from the blood samples may have resulted from degradation of viral RNA during transfer to the laboratory or insufficient sensitivity in the conventional RT-PCR. The propagation of another 6 virus isolates (TUR2007/01–06) by passage through KC cells indicates that virus was indeed present in the original blood samples, although not detected by conventional RT-PCR.

That only 1 of the 4 original serum samples was positive for EHDV antibodies by ELISA can be explained by time of sample collection. Antibodies to BTV can be detected from 8 days after infection (11); these samples may have been collected during the early stages of infection, before development of the immune response.

This study confirms EHDV infection of cattle in Turkey. EHD needs to be considered in the differential diagnosis of cattle with clinical signs that include fever; stomatitis; lameness; salivation; redness and scaling of the nose

Table 1. Clinical signs in cattle tested for EHD, Turkey, 2007\*

EHD status†	No. cattle with clinical sign									
	Discharge‡	Redness§	Recumbency	CE	Anorexia	RM	UE	Stomatitis	RD	Lame
Suspected (n = 41)	13	12	2	15	16	20	9	12	5	6
PCR+ (n = 1)	1	0	1	1	1	1	1	1	1	1
Seropositive (n = 1)	1	1	0	1	1	1	0	1	0	1
Virus isolated (n = 6)	5	6	0	4	6	6	0	4	3	3

\*EHD, epizootic hemorrhagic disease; CE, conjunctival edema; RM, reduced milk; UE, udder edema; RD, respiratory distress.

†PCR, ELISA, and virus isolation were performed on selected samples from the 41 samples (11 whole blood samples, 4 serum samples, and 15 supernatant samples from the baby hamster kidney cells). The virus-positive animals were PCR negative.

‡Nasal and ocular discharge

§Redness and scaling of nose and lips.

Table 2. Vital signs of cattle tested for EHD, Turkey, 2007\*

EHD status†	Temperature, °C	Heart rate, beats/min	Respiratory rate, breaths/min	Mucous membranes	Enlarged lymph nodes	Rumen motility, contractions/5 min
Suspected (n = 41)	37.5–39.2	72 ± 3‡	24 ± 4‡	Cyanotic (n = 2)	ND	0–12
PCR+ (n = 1)	40.5	110	52	Cyanotic	Prescapular, submandibular	0
Seropositive (n = 1)	41.1	104	48	Hyperemic	None	1
Virus isolated (n = 6)	39.7–40.6	68–86	32–56	Normal color	Submandibular (n = 1)	0–4

\*EHD, epizootic hemorrhagic disease; ND, not detected.

†PCR, ELISA, and virus isolation were performed on selected samples from the 41 samples (11 whole blood samples, 4 serum samples, and 15 supernatant samples from the baby hamster kidney cells). The virus-positive animals were PCR negative.

‡Mean ± SEM.

and lips; swelling of the tongue; and erosions of the pulvulus dentalis, palatinum, and nose. More detailed studies of EHDV infection in cattle are needed.

Dr Temizel is a veterinarian at the Uludag University Faculty of Veterinary Medicine, Department of Internal Medicine, Bursa, Turkey. His research interests are the infectious and metabolic diseases of cattle and small ruminants.

## References

- Mertens PPC, Maan S, Samuel A, Attoui H. *Orbivirus, Reoviridae*. In: Fauquet CM, Mayo MA, Maniloff J, Desselberger U, Ball LA, editors. Virus taxonomy, VIIIth report of the International Committee on Taxonomy of Viruses. London: Elsevier/Academic Press; 2005. p. 466–83.
- Mullen GR, Hayes ME, Nusbaum KE. Potential vectors of bluetongue and epizootic hemorrhagic disease viruses of cattle and white-tailed deer in Alabama. *Prog Clin Biol Res*. 1985;178:201–6.
- Radostitis OMGC, Blood DC, Hinchcliff KW. Disease caused by viruses and *Chlamydia*. In: Veterinary medicine: a textbook of the diseases of cattle, sheep, pigs, goats and horses. 9th ed. London: W.B. Saunders; 2004.
- House C, Shipman LD, Weybright G. Serological diagnosis of epizootic hemorrhagic disease in cattle in the USA with lesions suggestive of vesicular disease. *Ann N Y Acad Sci*. 1998;849:497–500. DOI: 10.1111/j.1749-6632.1998.tb11105.x
- Thompson LHMJ, Holbrook FR. Isolation and characterization of epizootic haemorrhagic disease virus from sheep and cattle in Colorado. *Am J Vet Res*. 1988;49:1050–2.
- Yadin HBJ, Bumbrov V, Oved Z, Stram Y, Klement E, Perl S, et al. Epizootic haemorrhagic disease virus type 7 infection in cattle in Israel. *Vet Rec*. 2008;162:53–6.
- Shapiro JL, Wieggers A, Dulac GC, Bouffard A, Afshar A, Myers DJ, et al. A survey of cattle for antibodies against bluetongue and epizootic hemorrhagic disease of deer viruses in British Columbia and southwestern Alberta in 1987. *Can J Vet Res*. 1991;55:203–4.
- Omori T, Inaba Y, Morimoto T, Tanaka Y, Ishitani R, Ibaraki virus, an agent of epizootic disease of cattle resembling bluetongue: I. Epidemiologic, clinical and pathologic observations and experimental transmission in calves. *Jpn J Microbiol*. 1969;13:139–57.
- Weir RP, Harmsen MB, Hunt NT, Blacksell SD, Lunt RA, Pritchard LI, et al. EHDV-1, a new Australian serotype of epizootic haemorrhagic disease virus isolated from sentinel cattle in the Northern Territory. *Vet Microbiol*. 1997;58:135–43. DOI: 10.1016/S0378-1135-9700155-7
- Bréard E, Sailleau C, Hamblin C, Graham SD, Gourreau JM, Zientara S. Outbreak of epizootic haemorrhagic disease on the island of Réunion. *Vet Rec*. 2004;155:422–3.
- Darpel KE, Batten CA, Veronesi E, Shaw AE, Anthony S, Bachanek-Bankowska K, et al. A study of British sheep and cattle infected with bluetongue virus serotype 8 from the 2006 outbreak in northern Europe. *Vet Rec*. 2007;161:253–61.
- Thevasagayam JA, Woolhouse TR, Mertens PPC, Burroughs JN, Anderson J. Monoclonal antibody based competitive ELISA for the detection of antibodies against epizootic haemorrhagic disease of deer virus. *J Virol Methods*. 1996;57:117–26. DOI: 10.1016/0166-0934(95)01968-5
- Shaw AE, Monaghan P, Alpar HO, Anthony S, Darpel KE, Batten CA, et al. Development and validation of a real-time RT-PCR assay to detect genome bluetongue virus segment 1. *J Virol Methods*. 2007;145:115–26. DOI: 10.1016/j.jviromet.2007.05.014
- Anthony S, Jones H, Darpel KE, Elliott H, Maan S, Samuel A, et al. A duplex RT-PCR assay for detection of genome segment 7 (VP7 gene) from 24 BTV serotypes. *J Virol Methods*. 2007;141:188–97. DOI: 10.1016/j.jviromet.2006.12.013
- Anthony S. Genetic studies of epizootic haemorrhagic disease virus (EHDV) [dissertation]. Oxford (UK): University of Oxford; 2007.

Address for correspondence: Ethem Mutlu Temizel, Uludag University Faculty of Veterinary Medicine, Internal Medicine, Gorukle, Bursa 16190, Turkey; email: ethem@uludag.edu.tr

Use of trade names is for identification only and does not imply endorsement by the Public Health Service or by the U.S. Department of Health and Human Services.

Search past issues of EID at [www.cdc.gov/eid](http://www.cdc.gov/eid)

Appendix Table. Hematologic findings in cattle tested for epizootic hemorrhagic disease, Turkey, 2007\*

EPH status†	WBCs, ×10 <sup>3</sup> /μL	Neutrophils, %	Lymphocytes, %	Monocytes, %	Eosinophils, %	Basophils, %	RBCs, ×10 <sup>6</sup> /μL	HGB, g/dL	HCT, %	MCV, μm <sup>3</sup>	MCH, pg/cell	MCHC, g/dL	RDW, %	PLT, ×10 <sup>9</sup> /μL
Suspected (n = 41) ‡	4.3 ± 0.3	55.1 ± 2.7	33.2 ± 2.8	9.1 ± 0.8	0.3 ± 0.1	1.6 ± 0.3	6.4 ± 0.2	9.2 ± 0.2	25.7 ± 0.7	40.8 ± 0.9	15 ± 0.5	36.7 ± 0.8	22.9 ± 0.4	359.4 ± 32
PCR+ (n = 1)	1.99	66.5	22.8	8.59	0.224	1.82	5.42	9.27	24.8	45.8	17.1	37.3	20	168
Seropositive (n = 1)	5	30	56	6	8	0.8	6.43	8.5	24	41	13.4	35.2	19.8	150
Virus isolated (n = 6)	1.6–5.13	36.2–70.3	14.6–59.2	3.03–23.5	0–2.5	0.48–4.2	3.9–6.7	7.0–11.8	17.8–29.9	45.1–48.8	17.2–19.9	37.5–40.7	18.9–20.9	152–603

\*EPH, epizootic hemorrhagic disease; WBCs, white blood cells; RBCs, red blood cells; HGB, hemoglobin; HCT, hematocrit; MCV, mean corpuscular volume; MCH, mean corpuscular hemoglobin; MCHC, mean corpuscular hemoglobin concentration; RDW, red blood cell distribution width; PLT, platelets.

†PCR, ELISA, and virus isolation were performed on selected samples from the 41 samples (11 whole blood samples, 4 serum samples, and 15 supernatant samples from the baby hamster kidney cells). The virus-positive animals were PCR negative.

‡Mean ± standard error of the mean.