

timonae infection is diagnosed have >1 eschar, which raises the suspicion that some cases of Mediterranean spotted fever with multiple eschars reported in Spain could be caused by this rickettsial species. More studies about the vectors of this bacteria are needed because studies of *Hyalomma* and *Rhipicephalus* ticks (the suspected hosts) conducted in our area have not demonstrated the presence of this *Rickettsia* species.

Koldo Aguirrebengoa,*
Aránzazu Portillo,†
Sonia Santibáñez,†
Juan J. Marín,†
Miguel Montejo,*
and José A. Oteo†

*Hospital de Cruces, Baracaldo, Spain; and †Hospital San Pedro—Centro de Investigación Biomédica de La Rioja (CIBIR), Logroño, Spain

References

1. Fournier PE, Zhu Y, Yu X, Raoult D. Proposal to create subspecies of *Rickettsia sibirica* and an emended description of *Rickettsia sibirica*. *Ann N Y Acad Sci*. 2006;1078:597–606.
2. Raoult D, Brouqui P, Roux V. A new spotted-fever-group rickettsiosis. *Lancet*. 1996;348:412.
3. Fournier PE, Gouriet F, Brouqui P, Lucht F, Raoult D. Lymphangitis-associated rickettsiosis, a new rickettsiosis caused by *Rickettsia sibirica mongolotimonae*: seven new cases and review of the literature. *Clin Infect Dis*. 2005;40:1435–44.
4. Pretorius AM, Birtles RJ. *Rickettsia mongolotimonae* infection in South Africa. *Emerg Infect Dis*. 2004;10:125–6.
5. Psaroulaki A, Germanakis A, Gikas A, Scoulica E, Tselentis Y. Simultaneous detection of “*Rickettsia mongolotimonae*” in a patient and in a tick in Greece. *J Clin Microbiol*. 2005;43:3558–9.
6. de Sousa R, Barata C, Vitorino L, Santos-Silva M, Garrapato C, Torgal J, et al. *Rickettsia sibirica* isolation from a patient and detection in ticks, Portugal. *Emerg Infect Dis*. 2006;12:1103–8.
7. Choi YJ, Jang WJ, Kim JH, Ryu JS, Lee SH, Park KH, et al. Spotted fever group and typhus group rickettsioses in humans, South Korea. *Emerg Infect Dis*. 2005;11:237–44.

8. Oteo JA, Portillo A, Santibáñez S, Pérez-Martínez L, Blanco JR, Jiménez S, et al. Prevalence of spotted fever group *Rickettsia* species detected in ticks in La Rioja, Spain. *Ann N Y Acad Sci*. 2006;1078:320–3.
9. Jado I, Oteo JA, Aldámiz M, Gil H, Escudero R, Ibarra V, et al. *Rickettsia monacensis* and human disease, Spain. *Emerg Infect Dis*. 2007;13:1405–7.

Address for correspondence: José A. Oteo, Área de Enfermedades Infecciosas, Hospital San Pedro, C/ Piqueras, 98-7ª NE, 26006 – Logroño (La Rioja), Spain; email: jaoteo@riojasalud.es

Lymphangitis in a Portuguese Patient Infected with *Rickettsia sibirica*

To the Editor: We report a case of *Rickettsia sibirica* mongolotimonae strain infection associated with lymphangitis (1). A 44-year-old man was admitted to São Bernardo Hospital in Setubal, Portugal, on August 21, 2006. Twelve days previously while on vacation at Troia Peninsula, he noted malaise, insomnia, and dry buccal mucosa. The next day he observed a small erythematous pruritic lesion on the lower right forearm that 2 days later developed into an eschar. He also had fever and sought medical care. After treatment with topical bacitracin, floxacillin, and acetaminophen for 2 days, fever (38.7°C) continued with lymphangitis extending from the right wrist to the elbow. The medication was changed to nimesulide. Three days later a rash developed on the trunk and arms, and lymphangitis extended to the axilla. Fever and chills continued, leading to hospital admission. No history of tick exposure was reported. Physical examination showed blood pressure 128/73 mm Hg, pulse 96/min, and a rubbery, nontender right

supraclavicular lymph node ≈1 cm in diameter. Several 5- to 10-mm maculopapular erythematous lesions were observed on the patient’s palms. He had inflammation on the right forearm suggestive of lymphangitis and an eschar with surrounding edema and erythema on the dorsal lower right forearm (Figure). Admission evaluation showed platelets 117,000/μL, total bilirubin 0.42 mg/dL, albumin 3.42 g/dL, creatinine 1.1 mg/dL, alanine aminotransferase 244 U/L, aspartate aminotransferase 54 U/L, alkaline phosphatase 1061 U/L, creatine phosphokinase 87 U/L, lactate dehydrogenase 784 U/L, C-reactive protein 7.1 mg/dL, radiographic pulmonary diffuse reticular pattern, arterial pO₂ 68 mm Hg, O₂ saturation 94%, pCO₂ 22 mm Hg, and arterial blood pH 7.35. The differential diagnoses included rickettsiosis, pneumonia, and cellulitis. Treatment with vancomycin, ceftriaxone, and 100 mg of doxycycline twice a day was begun. On the day after hospitalization, a heparinized blood sample and 2 skin biopsy samples were collected. Vancomycin and ceftriaxone were discontinued at 48 hours when rickettsial infection was confirmed by PCR on skin biopsy; 48 hours later, the patient was afebrile.

Immunofluorescence assay for antibodies that used *R. sibirica* mongolotimonae strain as antigen demonstrated seroconversion with no antibodies in the serum sample collected on August 21 and immunoglobulin G (IgG) and IgM antibodies at a titer of 256 in serum collected on August 30. DNA was extracted from 1 skin biopsy sample by using a DNeasy Tissue Kit (QIAGEN, Hilden, Germany). The products of nested PCR showed 100% similarity with *gltA* (353/353) and *ompA* (350/350) nucleotide sequences of *R. sibirica* mongolotimonae strain (GenBank accession nos. DQ423368.1 and DQ423367.1) (1).

Cutaneous biopsy indicated epidermal and dermal necrosis with extensive lymphocyte- and macro-

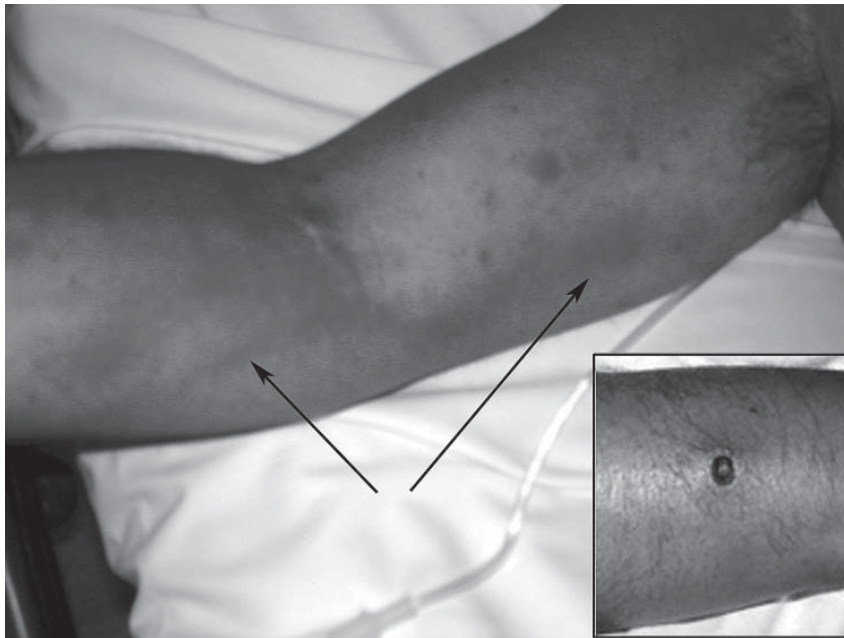


Figure. Lymphangitis extending from the right forearm to the axilla and (inset) eschar on right forearm, caused by *Rickettsia sibirica mongolitimonae* strain. Arrows indicate lymphangitis.

phage-rich inflammatory infiltrates involving the papillary and reticular dermal blood vessels characteristic of rickettsial infection. Relatively scant intracellular organisms were observed in the reticular dermis by spotted fever group rickettsia-specific immunohistochemistry (2).

Because of the presence of shared protein and lipopolysaccharide antigens in spotted fever group rickettsiae, distinguishing infections with closely related rickettsiae such as *R. conorii*, *R. africae*, and *R. sibirica* by serologic or immunohistochemical methods is very difficult. However, isolation and/or PCR detection followed by genetic characterization can determine the genotype of the organism to the level of genus, species, and strain. The incidence of *R. sibirica mongolitimonae* strain infection in Portugal is not known because the usual laboratory confirmation by serologic methods does not distinguish these cases from Mediterranean spotted fever.

Both cases of *R. sibirica* infection that have been recognized in Portugal occurred in August during the season-

al peak of Mediterranean spotted fever (1). This epidemiology differs from that in other countries (3–6). Perhaps differences in seasonal activity, population dynamics, or species of the vectors are the basis for the varying epidemiology. In Portugal, *R. sibirica* has been detected in *Rhipicephalus pusillus* (1). *Rickettsia sibirica mongolitimonae* strain was first isolated from a *Hyalomma asiaticum* tick from Inner Mongolia in 1991 (7) and subsequently from *H. truncatum* in Niger and from *H. excavatum* removed from a Greek patient (4,8).

Lymphangitis in some patients with *R. sibirica mongolitimonae* strain infection is a potentially useful diagnostic sign. Nevertheless, half of the patients with reported cases have not had lymphangitis, and infections caused by other *Rickettsia* spp. can also cause lymphangitis (e.g., patients with African tick bite fever and *R. heilongjiangensis* infections) (1,3–6,9,10). Thus, the diagnosis of any rickettsiosis should not be based solely on clinical manifestations. The pathogenic role of rickettsiae in lym-

phangitis remains to be determined. *R. sibirica* may possibly infect the endothelium of the lymphatic vessel along the pathway from the rickettsial portal of entry at the eschar inoculation site to regional lymph nodes. However, rickettsiae have not been observed in lymphatic vessels, and the lymphatic vessel lesion has not been characterized. The possibility of another agent or pathogenic effectors cannot be excluded. Currently, this clinical manifestation is the strongest evidence that rickettsiae may initially spread by a lymphogenous route before hematogenous dissemination.

Acknowledgment

We thank Rui Bajanca for providing the histologic slides that were used for immunohistochemistry.

Rita de Sousa,* Luís Duque,†
Margarida Anes, † José Poças,†
Jorge Torgal,‡ Fátima Bacellar,*
Juan P. Olano,§
and David H. Walker§

*National Institute of Health, Lisbon, Portugal; †Hospital de São Bernardo, Setúbal, Portugal; ‡Universidade Nova de Lisboa, Lisbon, Portugal; and §University of Texas Medical Branch, Galveston, Texas, USA

References

1. Sousa R, Barata C, Vitorino L, Santos-Silva M, Carrapato C, Torgal J, et al. Isolation of *Rickettsia sibirica* (strain mongolitimonae) from a patient and detection in a *Rhipicephalus pusillus* tick in Portugal. *Emerg Infect Dis*. 2006;12:1103–8.
2. Galvao MA, Dumler JS, Mafra CL, Calic SB, Chamone CB, Cesarino Filho G, et al. Fatal spotted fever rickettsiosis, Minas Gerais, Brazil. *Emerg Infect Dis*. 2003;9:1402–5.
3. Fournier PE, Gouriet F, Brouqui P, Lucht F, Raoult D. Lymphangitis-associated rickettsiosis, a new rickettsiosis caused by *Rickettsia sibirica mongolitimonae*: seven new cases and review of the literature. *Clin Infect Dis*. 2005;40:1435–44.
4. Psaroulaki A, Germanakis A, Gikas A, Scoulica E, Tselentis Y. Simultaneous detection of *Rickettsia mongolitimonae* in a patient and a tick in Greece. *J Clin Microbiol*. 2005;43:3558–9.

5. Raoult D, Brouqui P, Roux V. A new spotted-fever-group rickettsiosis. *Lancet*. 1996;348:412.
6. Pretorius AM, Birtles RJ. *Rickettsia mongolotimonae* infection in South Africa. *Emerg Infect Dis*. 2004;10:125–6.
7. Yu X, Fan M, Xu G, Liu Q, Raoult D. Genotypic and antigenic identification of two new strains of spotted fever group rickettsiae isolated from China. *J Clin Microbiol*. 1993;31:83–8.
8. Parola P, Inokuma H, Camicas J-L, Broqui P, Raoult D. Detection and identification of spotted fever group rickettsiae and ehrlichiae in African ticks. *Emerg Infect Dis*. 2001;7:1014–7.
9. Mediannikov OY, Sidelnikov Y, Ivanov L, Mokretsova E, Fournier PE, Tarasevich I, et al. Acute tick-borne rickettsiosis caused by *Rickettsia heilongjiangensis* in Russian Far East. *Emerg Infect Dis*. 2004;10:810–7.
10. Brouqui P, Harle JR, Delmont J, Frances C, Weiller PJ, Raoult D. African tick-bite fever. An imported spotless rickettsiosis. *Arch Intern Med*. 1997;157:119–24.

Address for correspondence: David H. Walker, The Carmage and Martha Walls Distinguished University Chair in Tropical Diseases, Department of Pathology, Center for Biodefense and Emerging Infectious Disease, University of Texas Medical Branch, 301 University Blvd, Keiller Bldg, Galveston, TX 77555-609, USA; email: dwalker@utmb.edu

ANOTHER DIMENSION

The Same Air

AI Zolynas

—for Guy Murchie, *The Seven Mysteries of Life*

The same air
that moves
through me and you
through the waving branches
of the bronchial tree
through veins
through the heart
the same air
that fills balloons
that carries voices
full of lies and truths
and half-truths
that holds up the wings of butterflies
humming birds eagles hang gliders 747s
the same air
that sits like a dull relative
on humid lakes
in Minnesota in summer
the same air
trapped in vintage champagne
in old bicycle tires lost tennis balls
the air inside a vial in a sarcophagus
in a tomb in a pyramid
buried beneath the sand
the same air

inside your freezer
wrapping its cold arms
around your t.v. dinners
the same air that supports you
that supports me
the same air that moves through us
that we move through
the same air frogs croak with
cattle bellow with
monks meditate with and on
the same air we moan with
in pleasure or in pain
the breath I'm taking now
will be in China in two weeks
my lungs have passed an atom
of oxygen that passed through the lungs
of Socrates or Plato
or Lao-tsu or Buddha
or Walt Disney or Ronald Reagan
or a starving child in Somalia
or certainly you
you right here right now
yes certainly you
the same air
the very same air

Zolynas' books include *The New Physics*, Wesleyan University Press, 1979; *Under Ideal Conditions*, Laterthanever Press, 1994 (San Diego Book Award, Best Poetry, 1994); and *The Same Air*, Intercultural Studies Forum, 1997. Seven of his poems were recently featured in the movie *Fighting Words* (Indican Pictures, Los Angeles, 2007). A long-time Zen practitioner, he teaches at Alliant International University, San Diego, California, and lives with his wife in Escondido, California.